

Case Report

Symptomatic Tarlov Cyst: Report and Review

Pradit Chaiyabud MD*,
Kitti Suwanpratheap MD*

* Neurosurgery Unit, Department of Surgery, Ratchaburi Hospital

Tarlov or perineural cysts are nerve root cysts found most commonly at the sacral spine level arising between covering layers of the perineurium and the endoneurium near the dorsal root ganglion. The cysts are relatively rare and most of them are asymptomatic. Some Tarlov cysts can exert pressure on nerve elements resulting in pain, radiculopathy and even multiple radiculopathy of cauda equina. There is no consensus on the appropriate therapeutic options of Tarlov cysts. The authors present a case of two sacral cysts diagnosed with magnetic resonance imaging. The initial symptoms were low back pain and sciatica and progressed to cauda equina syndrome. Surgical treatment was performed by sacral laminectomy and wide cyst fenestration. The neurological deficits were recovered and had not recurred after a follow-up period of nine months. The literature was reviewed and discussed. This is the first reported case in Thailand

Keywords: Tarlov cyst

J Med Assoc Thai 2006; 89 (7): 1047-50

Full text. e-Journal: <http://www.medassocthai.org/journal>

Nerve root cysts within the sacral spinal canal can be detected as incidental findings in patients with lumbosacral spine problems. Tarlov originally found this type of cysts on autopsy in 1938. Most Tarlov cysts are clinically insignificant. Large and some small cysts can cause variable degrees of pain and disability. Because of rarity and unclear pathophysiology, management of symptomatic Tarlov cyst is still challenging.

Case Report

A 24-year-old woman presented with low back pain radiating to the left leg for four years. During the last two weeks, the pain had become intense and both legs were numb and weak. She also suffered from urinary incontinence and constipation. Upon neurological examination, there was decreased pin prick sensation on both S1 dermatome and saddle area, weakness of plantar flexion on both sides and decreased anal sphincter tone.

Magnetic resonance image of the lumbosacral spine showed two cystic lesions in the paramedian aspect of the spinal canal at S2 level. A cyst on the

right side was measured 1.4x2.2 centimeters and the other on the left side was 1.5x1.7 centimeters. The cysts appeared hypointense on T1 and hyperintense on T2 weighted images. There was scalloping of the S2 vertebral body (Fig. 1, 2). The diagnosis was two Tarlov cysts with cauda equina syndrome.

Sacral laminectomy was performed. The operative findings revealed two thin walled cysts at the S2 level. Both cyst walls were only widely fenestrated in the area that was free of nerve root fibers and fluid content was drained out. The presence of nerve root fibers on the cyst walls was grossly evident (Fig. 3). Sixteen days after surgery, she was completely recovered and had at least nine months of symptom-free period.

Discussion

The term 'Tarlov cysts', 'nerve root cysts', 'perineurial cysts' or 'perineural cysts' are synonyms that have been defined as fluid-filled sacs that most frequently affect nerve roots in the sacral area. The cyst was first described by Tarlov in 1938 as an incidental autopsy finding⁽¹⁾. This relatively rare lesion occurs on the extradural components of sacral nerve roots, usually multiple and multilocular, and arises between the endoneurium and perineurium of nerve

Correspondence to : Chaiyabud P, Neurosurgery Unit, Department of Surgery, Ratchaburi Hospital, Ratchaburi 70000, Thailand.

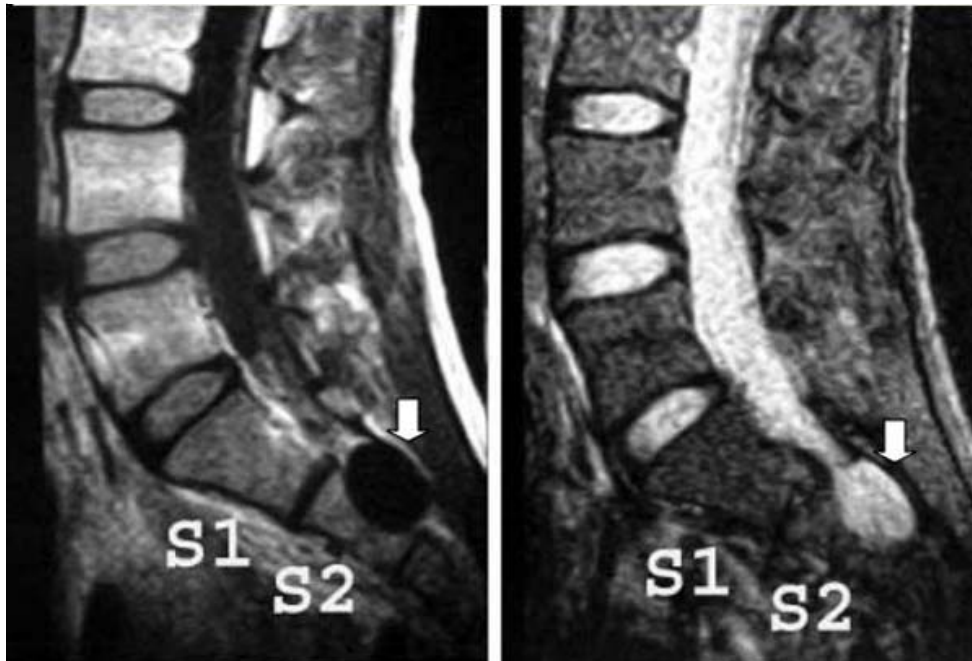


Fig. 1 MRI of lumbosacral spine-The sagittal (T1 weighted-left, T2 weighted-right) views show the cystic lesion (arrows) in spinal canal and scalloping of body of S2

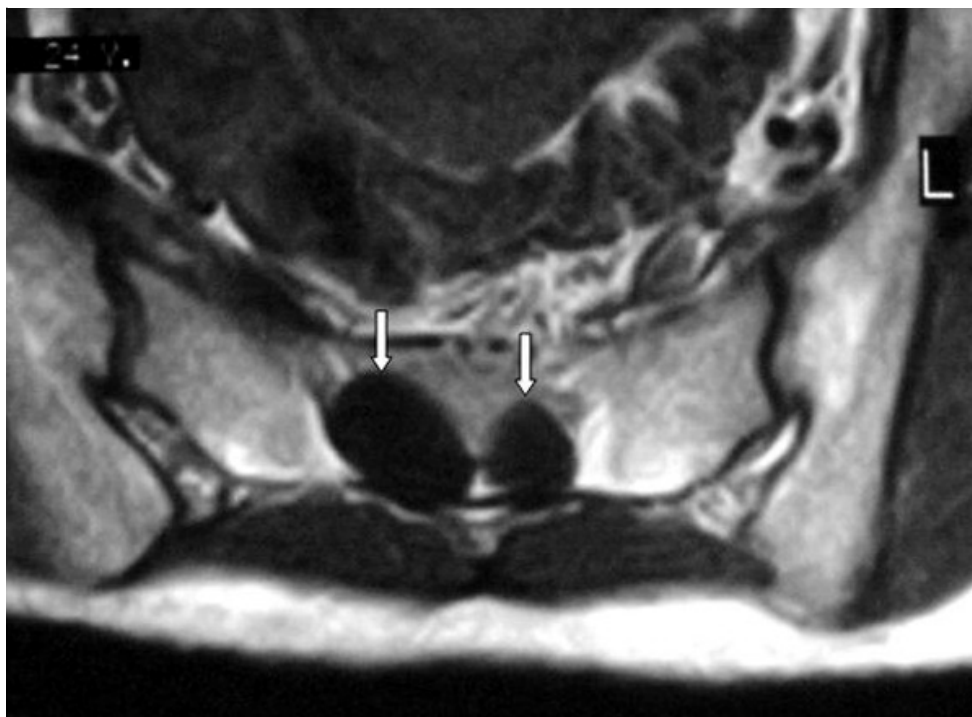


Fig. 2 MRI of lumbosacral spine-An axial T1 weighted view shows two cystic lesions (arrows) in paramedian aspect of S2 spinal canal. The right cyst is larger than the left cyst

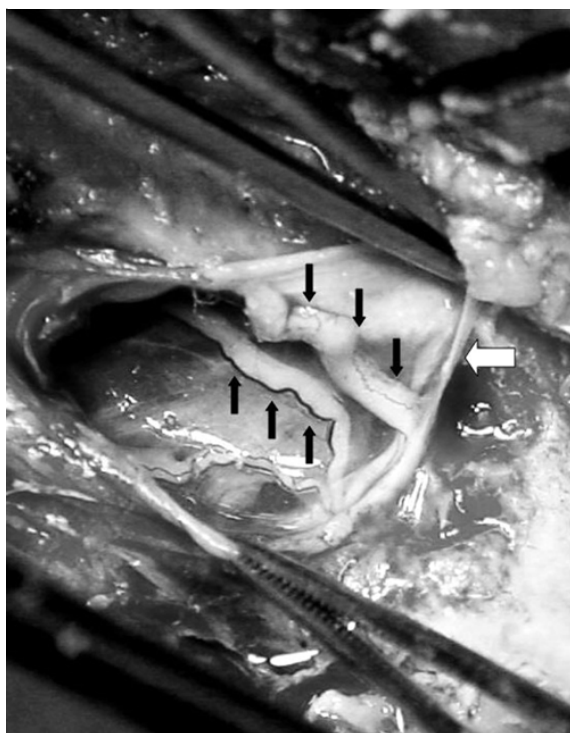


Fig. 3 An operative finding shows nerve roots (black arrows) run on the cyst wall (white arrow)

root sheath near the dorsal root ganglion⁽²⁻⁴⁾. Nerve fascicles run within the wall of the cyst and histopathologically found to contain nerve fibers and ganglion cells⁽⁵⁻⁸⁾. Most cysts do communicate with the subarachnoid space⁽⁹⁾. Tarlov cysts can be classified as type 2 of spinal meningeal cysts according to current classification introduced by Nabors et al (type 1-extradural cysts without spinal nerve root fibers, type 2-extradural cysts with spinal nerve root fibers, type 3-intradural cysts)⁽⁴⁾. Several mechanisms have been proposed to explain the formation and growth of Tarlov cysts. Some data suggest that the cysts are acquired later in life in those spinal segments subjected to trauma and cerebrospinal fluid pressure^(7,10). Tarlov believed that the cysts resulted from traumatic or spontaneous hemorrhage into the nerve root, a degenerative process involving the posterior nerve root, or the migration of subarachnoid hemorrhage along the root^(1,2,11).

The major factor contributing to growth and symptomatology of Tarlov cysts is the hydrostatic and pulsatile forces of cerebrospinal fluid⁽¹²⁾.

Most Tarlov cysts are asymptomatic and incidental findings on investigations for lumbosacral spine problems. Symptomatic cysts predominantly

cause sensory symptoms due to the proximity of the cysts to the dorsal root and ganglion. When the cysts are enlarged enough to compress the ventral root, motor deficits occur. If further enlargement develops, multiple nerve roots may be involved. Common complaints are low back pain, perineal pain, sciatica, neurogenic claudication, leg numbness, leg weakness and bowel or urinary bladder difficulties^(2,6,8,13).

Tarlov cysts can be detected by various imaging tools such as myelography, Computed Tomography (CT) and Magnetic Resonance Imaging (MRI). MRI is more effective in determining the relationship of the cysts to the surrounding structures⁽¹⁴⁻¹⁶⁾. Delayed myelogram and CT-myelogram are used to assess communication of the cysts with the subarachnoid space^(7,17).

When Tarlov cysts have been detected by imaging tools, there are at least two challenging considerations. The first decision is whether to treat the cysts and the second decision is the therapeutic options. The majority of Tarlov cysts are incidental findings on lumbosacral imaging studies (1.3%-4.6% on MRI studies)^(16,18). Together with Tarlov cyst, the presence of other lumbosacral spine problem (such as lumbar disc disease, lumbar spinal or foraminal stenosis, spondylolisthesis and others) makes it difficult to decide which lesion is responsible for the patient's symptoms. Any mistaken supposition may result in either under treatment or over treatment. There is no consensus on the standard treatment of Tarlov cyst. Different modalities of treatment have been suggested and controversially discussed in the areas of failure, recurrence and complications. These procedures include percutaneous drainage with or without fibrin glue placement, fenestration and imbrication, partial excision with or without fat or muscle graft, total excision of the cyst, lumboperi-toneal shunt or cyst-subarachnoid shunt^(12,15,17,19,20).

The realization that Tarlov cysts may be another cause of lumbosacral spine symptoms has led to more attention to the presence of the cysts. More reported cases and further studies on Tarlov cysts are necessary to more understanding about the pathophysiology of the cysts and finally to establish the effective standard treatment.

References

1. Tarlov IM. Perineurial cysts of the spinal nerve root. *AMA Arch Neurol Psychiatry* 1938; 40: 1067-74.
2. Tarlov IM. Cysts of the sacral nerve roots; clinical significance and pathogenesis. *AMA Arch Neurol*

- Psychiatry 1952; 68: 94-108.
3. Tarlov IM. Spinal perineurial and meningeal cysts. J Neurol Neurosurg Psychiatry 1970; 33: 833-43.
 4. Nabors MW, Pait TG, Byrd EB, Karim NO, Davis DO, Kobrine AI, et al. Updated assessment and current classification of spinal meningeal cysts. J Neurosurg 1988; 68: 366-77.
 5. Kato T, Takamura H, Goto S, Sasaki H, Makino K, Ozaki N, et al. Sacral perineural cyst - report of a case. No Shinkei Geka 1988; 16: 893-7.
 6. ArunKumar MJ, Selvapandian S, Chandy MJ. Sacral nerve root cysts: a review on pathophysiology. Neurol India 1999; 47: 61-4.
 7. Voyadzis JM, Bhargava P, Henderson FC. Tarlov cysts: a study of 10 cases with review of the literature. J Neurosurg 2001; 95: 25-32.
 8. Jain SK, Chopra S, Bagaria H, Mathur PP. Sacral perineural cyst presenting as chronic perineal pain: a case report. Neurol India 2002; 50: 514-5.
 9. Uemura K, Komatsu Y, Shibata T, Kobayashi E, Nose T. Sacral meningeal cyst associated with valve-like mechanism - case report. Neurol Med Chir (Tokyo) 2001; 41: 288-91.
 10. Holt S, Yates PO. Cervical nerve root "CYSTS". Brain 1964; 87: 481-90.
 11. North RB, Kidd DH, Wang H. Occult, bilateral anterior sacral and intrasacral meningeal and perineurial cysts: case report and review of the literature. Neurosurgery 1990; 27: 981-6.
 12. Bartels RH, van Overbeeke JJ. Lumbar cerebrospinal fluid drainage for symptomatic sacral nerve root cysts: an adjuvant diagnostic procedure and/or alternative treatment? Technical case report. Neurosurgery 1997; 40: 861-4.
 13. Nadler SF, Bartoli LM, Stitik TP, Chen B. Tarlov cyst as a rare cause of S1 radiculopathy: a case report. Arch Phys Med Rehabil 2001; 82: 689-90.
 14. Rodziewicz GS, Kaufman B, Spetzler RF. Diagnosis of sacral perineural cysts by nuclear magnetic resonance. Surg Neurol 1984; 22: 50-2.
 15. Patel MR, Louie W, Rachlin J. Percutaneous fibrin glue therapy of meningeal cysts of the sacral spine. AJR Am J Roentgenol 1997; 168: 367-70.
 16. Langdown AJ, Grundy JR, Birch NC. The clinical relevance of Tarlov cysts. J Spinal Disord Tech 2005; 18: 29-33.
 17. Mummaneni PV, Pitts LH, McCormack BM, Corroo JM, Weinstein PR. Microsurgical treatment of symptomatic sacral Tarlov cysts. Neurosurgery 2000; 47: 74-8.
 18. Paulsen RD, Call GA, Murtagh FR. Prevalence and percutaneous drainage of cysts of the sacral nerve root sheath (Tarlov cysts). AJNR Am J Neuroradiol 1994; 15: 293-7.
 19. Morio Y, Nanjo Y, Nagashima H, Minamizaki T, Teshima R. Sacral cyst managed with cyst-subarachnoid shunt: a technical case report. Spine 2001; 26: 451-3.
 20. Caspar W, Papavero L, Nabhan A, Loew C, Ahlhelm F. Microsurgical excision of symptomatic sacral perineurial cysts: a study of 15 cases. Surg Neurol 2003; 59: 101-5.

ถุงน้ำ Tarlov ที่ก่อให้เกิดอาการ: รายงานผู้ป่วย และทบทวนบทนิพนธ์

ประดิษฐ์ ไชยบุตร, กิตติ สุวรรณประทีป

ถุงน้ำ Tarlov เป็นถุงน้ำที่เกิดบริเวณรากประสาท ซึ่งพบบ่อยที่กระดูกสันหลังระดับ sacrum ถุงน้ำเกิดขึ้นระหว่างเยื่อหุ้มเส้นประสาทชั้น perineurium และชั้น endoneurium ในตำแหน่งที่ใกล้กับ dorsal root ganglion ถุงน้ำชนิดนี้พบได้ไม่น้อย แต่มักไม่ก่อให้เกิดอาการใด ๆ หากถุงน้ำชนิดนี้มีแรงกดต่อเนื้อเยื่อประสาทบริเวณใกล้เคียงมากพอ จะทำให้เกิดอาการปวด อาการรากประสาทถูกกดทับ และกลุ่มอาการ cauda equina

ผู้วิจัยได้นำเสนอผู้ป่วยหนึ่งราย ซึ่งตรวจพบถุงน้ำ Tarlov สองถุงบริเวณระดับกระดูก sacrum ข้อที่สองจากการตรวจด้วยคลื่นแม่เหล็กไฟฟ้า (MRI) อาการเริ่มต้นของผู้ป่วยคืออาการปวดหลัง และร้าวลงขาข้างซ้าย ต่อมาอาการรุนแรงขึ้นปรากฏเป็นกลุ่มอาการ cauda equina ผู้ป่วยได้รับการรักษาด้วยการผ่าตัด อาการของผู้ป่วยหายไปและไม่กลับมามีอาการใหม่อีกเป็นระยะเวลาเกินเดือนที่ได้ติดตามผู้ป่วย รายงานนี้เป็นรายงานแรกในประเทศไทย