

Determination of the Ovarian Stages in Wild Persian Sturgeon, *Acipenser persicus*

Mahboubeh HOSSENZADE*, Mohammad Reza IMANPOOR,
Seyed Mostafa AGHILINEJAD and Ali SHABANI

Department of Fishery, Gorgan University of Agricultural Sciences and Natural Resources, Gorgan, Iran

(*Corresponding author's e-mail: M.Hoseinzade89@gmail.com)

Received: 29 November 2012, Revised: 16 January 2013, Accepted: 9 March 2013

Abstract

In the present study we investigated the histological changes in the ovary of 35 female Persian sturgeon. Ovarian samples were taken from the females stained with hematoxylin and eosin (H&E) staining and sexual maturity was determined by examining the sections under a light microscope. Four developmental stages of ovary including cortical alveoli formation stage (II), vitellogenic stage (III), mature stage (IV) and ovulation stage (V) were recognized during development. The gonadosomatic index (GSI) of female Persian sturgeon gradually increased during the development of ovary. The lowest GSI was recorded in stage II (2.57 ± 0.28) and the highest GSI was shown in stage V (23.58 ± 1.08). Therefore, GSI may be useful to determining maturity stages; however histological experiments of ovaries should be considered as the most accurate method for all stages.

Keywords: *Acipenser persicus*, histological experiment, gonadosomatic index (GSI), maturity stages, Caspian Sea

Introduction

Histological studies are currently used in many biological phenomena such as fish reproduction to invent new and effective methods for increasing efficiency of broodstock, increasing fish production and ultimately increased efficiency of predicting fish. Determining the peak period of spawning assessment and exploitation of fish, understanding the biological characteristics and life cycle of a species and reconstruction play important roles [1].

Successful management of sturgeon populations requires knowledge of the stock composition with regard to sex and maturational status [2]. Sexual maturation is delayed in sturgeons and paddlefishes. Gametogenesis and gonadal cycles were elucidated in cultured *Acipenser baerii* [3], the hybrid *Huso huso* \times *A. ruthenus* [1,4], *A. schrenckii* [5], and *A. transmontanus* [6]. When the primary oocyte enters the diplotene stage of the first meiotic division, karyokinesis is arrested and cell division halts until the final stage of sexual maturation. The primary oocyte then undergoes a series of changes to a vitellogenic oocyte, a secondary oocyte, and finally a fully matured ovulated oocyte. The growth from oogonium to mature oocyte is considerable. This increase in size is attributable mainly to accumulation of yolk proteins. The gonadosomatic index (GSI) of the ovary increases in concert with the increasing size of the oocytes [7].

The Persian sturgeon, *Acipenser persicus*, is a vulnerable anadromous fish for which a biological conservation program exists in the southern part of Caspian Sea [8]. Sexual maturity in sturgeon fish is reached under natural conditions after 8 to 13 years in males and after 10 to 16 years in females [9]. However, under aquaculture conditions, sturgeon maturity is usually reached at an earlier age [6]. In older females approaching puberty, information on ovarian developmental stage is critical for the quality of

caviar production. It should be borne in mind that vitellogenesis in cultured sturgeons can last up to 3 or 4 years [6] with large variations among individual fish of the same age [1,4]. Therefore, estimating the optimal time for caviar harvest requires several examinations of each individual female [10]. Since the complexity of most biological problems to obtain oocytes and the oocytes for the required artificial amplification, a defined manufacturing processes for more oocytes requires a detailed knowledge of biology and ovarian development. Sturgeons are not obviously sexually dimorphic; therefore, sex and stage of maturity are currently determined through histological studies [2].

Therefore, this study investigated growth and ovarian development of Persian sturgeon in the southeast Caspian Sea. Histological studies are able to provide the necessary and appropriate strategies for optimum utilization and maintain supplies of this valuable species.

Materials and methods

Fish Collection

The study was conducted between May 2010 and May 2011. In this study, 35 specimens of female Persian sturgeon (*A. persicus*) were captured every season from the southeast Caspian Sea during a year (Number of fish collected per season was 17, 8, 11 and 3 in April, summer, autumn and winter, respectively). Total weight and fork length of the fishes were measured. The data are reported as Mean \pm SD.

Histological Experiments

The fish, after they had been sacrificed were weighed using the gonad removed weight (kg) and examined microscopically. Pieces of gonads were cut and the gonad samples were fixed in Bouin's fluid for 48 h and then transferred to 70 % ethanol for storage until processing for light microscopy. Paraffin sections of 4 - 7 μ m were stained with hematoxylin and eosin (H&E). The captured fish in late winter and early spring that were in stage III-IV or IV were transferred to the Shahid Marjani sturgeon Propagation Center in Gorgan, Iran. Two injections of sturgeon pituitary preparation (PP) (3 - 5 mg/kg) were used to simulate the final maturation (stage V). The first injection PP (5 % of total dose) was made at 10 pm and the second (95 % of total dose) 12 h later at 8 AM. 24 h after the second injection the gonad was removed, weighed (kg) and examined microscopically. Sexual maturity was determined by examining the sections under a light microscope. We classified the gonad developmental stages according to the system of Amiri *et al.* [1,4].

Calculations of GSI

The GSI of female fish was calculated by dividing the ovaries weight (WG) by the whole body weight (WT) and multiplying by 100 [11].

$$\text{GSI} = \text{WG} / \text{WT} \times 100 \quad (1)$$

All data are expressed as means \pm SD. The SPSS 16 software was used for statistical analyses. Differences in the mean responses among different stages in GSI were assessed by one-way ANOVA, Duncan's multiple range tests. The significant differences were determined at $P < 0.05$.

Results

Mean total weight (27.11 ± 5.45 kg) and mean fork length (153.72 ± 19 cm) of the fishes were measured.

Four ovarian stages of Persian sturgeon are recognized during development.

1. Cortical alveoli formation stage (II)
2. Vitellogenic stage (III)
3. Mature stage (IV)
4. Ovulation stage (V)

The observation via light microscopy in this study revealed different histological structure of the oocytes in each ovarian developmental stage.

Stage II: This stage is characterized by the appearance of clear vesicles in the cytoplasm. The vesicle was begun to accumulate from the periphery of the oocyte. The nucleoli were still perinucleolar. In this stage, a thin acidophilic zona radiata or primary envelope became visible for the first time. Follicular layers were also seen at the first time. Adipose tissue was observed clearly (**Figure 1A**).

Stage III: The oocyte size increased. Yolk granules were visible as a ring of deep eosinophilic inclusions in the cytoplasm and later incorporated into the whole cytoplasmic area. The nucleus was still convoluted. The zona radiata was clearly visible as a non-cellular deep eosinophilic band (**Figure 1B**).

Stage IV: The oocyte has become larger and more hydrated, and the nucleus has migrated toward the periphery and is in the process of dissolution (**Figure 1C**).

Stage V: During ovulation the oocytes detach from the follicle cells. Oocytes were characterized by large mass of yolk. Oocytes have hydrated and the appearance of flowing sexual products is noted, commencement of spawning is ready to begin (**Figure 1D**).

GSI in stage II was very small (2.57 ± 0.28 %) and GSI in stage III and IV increased and reached 13.37 ± 0.42 and 21.51 ± 1.49 %, respectively. It was highest in stage V (23.58 ± 1.08 %) (**Figure 2**).

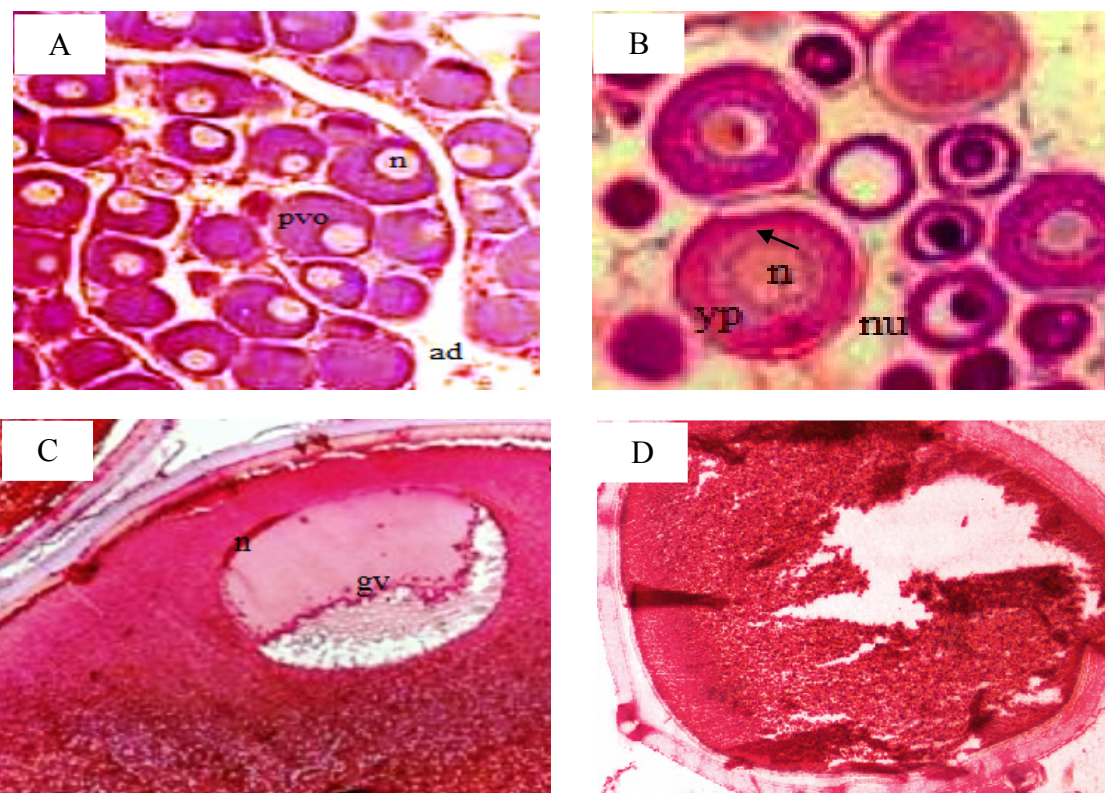


Figure 1 Histological sections of Persian sturgeon. Cortical alveoli formation stage 10X and X20 (A), Vitellogenic (yolk) stage 10X and X20 (B), Mature stage 10X and X20 (C). Ovulation stage 10X and X20 (D). ad: adipose tissue, gv: germinal vesicle, n: nucleus, nu: nucleolus, pvo: pre-vitellogenic oocytes, yp: yolk platelets.

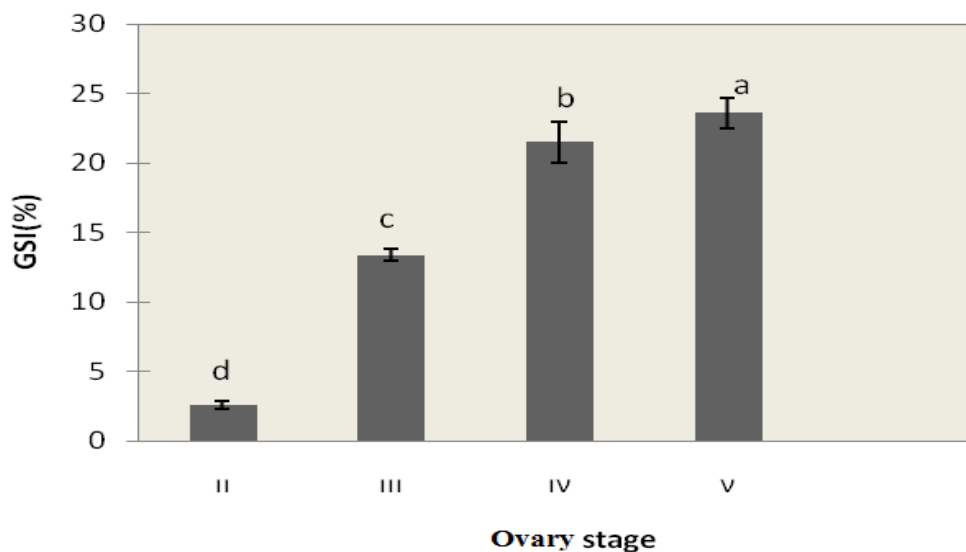


Figure 2 Changes in GSI by ovary stage of Persian sturgeon. Each value is Mean \pm SD. Means with different subscript letters are significantly different ($P < 0.05$).

Discussion

Female reproductive maturity was commonly quantified by the GSI [12]. Our results showed that the GSI of female Persian sturgeon increased during the development of the ovary. Under vitellogenic oocytes (stage III) GSI increased and are highest in stage V (**Figure 2**). Oocytes development in the ovary and increases in GSI were correlated with changes in serum E2 levels [13]. Some researchers found that female Russian sturgeon at the age of 3 and 4 years exhibit gonads at the pre-vitellogenic stage (stage II), with small oocytes and low GSI [14]. These results are in agreement with our study.

The GSI of the fish in the present study is correlated with the development of the gonad. However, determination of reproductive maturity using only the GSI is not enough because the structures within the ovary such as oocytes at different stages, interstitial tissue with accumulation of yolk materials, cannot be interpreted by weight. Direct observation of histological architecture is the most accurate method to let us know exactly the stage of maturation at the ovary [15].

The present study on the ovarian histology of Persian sturgeon revealed the basic histological architecture and identified the oocytes found within the ovary. It provides a basic knowledge for other studies such as reproductive biology.

Histological changes in the ovary during the reproductive cycle were similar in another species. Briefly Oogonia proliferate through mitotic division of primary germ cells, and transform into previtellogenic oocytes, characteristic of the immature ovary. The elaboration of yolk in the oocyte marks the beginning of vitellogenesis at the end of which the cell attains its maximum size and undergoes maturation/ovulation, followed by the extrusion of egg to the exterior [16].

Female gametogenesis comprises several developmental steps and consists of oogenesis, oocyte growth, maturation, and ovulation. Primordial germ cells differentiate into oogonia under the influence of early gene cascades and steroid signaling. Oocyte growth is triggered by gonadotropins, and the subsequent steroidogenic production of estradiol induces vitellogenesis, leading to a marked enlargement in oocyte size. Neuroendocrine factors including stimulatory and inhibitory signals are regarded as major regulators of oocyte development and mediators of environmental and physiological cues. Maturation requires meiotic resumption, and is triggered both by gonadotropins and maturation-inducing hormones. Gonadotropin signals are mediated or modulated in the ovary by a complex local paracrine network of

peptide factors [17].

The rhythm of deposition of yolk inclusions in the oocyte of fish differs from species to species. In *Tilapia mossambica*, lipid vesicles and yolk granules appear in the oocyte at the same time [18]. In other teleost, lipid vesicles are the first type of yolk inclusion to appear in vitellogenic oocytes, their appearance marking the onset of vitellogenesis [19,20]. The results of the present study are in agreement with those of latter researchers, that lipid yolk appears first in the oocyte before the elaboration of yolk granules as the second type of yolk inclusion.

Conclusions

The histology of ovary in Persian sturgeon is similar to other fish species. This information is of importance to commercial farming of Persian sturgeon aimed at caviar production and reproduction. Also, the results of the present study are vital to estimating the optimal time for caviar harvest.

Acknowledgment

The authors would like to thank Gorgan University of Agricultural Sciences and Natural Resources for providing the necessary facilities for the study. The authors are grateful to H. Nekoubin and Shahid Marjani at the sturgeon Propagation Center in Gorgan, Iran, for helping in our study.

References

- [1] B Amiri, A Maebayashi, S Hara, A Adachi and K Yamauchi. Ovarian development and serum sex steroid and vitellogenin profiles in the female cultured sturgeon hybrid, the bester. *J. Fish Biol.* 1996; **48**, 1164-78.
- [2] MAH Webb and GW Feist. Potential classification of sex and stage of gonadal maturity of wild white sturgeon using blood plasma indicators. *J. Trans. Am. Fish. Soc.* 2002; **131**, 132-42.
- [3] F Le-Menn and C Pelissero. *Histological and Ultrastructural Studies of Oogenesis of the Siberian Sturgeon*. In: P Williot (ed.). Acipenser, CEMAGRAEF Published, 1991, p. 113-7.
- [4] BM Amiri, M Maebayashi, S Adachi and K Yamauchi. Testicular development and serum sex steroid profiles during the annual sexual cycle of the male sturgeon hybrid, the bester. *J. Fish Biol.* 1996; **48**, 1039-50.
- [5] LZ Zhang, P Zhuang and T Zhang. Gonadal development of cultured Amur sturgeon, *Acipenser shrenckii*. *J. Fish Sci. China* 2002; **9**, 321-7.
- [6] SL Doroshov, GP Moberg and LP Van Eenennaam. Observation on the reproductive cycle of cultured white sturgeon, *Acipenser transmontanus*. *J. Environ. Biol. Fish.* 1997; **48**, 265-78.
- [7] JT Silverstein and BC Small. *Biology and Culture of Channel Catfish*. In: CS Tucker and JA Hargreaves (eds.). Elsevier, 2004, p. 69-94.
- [8] BH Kiabi, A Abdoli and N Naderi. Status of the fish fauna in the south Caspian basin of Iran. *Zool. Middle East* 1999; **18**, 57-65.
- [9] M Hochleithner and J Gessner. The Sturgeon and Paddlefishes of the world. *J. Appl. Ichthyol.* 1999; **15**, 4-5, 281.
- [10] A Hurvitz, K Jackson, G Degani and B Levavi-Sivan. Use of endoscopy for gender and ovarian stage determinations in Russian sturgeon, *Acipenser gueldenstaedtii*, grown in aquaculture. *J. Aquaculture* 2007; **270**, 158-66.
- [11] DA Roff. An allocation model of growth and reproduction in fish. *Can. J. Fish. Aquat. Sci.* 1983; **9**, 1395-404.
- [12] RH Lowe-McConnell. Tilapias in fish communities. In: Proceedings of the International Conference on the Biology and Culture of Tilapias, Bellagio, Italy, 1982, p. 83-113.
- [13] LW Crim and DR Idler. Plasma gonadotropin, estradiol, and vitellogenin and gonad phosphovitin levels in relation to the seasonal reproductive cycles of female brown trout. *Ann. Biol. Anim. Biochim. Biophys* 1978, **18**: 1001-5.

- [14] K Jackson, A Hurvitz, S Yom Din, D Goldberg, O Pearlson, G Degani and B Levavi-Sivan. Anatomical, hormonal and histological descriptions of captive Russian sturgeon (*Acipenser gueldenstaedtii*) with intersex gonads. *Gen. Comp. Endocrinol.* 2006, **148**: 359-67.
- [15] J Srijunngam and K Wattanasirmkit. Histological structures of Nile Tilapia, *Oreochromis niloticus*, ovary. *Nat. Hist. J. Chulalongkorn University* 2001; **1**, 53-9.
- [16] F Abou-Seedo, S Dadzin, and KA Al-Anaan. Histology of ovarian development and maturity stages in the yellowfin seabream, *Acanthopagrus latus*, reared in cages. *Kuwait J. Sci. Eng.* 2003; **30**, 121-37.
- [17] R Urbatzka, MJ Rocha and E Rocha. *Hormones and Reproduction of Vertebrates*. In: DO Norris and KH Lopez (eds.). Regulation of ovarian development and function in teleost. Elsevier, 2011, p. 84-101.
- [18] S Dadzie. Oogenesis and the stage of maturation in the female cichlid fish, *Tilapia mossambica*. *Ghana J. Sci.* 1974; **14**, 23-31.
- [19] MD Wiegand. Vitellogenesis in Fishes. In: CCJ Richter and HJT Goos (eds.). Reproductive physiology of fish. Pudoc, Wageningen, 1982, p. 136-46.
- [20] S Dadzie, F Abou-Seedo and T Al-Shallal. Histological and histochemical study of oocyte development in the silver pomfret, *Pampus argenteus* (Euphrasen), in Kuwait water. *Arab Gulf J. Sci. Res.* 2000; **18**, 23-31.