

# Double Inferior Vena Cava Co-Existing with Abdominal Aortic Aneurysm: A Case Report and Literature Review

Nootchanat Mairuae and Kritsana Homwutthiwong\*

Faculty of Medicine, Mahasarakham University,  
296 Nakhornsawan Road, Talad Subdistrict Muang District, Maha Sarakham 44000, Thailand

## Abstract

The embryogenesis of the inferior vena cava is a complex process involving multiple steps for the three pairs of embryonic veins. Improper completion of this process may lead to anatomic anomalies of the inferior vena cava (IVC) and its tributaries. A rare case of combined double inferior vena cava (DIVC) with abdominal aortic aneurysm (AAA) is described in a 60-year-old Thai male cadaver. This case is discussed, together with embryogenesis, the congenital anomalies of DIVC and IVCs in general, and the clinical significance of these anatomical conditions. We conclude that it is important for physicians and medical educators to have a comprehensive knowledge not just of normal anatomy but also of anatomical variations of the IVC.

**Keywords:** Double inferior vena cava; Abdominal aortic aneurysm; Anatomical variation; Renal vein; Testicular vein

## Abbreviation

AA	Abdominal aorta
AAA	Abdominal aortic aneurysm
CIV	Common iliac vein
DIVC	Double inferior vena cava
IVC	Inferior vena cava
IICV	Interiliac communicating vein
IIV	Internal iliac vein
LIVC	Left inferior vena cava

## 1. Introduction

Congenital anomalies of the inferior vena cava (IVC) result mainly from abnormal embryological development. These anomalies occur in 0.4 – 4.0% of the population [1]. Among these anomalies, double IVC (DIVC) is the most common, with an incidence of 0.2 – 3.0% [2-3]. There are 2 large veins that run bilateral of the abdominal aorta that consist of right IVC (RIVC) and left IVC (LIVC), which

join at the level of the kidney to become one vein [4]. Most double IVC (DIVC) cases are asymptomatic and diagnosed incidentally by imaging, usually with magnetic resonance imaging (MRI) or computed tomography (CT) scanning performed for other reasons, or they are found unexpectedly at the time of resection of abdominal aortic aneurysm, or during investigation of venous system anomalies, or dissection of cadavers [5-9]. Many reports have been published on IVC variations but few have focused on the coexistence of DIVC and abdominal aortic aneurysm (AAA). These anomalies are rare and have significant clinical implications, especially during abdominal aortic surgery. An unexpected severe hemorrhage in this operation is usually caused by unexpected venous injury [10-13]. It is also clinically important in certain situations in laparoscopic nephrectomy [14] and for the treatment of

thromboembolic diseases [15]. A double IVC can be misdiagnosed as a pathological lesion, such as a lymphadenopathy [16] or left pyelo-ureteric dilatation [17].

Comprehensive knowledge not just of normal anatomy but also anatomical variations of the IVC is important for establishing the presence of an associated venous anomaly and reducing the associated risks during abdominal surgery. Herein we present a case of the coexistence of DIVC with a typical confluence of the left renal vein and the left inferior vena cava with AAA, which was observed during routine dissection of a 60-year-old Thai male cadaver. We also discuss the embryological and clinical significance, and review the main types of this anatomical variation reported to date in the literature.

## 2. Materials and Methods

Vascular anomalies were observed during routine dissection of a 60-year-old Thai male cadaver in a gross anatomy class. The calibers of the vessels were measured with compasses and a ruler as described in previous studies [18-20].

## 3. Results

During routine retroperitoneal dissection of a 60-year-old Thai male cadaver in a gross anatomy class, DIVC was detected together with an AAA Figure 1. Medical records accompanying the cadaver indicated the man had died from heart disease. The two inferior vena cava originated in the pelvis and ascended bilaterally along the abdominal aorta. The RIVC ascended along the right side of the abdominal aorta. The RIVC was 20 mm in diameter and 70 mm in length and its diameter increased to 25 mm after receiving the right renal vein. The RIVC continued to ascend and ended at the inferior part of the right atrium of the heart.

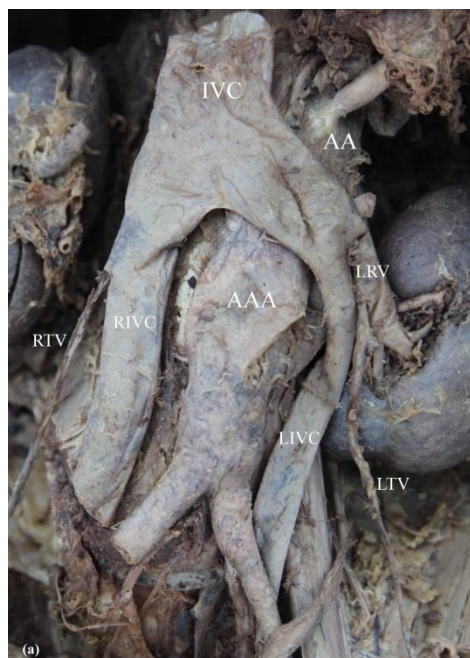
The LIVC coursed cranially along the left side of the abdominal aorta and terminated by joining with the left renal vein (LRV). It was 76 mm long with a diameter of 9 mm. The

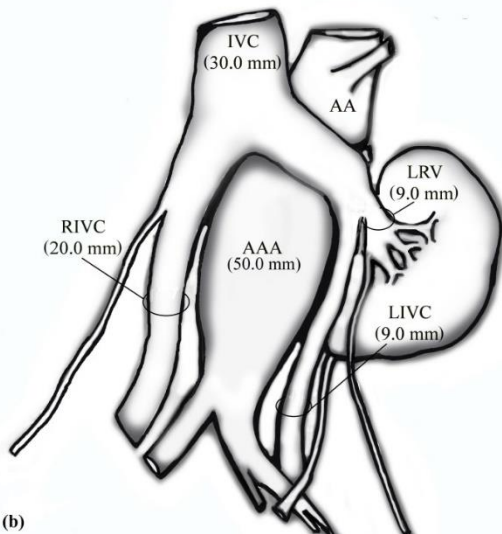
LRV was 9 mm in diameter before coalescing with the LIVC and 15 mm in diameter in the PT between the right and left IVC in front of the abdominal aorta (AA).

Both testicular veins had a straight shape and opened into an ipsilateral DIVC. At the level of the left kidney, the left testicular vein (LTV) opened into the LRV near its termination, while the right testicular vein (RTV) opened directly into the RIVC.

The AAA was located between the RIVC and LIVC and began about 40 mm below the renal arteries not involving the bifurcation, and had a maximum transverse diameter of 50 mm. The diameters of the aorta before bifurcation, and of the right and left common iliac arteries, were 30 mm, 13 mm, and 15 mm, respectively.

Other important measurements of the vessels of the abdomen are presented on the schematic arrangement Figure 1b. The origin, the course, and the territories of the other vessels followed the normal pattern. The kidneys and the ureters were also normal. No other anatomical anomalies were encountered.



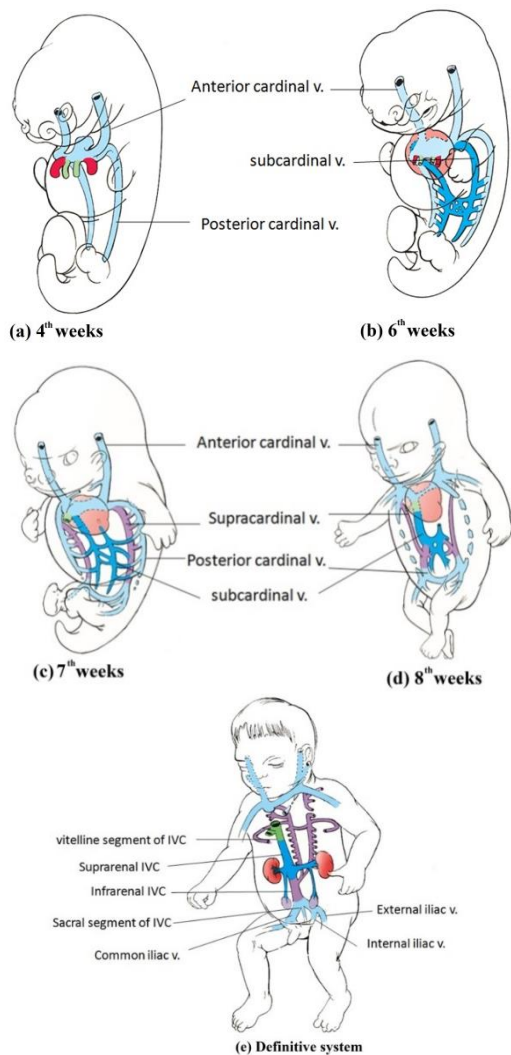


(b)  
**Figure 1.** Photograph (a) and schematic drawing (b) of the double inferior vena cava.

#### 4. Discussion

Embryogenesis of the IVC is a complex but well-characterized event. It occurs during the 4<sup>th</sup>- 8<sup>th</sup> week of gestation [1], and consists of multiple steps involving the development, regression, anastomosis and replacement of the three paired embryonic veins [2,21]. In order of their appearance, these are the posterior cardinal veins, the subcardinal veins, and the supracardinal veins. The posterior cardinal veins appear first and these veins regress, except for the distal aspects which become the sacral segment of the IVC, common iliac veins, internal and external iliac veins. Then the left and right subcardinal veins grow caudally and medial to the posterior cardinal veins. The right subcardinal vein remains to form the segment of IVC between the liver and the kidneys called the suprarenal IVC, while the left subcardinal vein completely regresses. Subsequently, a new pair of supracardinal veins develop, located directly posterior to the aorta. The left supracardinal vein then regresses, and the right supracardinal vein forms an abdominal segment of the IVC which is located inferior to the kidneys and called the infrarenal IVC [22]. The normal IVC is converted to a unilateral, right-sided

system, consisting of four components from the following embryonic structures: (1) the terminal (suprahepatic) segment from the right vitelline vein, (2) the suprarenal segment between the liver and the kidneys from the right vitelline vein and the right subcardinal vein, (3) the abdominal IVC (infrarenal IVC) from the right supracardinal vein, and (4) the sacral segment of the IVC from the most distal part of the bilateral posterior cardinal veins and the right supracardinal vein. Figure 2 shows the development of the IVC from the cardinal veins [22-23].



**Figure 2.** Development of the inferior vena cava: (a) 4 weeks, (b) 6 weeks, (c) 7 weeks, (d) 8 weeks, and (e) definitive system.

Because development of the IVC is a complex process, abnormalities during any step in its formation can result in congenital anomalies. Fifteen types of IVC anomaly have been reported in mammals [24]. The most commonly used classification system is based

on the embryonic vein that the anomaly is derived from [21]. Major clinically important anomalies of the IVC, together with information on their incidence, are listed in Table 1.

**Table 1.** Classification of IVC anomalies and their incidence in humans.

<b>Classification of IVC anomalies</b>	<b>Incidence</b>	<b>Study</b>
<b>Anomalies of the postcardinal veins</b>		
- Retrocaval/circumcaval ureter	< 0.1%	[25-28]
<b>Anomalies of the subcardinal veins</b>		
- Interruption of the inferior vena cava with azygous / hemiazygous continuation	0.6%	[2]
<b>Anomalies of the supracardinal veins</b>		
- Persistence of the left supracardinal vein: Left inferior vena cava	0.2 - 0.5%	[29]
- Persistence of both left and right supracardinal veins: Double inferior vena cava	0.2 - 3.0%	[2,30]
<b>Anomalies of the renal segment</b>		
- Circumaortic venous ring	1.6 - 14.0%	[31-32]
- Retroaortic renal vein	3.2%	[32]
- Multiple renal veins	9.7%	[33]

DIVC is one of the most common of all the IVC anomalies, and is considered to be due to the persistence of both supracardinal veins [2]. Normally, the double LIVC drains into the LRV, which then crosses anterior to the aorta (preaortic trunk; PT) and joins the RIVC. This is called incomplete DIVC [3]. The LIVC is smaller than the RIVC and the normal LRV could be attributed to inadequate obstruction of the vessel, resulting in persistence of the aberrant vessel [7].

In our case, the LIVC did not drain into the LRV, but after receiving the LRV it continued with a major PT that travelled obliquely and emptied into the RIVC. This anomaly is known as a complete DIVC, as classified by Natsis et al. [7]. The most common etiology of complete DIVC is persistence of the left suprasubcardinal and postsubcardinal anastomosis, and probably of the intersubcardinal anastomosis, which in turn results in persistence of the left

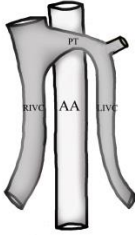
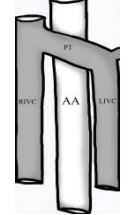
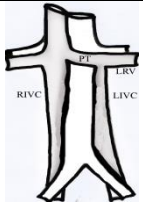
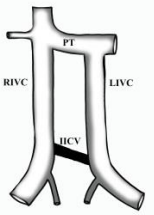
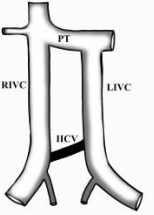
supracardinal vein. Complete DIVC is further classified into three types according to the size of the right and left IVC and the presence of the PT [7]. A type I or major double comprises of two bilaterally symmetrical trunks and a PT of the same caliber. A type II or minor double comprises of two bilaterally symmetrical trunks, smaller than the PT. A type III or asymmetric double comprises of a small LIVC, larger RIVC and even larger PT. Our case may be classified as a complete DIVC type III.

Other authors have further classified DIVCs according to the pattern of interiliac (communicating) veins (IICV). An IICV is defined as a vein that drains blood from the iliac veins, including the common, internal, or external iliac veins, into the contralateral side of the DIVC [22, 34]. An IICV originates from iliac anastomosis between the posterior cardinal veins, displays various patterns and interconnects the two IVCs [19, 22, 35]. Based on this, Chen et al [22] classified four types of DIVC as follows: type 2a, DIVC with no IICV; type 2b, DIVC with IICV from the left common iliac vein (CIV); type 2c, DIVC with IICV from the right CIV; and type 2d, IICV connecting the DIVC, runs transversely. Morita et al. [34] classified five types of DIVC with types 2a, 2b and 2c defined in accordance with the recommendations of Chen et al. [22]. Type 2d was defined as a DIVC with an IICV from the left internal iliac vein (IIV), and type 2e was defined as a DIVC with an IICV from the right IIV. According to both Chen et al. [22] and Morita et al. [34], our case may be classified as type 2a.

Clinically, an IICV has the potential to interfere with and cause problems during related surgery and interventional radiology. In anterior lumbar interbody fusion (ALIF), this vein might cause problems due to unexpected hemorrhage during retroperitoneal surgery because it runs across and in front of the anterior lumbar and sacral region. It might also cause problems during IVC filter placement because congenital IVC anomalies are a risk factor for deep venous thrombosis and this vein therefore serves as a decisive factor in determining the strategy for venous interventional radiology [22, 34].

The most detailed descriptions of DIVC are from anatomical studies of cadavers dissected during medical school anatomy courses [36]. Additionally in recent years, DIVCs have increasingly been reported following the use of advanced computed tomography angiography methods to investigate IVC anomalies [37]. There are multiple classification systems for DIVCs, which we have reviewed here and used to characterize our case Table 2.

**Table 2.** Types of DIVC variation reported by various authors and their classification according to gross appearance.

Study	Descriptive method	Schematic illustration of IVC anatomy	Classification		
			Natsis 2010	Morita 2007	Chen 2012
Our case	Cadaver dissection		Complete type III	2a	2a
Itoh et al. [38]	Cadaver dissection		Complete type III		
Polgui et al. [20]	Computer Tomography		Complete type III		
Castro et al. [39]	Computer Tomography		Complete type I		
Raza et al. [40]	Organ transplantation		Complete type I		
Saad et al. [36]	Phlebography		Complete type I		
Tanka [41]	Computer Tomography		Incomplete		
Yano et al. [19]	Cadaver dissection			2b	2b
Chen et al. [22]	Cadaver dissection			2b	2b
Sartori et al. [42]	Phlebography			2c	2c
Xue et al. [43]	Cadaver dissection			2c	2c
Benerjee et al. [35]	Cadaver dissection			2c	2c

According to a radiological report by Morita et al. [34], IVC anomalies are significantly more common in men (39 of 3821 cases – 1%) than in women (12 of 2473 cases – 0.5%); men/women ratio is 2:1 ( $p=0.02$ ). A study by Chen et al. [22] confirmed this finding. Chen et al. analyzed 109 cases of IVC anomalies published in the literature between 1967 and 2011 and found that the ratio of men/women is 72:37.

Kudo et al. found that multiple renal veins are common on the right side (up to 15%), whereas anomalies on the left side are rare. The incidence of retroaortic left renal vein was found to be 1.2–3.3%. The incidence of circumaortic left renal vein was reported to be 1.5–8.7% in one study and 2.5% in another [13]. In our case, the left and right renal veins followed the normal pattern. This indicates the complexity of the underlying embryological development role that anastomoses plays in the different morphological patterns [7].

Anatomical variations of the testicular vein have been reported in previous studies [42, 44-45]. The testicular vein deviates from the normal pattern in 21.3% of specimens. The most common pattern of variation was a double, and these were more common on the left side [46]. In the case of DIVC, the left gonadal vein (testicular vein in men, ovarian vein in women) tends to open into the left renal vein [40].

In the present case, the right testicular vein drained into the RIVC caudal to the right renal vein, while the single LTV drained into the LRV on the level of the renal hilum. This indicates that anastomosis between the left supracardinal vein and the left side of the subcardinal sinus differs from that on the right side during embryogenesis. Additionally, this anatomical difference induces relatively weak haemodynamics in the LTV and is considered to be a cause of left-sided varicoceles [40]. Ipsilateral scrotal edema has also been reported in a case of laparoscopic left donor nephrectomy with a double inferior vena cava [14]. The left gonadal vein can be

misinterpreted as a DIVC because it runs close to the ipsilateral IVC and drains into the left renal vein [22].

According to previous literature, DIVC is a rare but well-recognized developmental variation [20]. However, its coexistence with AAA has only been described in a few studies. In these previous reports, the dual anomaly was detected in patients undergoing an abdominal CT scan for other diseases [20, 47], during abdominal aortic surgery [12,48], or during cadaveric dissection [18].

AAA can co-exist not just with DIVC but with other retroperitoneal venous anomalies. For example, AAA has been reported in patients with a left-sided inferior vena cava [6, 49-51], and in patients with a retroaortic left renal vein [13, 52].

The presence of a DIVC is unusual and poses a potential hazard to surgeons during abdominal aortic surgery [11, 20], or in other related procedures such as phlebography, renal vein sampling, retroperitoneal dissection, and renal operations [13]. In abdominal aortic surgery, excessive intraoperative bleeding is usually caused by unexpected venous injury hemorrhage [11-12]. Significant venous bleeding can occur if major retroperitoneal venous anomalies are present. Venous hemorrhage can be more troublesome than arterial hemorrhage [11]. Anomalous veins are typically thin-walled and dilated, so manipulation in these areas is challenging and poses a high risk of massive hemorrhage [17]. In summary, the incidence of DIVC is low, and most cases are diagnosed incidentally on imaging for other reasons. However, this venous anomaly has important clinical implications, particularly during retroperitoneal surgery and other interventional procedures.

## 5. Conclusion

Double IVC with an unusual confluence of the left renal vein to the left IVC, coexisting with abdominal aortic

aneurysm is a rare condition. However, it can lead to complications and is clinically important in situations such as retroperitoneal surgery. Therefore, it is very important for physicians and medical educators to have a comprehensive knowledge not just of normal anatomy but also of different types of anatomical variation of the IVC as well.

## 6. Acknowledgements

This study was carried out in the medical biology laboratory at Mahasarakham University Faculty of Medicine. The authors thank Dr. Tim Cushnie for language-editing assistance.

## 7. References

- [1] Mayo, J., Gray R., St Louis, E., Grosman, H., McLoughlin, M., and Wise, D., Anomalies of the Inferior Vena Cava, *AJR Am J Roentgenol*, Vol.140, No.2, pp.339–345, 1983.
- [2] Bass, J.E., Redwine, M.D., Kramer, L.A., Huynh, P.T., and Harris, J.H.Jr., Spectrum of Congenital Anomalies of the Inferior Vena Cava: Cross-sectional Imaging Findings, *Radiographics*, Vol. 20, No.3, pp. 639–52, 2000.
- [3] Ng, WT., and Ng, SS., Double Inferior Vena Cava: a Report of Three Cases, *Singapore Med J.*, Vol.50, No.6, pp.e211–213, 2009.
- [4] Tore, H.G., Tatar, I., Celik, H.H., Oto, A., Aldur, M.M., and Denk, C.C., Two Cases of Inferior Vena Cava Double with Their CT Findings and a Review of the literature Review, *Folia Morphol (Warsz)*, Vol. 64, No. 1, pp. 55–58, 2005.
- [5] Hans, S.S., and Gordon, M., Double Inferior Vena Cava and Abdominal Aortic Aneurysm, *J Cardiovasc Surg (Torino)*, Vol. 26, No. 1, pp.76–78, 1985.
- [6] Evers, D.J., Stoot, J.H., and Breslau, R.J., Symptomatic Abdominal Aortic Aneurysm with Inferior Vena Cava Malposition, *Acta Chir Belg*, Vol. 107, No. 6, pp. 693–4, 2007.
- [7] Natsis, K., Apostolidis, S., Noussios, G., Papathanasiou, E., Kyriazidou, A., and Vyzas, V., Double of the Inferior Vena Cava: Anatomy, Embryology and Classification Proposal, *Anat Sci Int*, Vol. 85, No. 1, pp. 56–60, 2010.
- [8] Kapetanakis, S., Papadopoulos, C., Galani, P., Dimitrakopoulou, G., and Fiska, A., Anomalies of the Inferior Vena Cava: a Report of Two Cases and a Short Review of the Literature, *Folia Morphol*, Vol. 69, No. 3, pp. 123–127, 2010.
- [9] Hayashi, S., Naito, M., Hirai, S., Terayama, H., Miyaki, T., Itoh, M., Fukuzawa, Y., and Nakano, T., Proposal for a New Classification of Variations in the Iliac Venous System Based on Internal Iliac Veins: a Case Series and a Review of Double and Left Inferior Vena Cava, *Anat Sci Int*, Vol. 88, No. 4, pp. 183–8, 2013
- [10] Baldrige, E.D. Jr., and Canos, A.J., Venous Anomalies Encountered in Aortoiliac Surgery, *Arch Surg*, Vol. 122, No. 10, pp. 1184–8,1987.
- [11] Bartle, E.J., Pearce, W.H., Sun, J.H., and Rutherford, R.B., Infrarenal Venous Anomalies and Aortic Surgery: Avoiding Vascular Injury, *J Vasc Surg*, Vol. 6, No. 6, pp. 590–593, 1987.
- [12] Shindo, S., Kubota, K., Kojima, A., Iyori, K., Ishimoto, T., Kobayashi, M., Kamiya, K., and Tada, Y., Anomalies of Inferior Vena Cava and Left Renal Vein: Risks in Aortic Surgery, *Ann Vasc Surg*, Vol. 14, No.4, pp. 393–6, 2000.
- [13] Kudo, F.A., Nishibe, T., Miyazaki, K., Flores, J., and Yasuda, K., Left Renal Vein Anomaly Associated with Abdominal Aortic Aneurysm Surgery: Report of a Case, *Surg Today*, Vol. 33, No. 8, pp.609–611, 2003.
- [14] Christakis, P.G., Cimsit, B., and Kulkarni, S., Complication



- Arising from a Double Inferior Vena Cava Following Laparoscopic Living Donor Nephrectomy: a Case Report, *Transplant Proc*, Vol. 44, No.5, pp.1450–1452, 2012.
- [15] Anne, N., Pallapothu, R., Holmes, R., and Johnson, M.D., Inferior Vena Cava Double and Deep Venous Thrombosis: Case Report and Review of Literature, *Ann Vasc Surg*, Vol. 19, No. 5, pp. 740–743, 2005.
- [16] Marrocco-Trischitta M.M., Scicchitano, G., Acconcia, A., and Stillo, F., Management of Synchronous Abdominal Aortic Aneurysm and Renal Carcinoma Associated with Double of the Inferior Vena Cava, *J Cardiovasc Surg (Torino)*, Vol. 42, No. 5, pp. 683–685, 2001.
- [17] Downey, R.S., Sicard, G.A., and Anderson, C.B., Major Retroperitoneal Venous Anomalies: Surgical Considerations. *Surgery*, Vol. 107, No. 4, pp. 359–365, 1990.
- [18] Khaledpour, C., Matanovic, P., Rienačker, J., and Groñniger, J., An Abdominal Aortic Aneurysm in Combination with Double of the Inferior Vena Cava, the Right Renal Artery and the Right Renal Vein, *Surg Radiol Anat*, Vol. 12, No.1, pp.73–76, 1990.
- [19] Yano, R., Hayakawa, D., Emura, S., Chen, H., Ozawa, Y., Taguchi, H., and Shoumura, S., Two Cases of the Double Inferior Venae Cavae. *Okajimas Folia Anat Jpn*, Vol. 77, No. 4, pp. 133–136, 2000.
- [20] Polguj, M., Majos, M., Topol, M., Majos A., and Stefańczyk L., The Influence of Atherosclerotic Abdominal Aorta on the Shape of Double Inferior vena Cava: Its Potential Clinical Implications and Vascular Complications, *Folia Morphol*, Vol. 73, No. 4, pp. 521–526, 2014.
- [21] Mathews, R., Smith, P.A., Fishman, E.K., and Marshall, F.F., Anomalies of the Inferior Vena Cava and Renal Veins: Embryologic and Surgical Considerations, *Urology*, Vol, 53, No. 5, pp. 873–880, 1999.
- [22] Chen, H., Emura, S., Nagasaki, S., and Kubo, K.Y., Double Inferior Vena Cava with Interiliac Vein: a Case Report and Literature Review, *Okajimas Folia Anat Jpn*, Vol. 88, No. 4, pp.147–151, 2012.
- [23] LEE, B.B., Venous Embryology: the Key to Understanding Anomalous Venous Conditions, *Phlebology*, Vol 19. No. 4, pp. 170–181, 2012.
- [24] Giordano, J.M., and Trout, H.H. 3rd., Anomalies of the Inferior Vena Cava, *J Vasc Surg*, Vol. 3, No. 6, pp. 924–928, 1986.
- [25] Crosse, J.E., Soderdahl, D.W., Teplick, S.K., and Clark, R.E., Nonobstructive Circumcaval (Retrocaval) Ureter. A Report of 12 Cases, *Radiology*, Vol.116, No.1, pp. 69–71, 1975.
- [26] Gefter, W.B., Arger, P.H., Mulhern, C.B., Pollack, H.M., and Wein, A.J., Computed Tomography of Circumcaval Ureter, *AJR Am J Roentgenol*, Vol.131, No. 16, pp.1086–1087, 1978.
- [27] Murphy, B.J., Casillas, J., and Becerra, J.L., Retrocaval Ureter: Computed Tomography and Ultrasound Appearance, *J Comput Tomogr*, Vol.11 No.1, pp. 89–93, 1987.
- [28] Lin, C.H., Steinberg, A.P., Ramani, A.P., Abreu, S.C., Desai, M.M., Kaouk, J., Goldfarb, D.A., and Gill, I.S., Laparoscopic Live Donor Nephrectomy in the Presence of Circumaortic or Retroaortic Left Renal Vein, *J Urol*, vol. 171, No. 1, pp. 44–46, 2004.
- [29] Onbas, O., Kantarci, M., Koplay, M., Olgun, H., Alper, F., Aydinli, B., Zirek, H., and Ceviz, N., Congenital Anomalies of the Aorta and Vena Cava: 16-detector-row CT Imaging Findings,

- Diagn Interv Radiol, Vol.14, No.3, pp. 163–171, 2008.
- [30] Friedland, G.W., deVries, P.A., Nino-Murcia, M., King, B.F., Leder, R.A., and Stevens, S., Congenital Anomalies of the Inferior Vena Cava: Embryogenesis and MR, Features, Urol Radiol, Vol. 13, No. 4, pp. 237–48, 1992.
- [31] Trigaux, J.P., Vandroogenbroek, S., De and Wispelaere, J.F., Congenital Anomalies of the Inferior Vena Cava and Left Renal Vein: Evaluation with Spiral CT, J Vasc Interv Radiol, Vol. 9, No. 2, pp. 339–345, 1998.
- [32] Aljabri, B., MacDonald, P.S., Satin, R., Stein, L.S., Obrand, D.I., and Steinmetz, O.K., Incidence of Major Venous and Renal Anomalies Relevant to Aortoiliac Surgery as Demonstrated by Computed Tomography, Ann Vasc Surg, Vol. 15, No.6, pp. 615–618, 2001.
- [33] Baptista-Silva, J. C., Veríssimo, M. J., Castro, M. J., Câmara, A. L., and Pestana, J. O. Anatomical Study of the Renal Veins Observed during 342 Living-donor Nephrectomies, Rev. Paul. Med, Vol.115, No. 3, pp. 1456–1459, 1997.
- [34] Morita, S., Higuchi, M., Saito, N., and Mitsuhashi, N., Pelvic Venous Variations in Patients with Congenital Inferior Vena Cava Anomalies: Classification with Computed Tomography, Acta Radiol, Vol. 48, No.9, pp.974–979, 2007.
- [35] Banerjee, A., Maharana, S., Kumar, I.A., and Jhansi, p., Double of the Inferior Vena Cava – Report of a Rare Congenital Variation, Int J Anat Var (IJAV), Vol,5, No., pp. 141–143, 2012.
- [36] Saad, KR., Saad, PF., Amorim, CA., Armstrong, D., Soares, BLF., Neves, PCF and Razuk Filho, A., Double of the Inferior Vena Cava: Case Report and a Literature Review of Anatomical Variation, J. Morphol. Sci., Vol. 29, No. 1, p. 60–64, 2012.
- [37] Ang WC, Doyle T, Stringer MD. Left-Sided and Duplicate Inferior Vena Cava: a Case Series and Review, Clin Anat, Vol. 26, No. 8, pp. 990–1001, 2013.
- [38] Itoh, M., Moriyama, H., Tokunaga, Y., Miyamoto, K., Nagata, W., Satriotomo, I., Shimada, K., and Takeuchi, Y., Embryological Consideration of Drainage of the Left Testicular Vein into the Ipsilateral Renal Vein: Analysis of Cases of a Double Inferior Venacava, Int J Androl, Vol. 24, No. 3, pp.142–152, 2001.
- [39] Castro-Iglesias, A.M., Díaz-Bermúdeza, J., Gago-Ferreiro and C., and Noya-Castrob A., Double Vena Cava Inferior, Actas Urol Esp, Vol. 34, No. 9, pp. 815–826, 2010.
- [40] Raza SS, Farid S, Reddy M, Ahmad N. Duplication of the Inferior Vena Cava. JSCR, Vol.9, No.10, pp. 1-4, 2011.
- [41] Tanka, M., Report of two cases of Double Inferior Vena Cava with an Emphasis on Embryogenesis and Clinical Relevance, Int J Anat Var (IJAV), Vol.7 No. , pp. 77–79, 2014.
- [42] Sartori, M.T., Zampieri, P., Andres, A.L., Prandoni, P., Motta, R., and Miotto, D., Double Vena Cava Filter Insertion in Congenital Double Inferior Vena Cava: a Case Report and Literature Review, Haematologica, Vol. 91 No. 1, pp. 85–86, 2006.
- [43] Xue, H.G., Yang, C.Y., Ishida, S., Ishizaka, K., Ishihara, A., and Ishida, A., Tanuma K., Duplicate Testicular Veins Accompanied by Anomalies of the Testicular Arteries, Ann Anat , Vol.187, No. 4, pp.393–398, 2005.
- [44] Tubbs, R.S., Salter, E.G., and Oakes, W.J., Unusual Drainage of The testicular veins, Clin Anat, Vol.18, No. 7, pp. 536–539, 2005.
- [45] Yang, C.Y., Xue, H.G., Tanuma, K., and Ozawa, H., Variations of the

- Bilateral Testicular Veins: Embryological and Clinical Considerations, *Surg Radiol Anat*, Vol. 30, No.1: 53–55, 2008.
- [46] Asala, S., Chaudhary, S.C., Masumbuko-Kahamba, N., and Bidmos, M., Anatomical Variations in the Human Testicular Blood Vessels, *AnnAnat* Vol. 183 No. 6, pp. 545–549, 2001.
- [47] Kakisis, J.D., Parthenis, D.G., Angeli, A.A., Karkaletsis, K.G., Troupis, T.G., Vasdekis, S.N., Double of the Inferior Vena Cava and Abdominal Aortic Aneurysm, *Vasc Med*, Vol. 9, No. 2, pp. 139–40, 2004.
- [48] Lee, F., and Quick, C.R., Abdominal Aortic Aneurysm Associated with Horseshoe Kidney and Double of Inferior vena Cava - an Extra-peritoneal Approach, *Eur J Vasc Endovasc Surg*, Vol. 14, No. 5, pp. 406–407, 1997.
- [49] Rispoli, P., Ortensio, M., Cassatella, R., Conforti, M., Moniaci, D., Varetto, G., Zan, S., and Raso, A.M., Anomalies of the Inferior Vena Cava in Patients Treated with Surgical Vascular Procedures in the Aorto Iliac Area, Report of 2 Cases and Review of the Literature, *Minerva Cardioangiol*, Vol. 49, No. 2, pp.141-146, 2001.
- [50] Nishimoto, M., Hasegawa, S., Asada, K., Furubayashi, K., and Sasaki, S., The Right Retroperitoneal Approach on Abdominal Aortic Aneurysm with an Isolated Left-sided Inferior Vena Cava. Report of a Case., *J Cardiovasc Surg (Torino)*, Vol. 43, No. 2, pp. 241–243, 2002.
- [51] Nishibe, T., Sato, M., Kondo, Y., Kaneko, K., Muto, A., Hoshino, R., Kobayashi, Y., Yamashita, M., and Ando, M., Abdominal Aortic Aneurysm with Left-sided Inferior Vena Cava, Report of a case, *Int Angiol*, Vol. 23, No. 4, pp. 400–402, 2004.
- [52] Karkos, C.D., Bruce, I.A., Thomson, G.J., and Lambert, M.E., Retroaortic Left Renal Vein and Its Implications in Abdominal Aortic Surgery, *Ann Vasc Surg*, Vol. 15, No. 6, pp. 703–708, 2001.