

REPEATED SCLEROTHERAPY SUCCESSFULLY TREATS A CHILD WITH IDIOPATHIC CHYLURIA: A CASE REPORT

Narumon Densupsoontorn¹, Anirut Pattaragarn¹ and Phichaya Sujjantararat²

¹Department of Pediatrics, ²Department of Surgery, Faculty of Medicine Siriraj Hospital, Mahidol University, Bangkok, Thailand

Abstract. We describe a clinical course of idiopathic chyluria in a previously healthy 8-year-old Thai boy, with a 1-year history of cloudy white urine undergoing antibiotic treatment. The patient was investigated for the causes but they all proved negative. Cystoscopy and retrograde pyelography demonstrated a renolymphatic fistula of the right kidney. The patient was refractory to a medium-chain triglyceride-rich diet. Ultimately, sclerotherapy with 1% povidone iodine was employed twice, which resulted in a resolution of the disorder. We emphasize that chyluria, even though a very rare condition of chylous disorders, but ultimately can be initially managed by providing a medium-chain triglyceride-rich diet and is curable by sclerotherapy. Importantly, medium-chain triglyceride-rich diet can be applied to treat other types of chylous disorders.

Keywords: child, chyluria, medium-chain triglyceride-rich diet, sclerotherapy

INTRODUCTION

Chyluria is a rare condition of chylous leakage from lymphatic vessels into urinary system through abnormal communicating tracts. Chyluria is found in 10% and 34% of patients suffering from filariasis in India and China, respectively (Cui *et al*, 1990; Tandon *et al*, 2004). Its incidence from radiofrequency ablation for treatment of renal tumors is 41% (Kaur *et al*, 2011). To the best of our knowledge, no incidence of chyluria in the general population and pediatric group has been published except for three

reported cases (Stalens *et al*, 1992; Ganesh *et al*, 2007; McNeil *et al*, 2008).

The etiology of chyluria is categorized into two groups, which are (i) parasitic cause, *viz*, lymphatic filariasis, and (ii) non-parasitic cause, *viz*, congenital anomalies of lymphatic system, trauma, lymphatic obstruction after surgery, tumor, tuberculosis, thoracic aneurysm, mesenteric adenitis, and granulomatous disease (McNeil *et al*, 2008). Patients with chyluria might present with milky urine, chylous clot, hematochyluria, dysuria, frequent urination, weight loss, urinary retention, low back pain, renal colic, edema, or protein-energy malnutrition (Nandy *et al*, 2004).

To date, in the Thai population only an elderly female with nephrotic syndrome was reported to have chylous ascites and chyluria, but evidences of lymphatic obstruction and lympho-renal fistula could not be substantiated (Lewsuwan *et al*,

Correspondence: Narumon Densupsoontorn, Department of Pediatrics, Faculty of Medicine Siriraj Hospital, Mahidol University, 2 Wang Lang Road, Bangkok Noi, Bangkok 10700, Thailand.
Tel: +66 (0) 2419 7000 ext 95947; Fax: +66 (0) 2411 3010
E-mail: narumon.den@mahidol.ac.th

2006). Herein, clinical manifestation, investigation to demonstrate lympho-renal connection, management protocol and finally cure of a previously healthy Thai boy with idiopathic chyluria are described.

CASE REPORT

An 8-year-old boy presented to a pediatric nephrologist for evaluation of passing cloudy white urine for 1 year. The patient had difficulty in voiding urine

particularly in the morning due to white clots obstructing the urethra. Although the patient had been treated for urinary tract infection with oral antibiotics three times during one year but with negative urine cultures, the symptoms still persisted. The results of urinalysis showed positive proteinuria off and on and the patient still grew well with the normal growth percentiles during the previous year. The physician was unaware of other uncommon conditions.

The consulting pediatric nephrologist noticed that by drinking large amounts of water, the patient's urine became clearer and the patient could void urine without difficulty. The patient had no history of prolonged fever, burning sensation during urination, brownish/reddish urine or unexplained edema of extremities. No history of blunt trauma at abdomen or back, elephantiasis, chronic cough, weight loss, joint pain, hair loss or skin lesions occurred. The patient had traveled to Myanmar four years ago. There was no family history of tuberculosis, chronic cough or kidney diseases. Dietary history revealed regular intake of solid food,




Fig 1–Gross appearance of cloudy white urine.

ultra-heat temperature cow's milk, fruits and snacks.

Physical examination revealed afebrile, a blood pressure of 112/72 mm Hg, weight of 25 kg (at the 50th percentile), height of 124 cm (between the 25th and 50th percentiles), a visible BCG scar, no hardening and thickening of the skin, no pitting edema or swelling of legs, no abdominal mass, normal urethral opening and scrotum, no phimosis, and no superficial lymphadenopathy.

A complete blood count showed hemoglobin level of 12.5 g/dl, a white blood cell count of 7,300/mm³ with 49.2% neutrophils, 38.9% lymphocytes, 8.3% monocytes, 3.3% eosinophils (absolute eosinophils 240 cell/mm³), and a normal platelet count. Blood chemistry revealed blood urea nitrogen level of 8 mg/dl, creatinine 0.4 mg/dl, cholesterol 158 mg/dl, and albumin 3.5 g/dl.

Urinalysis showed cloudy white color (Fig 1), specific gravity of 1.025, pH 6.0, 4+ albumin level, no presence of sugar, positive occult blood, no nitrite present, white blood cells of 3-5/high power field (HPF), red blood cells of 10-20/HPF with-

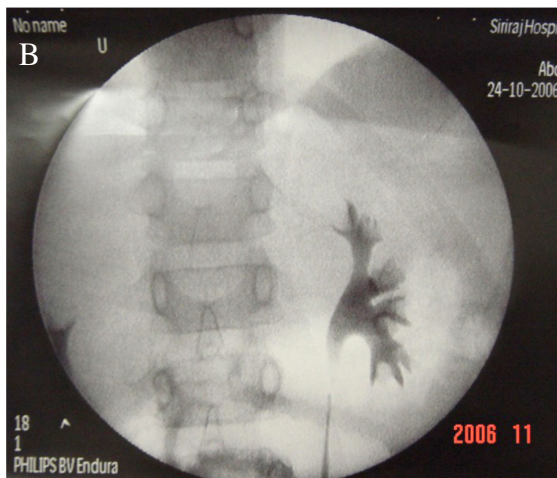
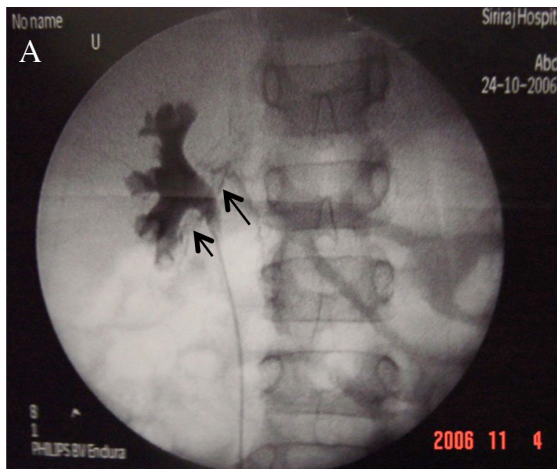


Fig 2—Cystoscopy with retrograde pyelography. A) right side showing a lymphatic fistula tract at the right lower calyx (arrows); B) left side showing normal finding.

out dysmorphic shape, and no presence of crystals. Urine triglyceride was 29 mg/dl whereas serum triglyceride was 137 mg/dl. A urine culture was negative.

Based on the patient's remarkable history and urine triglyceride level, chyluria was diagnosed. The possible causes of chyluria were filariasis, abdominal tumor, or congenital anomaly.

Microfilaria in the blood was not




Fig 3—Examples of an MCT-rich diet menu. A) steamed rice, fried boiled egg white with tamarind sauce, and vegetable soup with chicken breast; B) fried rice with egg white and chicken breast, vegetable soup with chicken breast, and papaya; C) steamed rice, fried chicken breast, stirred fried mixed vegetables, and rose apple.

found and serologic test for antifilarial IgG was negative. Stool examination for parasites and parasite eggs was negative.

Ultrasonography of the urinary system, intravenous pyelography and computer tomography of abdomen and pelvis disclosed no detectable abnormal findings. Radionuclide lymphoscintigraphy was conducted to determine site of chylous leakage by intradermal injection of Tc-99m dextran in the webs between the first and second toes of both feet, 1 mCi per point. Immediate imaging for whole body and dynamic imaging for abdomen were performed. There appeared faint accumulation of radioactivity in an area located at the left lateral and superior to the urinary bladder, which might indicate leakage of lymph at the distal part of the left ureter.

Cystoscopy demonstrated an efflux of milky urine from the right but clear urine from the left ureteric orifice. Retrograde pyelography demonstrated a lymphatic fistula tract at the right lower calyx (Fig 2A) but normal left pyelography (Fig 2B).

Subsequent to a conservative treatment with a medium-chain triglyceride (MCT)-rich diet, urine became clearer and urine triglyceride and protein were undetectable. Neither clinical symptoms nor signs of essential fatty acid deficiency and fat-soluble vitamin deficiencies were observed. At 80 days of conservative MCT-rich diet treatment, the patient's body weight and serum albumin level increased to 26.3 kg and 4.1 g/dl, respectively. At this time the physician team thought that normal diet should be restored because all clinical symptoms and laboratory results were normal without signs of essential fatty acid and fat-soluble vitamin deficiencies from the avoidance of long-chain triglyceride in the treatment diet. Conse-

quently, urine triglyceride became measurable (4 mg/dl) 6 days later. Although the MCT-rich diet was re-introduced again, the patient's urine kept being cloudy and urine analysis showed protein at 4+ level and triglyceride of 1,356 mg/dl. These resulted from the patient's poor compliance with the MCT-rich diet.

With parents' consent, sclerotherapy under retrograde pyelography using 10 ml of 1% povidone iodine solution injected through a ureteric catheter into the right renal pelvis under fluoroscopy guide was performed. The patient continued to consume the MCT-rich diet for 1 month after sclerotherapy and then was placed on a normal diet. Chyluria was not resolved completely based on the presence of urine protein at 4+ level and urine triglyceride of 43 mg/dl at day 51 after sclerotherapy. On day 84 a second sclerotherapy with 20 ml of 1% povidone iodine solution was initiated. No adverse effects were observed and the MCT-rich diet was discontinued a day after sclerotherapy.

The patient's progress was followed-up several times post-sclerotherapy. The patient was asymptomatic and urine tests showed the presence of neither protein nor triglyceride. Chyluria did not reappear at a 4-year follow-up visit.

DISCUSSION

We report a clinical progress of idiopathic chyluria in a previously healthy Thai boy. The patient was investigated for possible causes but they all came up negative. The patient was refractory to an MCT-rich diet. Finally, sclerotherapy with 1% povidone iodine solution was employed twice and resolved the symptom.

Normally, urine does not contain triglyceride and chyle is characterized by a

high content of triglyceride (in a form of chylomicrons), albumin, globulin, lymphocytes and certain electrolytes. Point-of-care test to confirm chylous effusion is conducted by adding a solvent for fat, *eg*, chloroform or ether, into the turbid white urine, which dissolves lipid substances to produce a clear urine solution (Stalens *et al*, 1992; Cheng *et al*, 2006). Two studies reported that patients with chyluria presented with nephrotic-range proteinuria in milky white urine (Cheng *et al*, 2006; Pakki Venkata *et al*, 2009).

Once chyuria is diagnosed, its cause has to be investigated. Causes of chyluria include filariasis, pyuria, tuberculosis, lipiduria, hyperoxaluria, and phosphaturia. The tropics and sub-tropics of Asia, Africa, Western Pacific, and parts of the Caribbean and South America are the geographic distribution of lymphatic filariasis, caused by *Wuchereria bancrofti*, *Brugia malayi* and *Brugia timori* infection (CDC, 2013). All investigations of our patient did not demonstrate any evidence of filariasis and hyperoxaluria. In addition the patient had no history of tuberculosis contact and symptoms or of previous abdominal operation and no presence of tumors from imaging studies.

A previous healthy history and normal findings from roentgenographic studies suggested idiopathic or congenital lympho-renal fistula. Lymphatic imaging to locate the site of communicating fistula includes contrast lymphangiography and lymphoscintigraphy (WHO, 1992). Lymphangiography is an accurate invasive test, requiring an experienced physician, and possibly complicating injury to lymphatic vessels. On the other hand, lymphoscintigraphy is a simple, physiologic, less-invasive, and less complicated test, using radionuclide technique to detect lymphatic obstruction and leakage. Ra-

diotracers used in lymphoscintigraphy are colloidal (*eg*, Tc-99m sulfur, or Tc-99m albumin) and non-colloidal tracers (*eg*, Tc-99m dextran). Injection techniques consist of intradermal and subcutaneous injections. The lymphoscintigraphic result of our patient did not correlate with findings from cystoscopy and retrograde pyelography, which could not be explained in spite of a dual uptake mechanism of Tc-99m dextran, thus indicating the need of more specific tests to identify the location of the lymphatic leakage responsible for chyluria (Yuan *et al*, 2006). Metabolic status, *eg*, weight loss, protein and lipid status in patients with chyluria should also be assessed.

Treatment modalities consist of conservative and invasive methods (Stalens *et al*, 1992; Tandon *et al*, 2004; Sharma *et al*, 2008). Conservative treatment consists of an MCT-rich diet, in which a long-chain triglyceride (LCT)-restriction diet is substituted with MCT oil, purely extracted from coconut oil. Fatty acids in most dietary triglycerides are long-chain fatty acids that are incorporated into chylomicrons and transported through the lymphatic vessels. However, medium-chain fatty acids are absorbed passively and are directly transported through the portal vein. Thus, LCT restriction results in a decreased production of chyle and, finally obliteration of lymphatic vessels.

In brief, ingredients of an MCT-rich diet consist of rice, rice noodle, egg white, chicken breast without skin, MCT oil, green leafy vegetables without seeds, carrot, non-fat milk, and fruits without seeds depending on the age of the patients. Vegetable seed oils, nuts or bean, other protein sources, and their derivatives are not allowed. Examples of an MCT-rich diet menu are steamed rice, fried rice with egg white and chicken breast, fried boiled egg

white with tamarind sauce, fried chicken breast, stirred fried mixed vegetables, vegetable soup with chicken breast, and fruits (Fig 3). An MCT-rich diet is in principle a specific dietary treatment for chylous leakage conditions, such as chylothorax and chylopericardium (Densupsoontorn *et al*, 2005, 2014), chylous ascites (Densupsoontorn *et al*, 2009), and chyluria. Compliance with the diet and clinical symptoms and signs of both essential fatty acids (EFA) and fat-soluble vitamin deficiencies should be monitored during treatment with an MCT-rich diet. Blood test for triene-to-tetraene ratio should be performed if EFA deficiency is indicated. Intravenous lipid emulsion and fat-soluble vitamins may be supplemented parenterally. If water-miscible forms of oral vitamin A, D, E, and K are available, they should be recommended. On the other hand, LCT fat-restricted diet is much less palatable than normal diet, which may cause a patient's low compliance with such special diet in the long term.

Invasive treatment includes surgery and sclerotherapy. Surgery is indicated if refractory or unresponsive to conservative treatment (Stalens *et al*, 1992; Ganesh *et al*, 2007), as severe symptoms endangering life (severe, acute and continuous chyluria resulting in cachexia) or significant weight loss can occur (Tandon *et al*, 2004). Laparoscopic or open operation is aimed to disconnect lymphorenal communication. Sclerotherapy, a less invasive method than surgery, involves injecting a drug directly into the lymphatic vessels causing irritation, scarring, and finally shrinkage (Nandy *et al*, 2004; Tandon *et al*, 2004; Ganesh *et al*, 2007). Sclerosing agents include silver nitrate, povidone iodine, sodium iodide/bromide, or 50% dextrose. Severe side effects of silver nitrate were reported including sclerosis of the collecting system, ureteral stricture, anuria, interstitial nephritis, pyo-

nephrosis, and sepsis (Nandy *et al*, 2004; Tandon *et al*, 2004). In order to avoid such serious adverse effects, povidone iodine was chosen as the sclerosant agent in the present case. There has been no intensive intervention in asymptomatic cases of congenital fistula between the lymphatic system and bladder (Stalens *et al*, 1992).

Results of the treatment modality are variable depending on severity. Nandy *et al* (2004) reported that 4/50 (8%) patients with chyluria responded to conservative treatment, 40 (80%) to a combination of 5% povidone iodine solution and 50% dextrose, and 2 (4%) to nephropexy and chylolymphatic disconnection. McNeil *et al* (2008) described a favorable outcome of primary tumor resection in a boy with metanephric adenoma-associated chyluria. Ganesh *et al* (2007) reported a success in laparoscopic lymphorenal disconnection in a 5-year old boy with symptomatic chyluria who failed to respond to conservative management. Sharma *et al* (2008) reported that 35/50 patients with chyluria respond well to a single pelvic renal instillation therapy using 5% povidone iodine solution with contrast agent, whereas 5 patients needed a second instillation. In the present case, 1% povidone iodine solution was retrogradely instilled twice at a 12-week interval with good outcome.

In summary, we report a previously healthy Thai boy with idiopathic chyluria, which was likely caused by congenital lymphorenal fistula based on the absence of an underlying disease. The patient presented with cloudy white urine and difficulty in urination due to a white proteinaceous clot obstructing the urethra. The diagnosis was delayed due to unawareness of this uncommon condition. The patient was refractory to an MCT-rich diet without any complications. Finally, sclerotherapy with 1% povidone iodine was employed

twice resulting in a favorable outcome. The interesting features of this case to general practitioners, especially pediatricians and urologists, are high suspicion of this condition, proper diagnosis and approach, and appropriate treatment modality.

REFERENCES

- Centers for Disease Control and Prevention (CDC). Lymphatic filariasis. Atlanta: CDC, 2013. [Cited 2015 Apr 7]. Available from: <http://www.cdc.gov/parasites/lymphaticfilariasis/>
- Cheng JT, Mohan S, Nasr SH, D'Agati VD. Chyluria presenting as milky urine and nephrotic-range proteinuria. *Kidney Int* 2006; 70: 1518-22.
- Cui ZH, Liu B, Lin XJ, *et al.* [Epidemiological survey on patients with advanced filariasis in Shandong Province with bancroftian filariasis basically eliminated]. *Zhongguo Ji Sheng Chong Xue Yu Ji Sheng Chong Bing Za Zhi* 1990; 8: 245-8.
- Densupsoontorn N, Jirapinyo P, Aanpreung P, Laohapensang M, Parichatikanond P. Congenital chylous ascites: the roles of fibrin glue and CD31. *Acta Paediatr* 2009; 98: 1847-9.
- Densupsoontorn N, Jirapinyo P, Tirapongporn H, *et al.* Fat-soluble vitamins and plasma and erythrocyte membrane fatty acids in chylothorax pediatric patients receiving a medium-chain triglyceride-rich diet. *J Clin Biochem Nutr* 2014; 55: 174-7.
- Densupsoontorn NS, Jirapinyo P, Wongarn R, *et al.* Management of chylothorax and chylopericardium in pediatric patients: experiences at Siriraj Hospital, Bangkok. *Asia Pac J Clin Nutr* 2005; 14: 182-7.
- Ganesh KS, Rao S, D'Cruz AJ. Successful laparoscopic management of unilateral chyluria in a 5 year old. *J Pediatr Urol* 2007; 3: 63-5.
- Kaur H, Matin SF, Javadi S, *et al.* Chyluria after radiofrequency ablation of renal tumors. *J Vasc Interv Radiol* 2011; 22: 924-7.
- Lewsuwan S, Kanjanabuch T, Avihingsanon Y, Praditpornsilpa K, Eiam-Ong S. A rare case of chylous ascites and chyluria in an adult nephrotic syndrome with focal segmental glomerulosclerosis. *J Med Assoc Thai* 2006; 89 (suppl 2): S253-6.
- McNeil JC, Corbett ST, Kuruvilla S, Jones EA. Metanephric adenoma in a five-year-old boy presenting with chyluria: case report and review of literature. *Urology* 2008; 72: 545-7.
- Nandy PR, Dwivedi US, Vyas N, Prasad M, Dutta B, Singh PB. Povidone iodine and dextrose solution combination sclerotherapy in chyluria. *Urology* 2004; 64: 1107-9.
- Pakki Venkata UR, Callum M, Neuman M, Smith RN, Trebbin W. Quiz page May 2009: Lymphaticourinary fistula causing chyluria and nephrotic-range proteinuria. *Am J Kidney Dis* 2009; 53: A33-4.
- Sharma G, Chitale V, Karva R, Sharma A, Durug AB. Fluoroscopy guided instillation therapy in chyluria using combination of povidone iodine with contrast agent. Is a single instillation sufficient? *Int Braz J Urol* 2008; 34: 270-5.
- Stalens JP, Falk M, Howmann-Giles R, Roy LP. "Milky" urine--a child with chyluria. *Eur J Pediatr* 1992; 151: 61-2.
- Tandon V, Singh H, Dwivedi US, Mahmood M, Singh PB. Filarial chyluria: long-term experience of a university hospital in India. *Int J Urol* 2004; 11: 193-8.
- World Health Organization (WHO). Lymphatic filariasis: the disease and its control: fifth report of the WHO Expert Committee on Filariasis. Geneva: WHO, 1992; 821: 14-5. [Cited 2015 Apr 7]. Available from: <http://apps.who.int/iris/handle/10665/39309>
- Yuan Z, Chen L, Luo Q, Zhu J, Lu H, Zhu R. The role of radionuclide lymphoscintigraphy in extremity lymphedema. *Ann Nucl Med* 2006; 20: 341-4.