

CASE REPORT

ORAL HISTOPLASMOSIS PRESENTING AS ORAL ULCER IN A NON-HIV PATIENT

MT Rahman¹, NHA Bakar¹, R Philip² and AR Shamsudin

¹Pathology Department, ²Department of Otorhinolaryngology, ³Department of Maxillo Facial Surgery, University Sains Malaysia, Kubang Kerian, Kota Bharu, Kelantan, Malaysia

Abstract. A 40-year-old man presented with chronic mouth ulcer for the last six months. Histopathological examination of the biopsy from the lesion confirmed a diagnosis of histoplasmosis. Although histoplasmosis commonly manifests in immunocompromized patients, like HIV, the present case was negative for HIV. Histoplasmosis is endemic in certain parts of the world and it is comparatively rare in the South Asian region, particularly Malaysia. Thirty-seven cases of histoplasmosis were reported from Malaysia (Ng and Siar, 1996), between July 1967 and October 1997. Despite the apparent rarity of the disease, clinicians and pathologists should be aware of the possibility of histoplasmosis when cases of oral ulcer are encountered.

A 40-year-old Malay male was admitted to the University Sains Hospital Malaysia on 18th August 2002 with complaints of chronic mouth ulcer for the last six months. He also complained of occasional bleeding from the mouth, halitosis, loss of weight, loss of appetite, cough, dysphagia particularly to solid food, and irregular low grade fever for the same period. Physical examination revealed him to be alert, moderately emaciated, and febrile; a nodular ulcerative lesion was seen on the upper mouth cavity involving the hard and soft palate and extending to the anterior pillar, lateral pharyngeal wall, and base of the tongue. Laboratory investigations showed mild anemia (Hb-12.1g/dl), ESR 38 mm in first hour, mild elevation of AST(62U/l)/ALT(65 U/l), x-ray chest PA-view, bilateral haziness in both lungs. Auscultation revealed bilateral crepitations. All other physical examinations were normal. CT scan of the head and neck was normal, sputum for AFB and Mantoux test were negative. Serological tests for HbsAg, HCV, AIDS were negative. Past history elicited nothing contributory, ex-

cept that he smoked 20 cigarettes per day. He is single with a history of sexual promiscuity.

An incisional biopsy was taken from the irregular ulcerative nodule in the mouth occupying the hard and soft palate and side of the tongue (Fig 1A). Two pieces of incisional biopsy, one from the left lateral border of the tongue measuring 10 mm x 5 mm x 4 mm, the other from the hard palate measuring 6 mm x 4 mm x 3 mm, were taken and sent for histopathological examination. Grossly both were irregular pieces and grayish white in color and embedded as such. Routine hematoxylin and eosin stain under light microscopy of both pieces confirmed the diagnosis of histoplasmosis. Both the biopsy tissues showed granulation tissue densely infiltrated by dense inflammatory infiltrate comprised of neutrophils, lymphocytes, plasma cells, numerous histiocytes containing fungal spores, some with budding (confirmed by PAS stain) and a few multinucleated giant cells (Fig 2).

Histoplasmosis was first described by Darling, in 1908. Infection with *Histoplasma capsulatum* is encountered in many areas of the world, but it is the most common endemic respiratory mycosis in the United States. Thirty percent of the population residing in Ohio and Mississippi valleys are skin-test positive (Werber, 1988). Reactivation in the immunocompromized

Correspondence: Dr Md Tahminur Rahman, Pathology Department, University Sains Malaysia, 16150 Kubang Kerian, Kota Bharu, Kelantan, Malaysia.
Tel: 00609 7664016 (Office); 00609 7641272 (Residence)
E-mail: tahminur@kb.usm.my

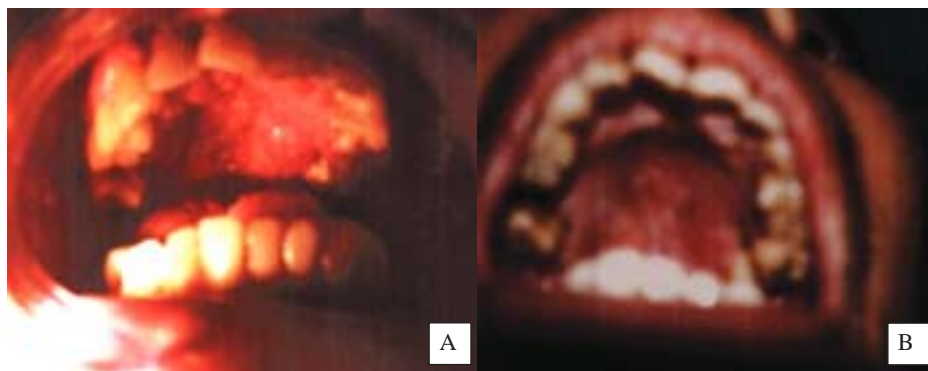


Fig 1—Gross photograph of the patient's oral ulcer before (A) and after treatment (B).

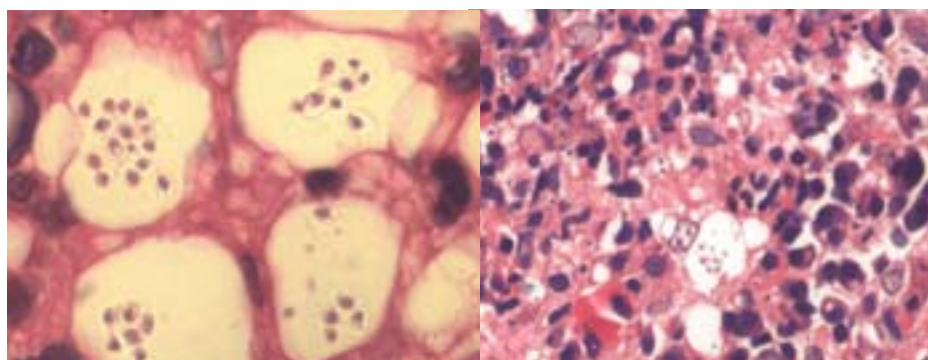


Fig 2—Microphotograph (H&E x 40) showing inflammatory infiltrate and macrophages containing the yeast form of *H. capsulatum*.

host may cause a chronic pulmonary infection or disseminated disease (Stein and Sugar, 1989). Oral lesions are present in 30%-50% of the patients with disseminated histoplasmosis (MacFarlane and Samaranayake, 1990). Our reported case has oral lesion and bilateral lung crepitation and haziness. Histoplasmosis is common in immunocompromized patients, such as HIV patients, and oral histoplasmosis may be the primary diagnostic manifestation of underlying HIV infection. However, in our case the patient was seronegative for HIV, HCV, and HBsAg.

Oral lesions along with constitutional symptoms like dysphagia, loss of weight, loss of appetite, irregular low grade fever, often mimic a clinical diagnosis of squamous cell carcinoma or granuloma (Swindells *et al*, 1994). The presented case also had these symptoms and was clinically suspected to have a malignancy with ulceration. Most oral ulcers underlie associated diseases, such as fungal infections like histoplasmosis and candidiasis, granulomatous inflammation, squamous cell

carcinoma or immunocompromized conditions like HIV (Weber, 1988; Nittayananta *et al*, 1997; Economopoulou *et al*, 1998). Here lies the importance of histopathological, serological and microbiological examination to exclude those conditions. Histoplasmosis can also present as hyperplastic gingival lesion (Loh *et al*, 1989) and as a lesion in the pharynx and larynx (Gerber *et al*, 1995).

As usual, the patient responded well to antifungal therapy started after diagnosis, and improved dramatically (Fig 1B). Patients presenting with oral ulcer should be meticulously examined clinically and physically, and laboratory investigations should be done to exclude histoplasmosis. Patients should be screened for immunocompromized disorders, particularly HIV, whether it is positive or negative, and appropriate therapy should be started.

REFERENCES

Darling ST. Histoplasmosis: a fatal infectious disease

- resembling Kala-Azar found among natives of tropical America. *Arch Intern Med* 1908; 2: 107-23, cited by Werber JL. Histoplasmosis of the head and neck. *Ear Nose Throat J* 1988; 67: 841-45.
- Economopoulou P, Laskaris G, Kittas C. Oral histoplasmosis as an indicator of HIV infection. *Oral Surg Oral Med Oral Pathol* 1998; 86: 203-6.
- Gerber ME, Rosdeutscher JD, Seiden AM, Tami TA. Histoplasmosis: the otolaryngologist's perspective. *Laryngoscope* 1995; 105 (9 pt 1): 919-23.
- Loh FC, Yeo JF, Tan WC, Kumarasinghe G. Histoplasmosis presenting as hyperplastic gingival lesion. *J Oral Pathol Med* 1989; 18: 533-6.
- MacFarlane TW, Samaranyake LP. Systemic infections. In: Johns JH, Mason DK, eds. *Oral manifestations of systemic disease*. 2nd ed. London: Balliere Tindall, 1990: 339-86.
- Ng KH and Siar CH. Review of oral histoplasmosis in Malaysians. *Oral Surg Oral Med Oral Pathol Radic Endod* 1996; 81: 303-7.
- Nittayananta W, Kumplanont P, Srisintorn S, et al. Oral histoplasmosis associated with candidiasis in HIV infected patients: a report of two cases. *Br Den J* 1997; 182: 309-12.
- Stein DK, Sugar AM. Fungal infections in the immunocompromised host. *Diagn Microbiol Infect Dis* 1989; 12 (suppl): 221S-228S.
- Swindells S, Durham T, Johansson SL, Kaufman L. Oral histoplasmosis in a patient infected with HIV. *Oral Surg Oral Med Oral Path* 1994; 77: 126-30.
- Werber JL. Histoplasmosis of the head and neck. *Ear Nose Throat J* 1988; 67: 841-5.