

# การเก็บเอ็นเซมิเท็นดิโนซัสและเจาะท่อเพื่อร้อยเอ็นในการสร้างซ่อมเอ็นไขว้หน้าผ่านกล้องส่องข้อด้วยแผลเดียว

ปกรณ์ นาระคอล<sup>1\*</sup>, วินัย ศิริชาติวาปี<sup>2</sup>, โกวิท ไชยศิวิมมงคล<sup>3</sup>

<sup>1</sup>กลุ่มงานศัลยกรรมออร์โธปิดิกส์ โรงพยาบาลขอนแก่น

<sup>2</sup>ภาควิชาออร์โธปิดิกส์ คณะแพทยศาสตร์ มหาวิทยาลัยขอนแก่น

<sup>3</sup>ภาควิชากายวิภาค คณะแพทยศาสตร์ มหาวิทยาลัยขอนแก่น

## The One-Incision Technique for Harvesting Semitendinosus Tendon and Graft Tunneling in Arthroscopic Assisted Anterior Cruciate Ligament Reconstruction

Pakorn Narakol<sup>1\*</sup>, Winai Sirichatvapee<sup>2</sup>, Kowit Chaisiwamongkol<sup>3</sup>

<sup>1</sup>Orthopaedics surgeon, Department of Orthopedics, Khon Kaen Hospital

**หลักการและวัตถุประสงค์ :** การผ่าตัดซ่อมเอ็นไขว้หน้าโดยใช้เอ็นแฮมมัสตริง โดยเฉพาะอย่างยิ่งเซมิเท็นดิโนซัสได้รับความนิยมอย่างแพร่หลาย แต่ความท้าทายคือการค้นหาเอ็นที่ต้องการให้ถูกต้อง และการเจาะท่อร้อยเอ็นแทนเอ็นไขว้หน้า การศึกษานี้มีวัตถุประสงค์เพื่อพัฒนาวิธีเก็บเอ็นเซมิเท็นดิโนซัส และสร้างท่อร้อยเอ็นผ่านแผลผ่าตัดเดียวกัน

**วิธีการศึกษา :** การศึกษา มี 3 ระยะ ดังนี้

**ระยะที่ 1 :** ศึกษาลักษณะของเอ็นเซมิเท็นดิโนซัส จากร่างที่เตรียมสำหรับนักศึกษาแพทย์ จำนวน 62 ร่าง

**ระยะที่ 2 :** ศึกษาในร่างสดที่เตรียมสำหรับนักศึกษาแพทย์ และแพทย์ประจำบ้านออร์โธปิดิกส์ จำนวน 32 ร่าง เพื่อทดสอบเทคนิคการผ่าตัดแบบใหม่

**ระยะที่ 3 :** ศึกษาในผู้ป่วยโรงพยาบาลขอนแก่นที่ได้รับการผ่าตัดซ่อมเอ็นไขว้หน้าผ่านกล้องโดยใช้เอ็นเซมิเท็นดิโนซัส จำนวน 32 ราย

**ผลการศึกษา :** จากการศึกษา พบว่าจุดที่เส้นเอ็นเซมิเท็นดิโนซัสสังเกตเห็นได้ชัดเจน คือตำแหน่ง 1 กระบี่ข้อมนิ้ว (2 ซม.) ต่ำกว่าปุ่มกระดูกหน้าแข้ง กับ 1/4 ความกว้างของกระดูกหน้าแข้งระดับนี้วัดจากสันแข้งด้านใน จากการศึกษาในร่างสดพบว่าสามารถเก็บเส้นเอ็นผ่านแผลขนาด 2.5-3 ซม. และเมื่อผ่าตัดจริงพบว่าทุกรายสามารถเก็บเส้นเอ็นดังกล่าว และสามารถเจาะท่อร้อยเอ็นแทนเอ็นไขว้หน้าผ่านแผลเดียวกันทั้ง 32 ราย พบอาการขาหน้าแข้งหลังผ่าตัดในผู้ป่วย 10 ราย แต่ทั้ง 32 รายต่างก็พอใจในแผลผ่าตัด และหลัง 1 เดือนทุกรายไม่เจ็บที่แผลผ่าตัด

**Background and objective :** The use of autogenous hamstring tendon especially the semitendinosus has been widely spread for anterior cruciate ligament (ACL) reconstruction. Anterior approach can be challenging due to difficult tendon identification and when the harvesting wound intended to be share for graft tunneling. This studied aim to find out the technique harvesting semitendinosus tendon and making graft tunnel through the same incision.

**Methods:** The study was performed in 3 phases as follows.

**Phase 1 :** Sixty two dry cadavers were studied for their characteristics of the semitendinosus tendon, after the medical student classes.

**Phase 2 :** Thirty six fresh cadaveric specimen from orthopedic students and residents workshop were dissected to postulate the new technique.

**Phase 3 :** Thirty two cases of arthroscopic assisted ACL reconstruction using single bundle quadrupled semitendinosus tendon graft were performed in Khon Kaen Hospital.

**Result :** Cadaveric studied revealed that the semitendinosus tendon was located at 1 finger breadth (2 cm.) below the tibial tuberosity and 1/4 inner most the width of the medial metaphysis at this level. In all fresh cadaveric dissection, we could harvest the tendon graft via a 2.5-3 cm. incisional wound. And the tibial tunneling was successfully placed through the same incision in all 32

\*Corresponding author: Pakorn Narakol Orthopaedics surgeon, Department of Orthopedics, Khon Kaen Hospital

E-mail : pnarakol@gmail.com

**คำสำคัญ :** เอ็นเซมิเท็นดิโนซัส; จุดสังเกต; ท่อกระดูก; การสร้างเอ็นไขว้หน้า

operated cases. After surgery we found 10 cases complained numbness at the medial aspect of their shins. However, all 32 cases were appreciate in their surgical scars, and reported no pain at the harvesting wound 1 month after surgery.

**Conclusion :** An alternative landmark i.e., 1 finger breadth below the tibial tuberosity and ๙ the width of the medial metaphysic at this level lateral to the medial tibial crest is useful in semitendinosus tendon harvesting and graft tunneling using in the same incision in arthroscopic assisted ACL reconstruction.

**Keyword:** Semitendinosus tendon; landmark; autogenous graft; tunneling; ACL reconstruction

ศรีนครินทร์เวชสาร 2557; 29 (6): 530-534. ♦ Srinagarind Med J 2014; 29 (6): 530-534.

## Introduction

Anterior Cruciate ligament (ACL) reconstruction surgery aims primarily to restore knee joint stability<sup>1</sup> so that patient can return to sports and activity in daily living with a low risk for graft ruptures and graft-related morbidity. Previous studies of the biomechanical properties found that patellar tendon bone graft gain stiffer and stronger. However the hamstring tendons are increasingly popular graft choice for anterior cruciate ligament reconstruction due to preservation of quadriceps function and the absence of anterior knee pain post-operatively.

The use of autogenous hamstring tendon especially semitendinosus tendon has been wide spread many years. Hamstring autograft harvest through an anterior approach can be challenging when identification of the tendon is difficult<sup>2,3</sup> or if premature graft amputation occurs<sup>4</sup>. And also the harvesting wound is different to the tunneling wound<sup>5</sup>. This study therefore aimed to find the simple method for harvesting semitendinosus tendon precisely and also perform ACL reconstruction surgery through the same incision.

## Methods

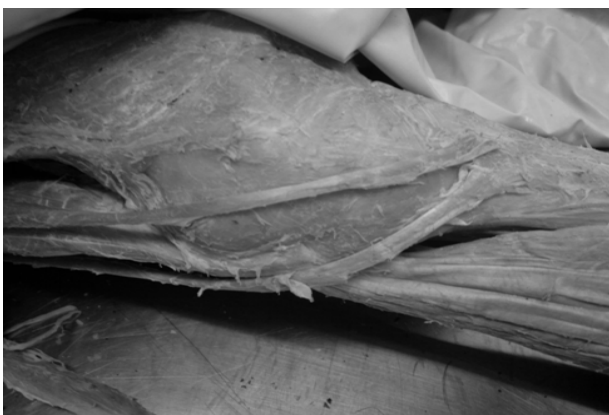The Human Ethics committee of Khon Kaen Hospital approved this study (39/2548). Patients were informed of the nature of the experiment and gave written consent before operation in phase 3 of this study.

**Phase 1 :** During March 2010 – March 2011, 62 dry cadavers that had prepared for medical students of faculty of medicine were studied to identify semitendinosus tendon and anatomic correlation. The 30 male and 32 female cadavers were dissected the footprint and correlation of pes anserinus insertion (Sartorius, Gracilis and Semitendinosus tendon) (Fig.1) and the land mark of harvesting point was identified in simple way for surgical applicable. The saphenous nerve was also identified.

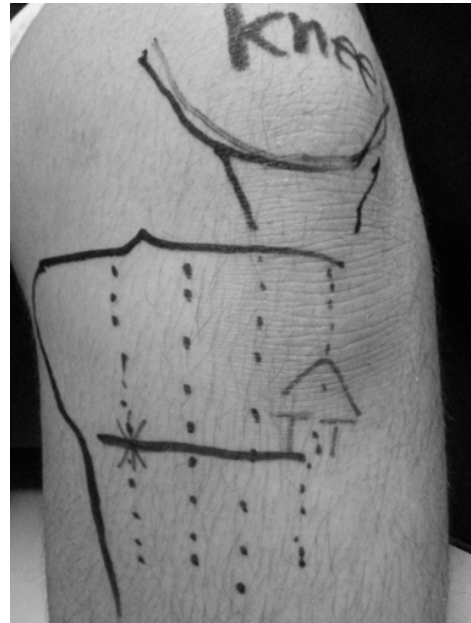
**Phase 2:** During March 2011 – March 2012, 36 fresh cadaveric that prepared for Orthopedic students and Orthopedic residents of faculty of Medicine were dissected in postulate the new technique as the landmark 1 finger breadth below the tibial tuberosity and the width of the medial metaphysic at this level lateral to the medial tibial crest. (Fig.2)

**Phase 3:** During March 2012 – November 2013, 32 cases in Khon Kaen Hospital that arthroscopic assisted anterior cruciate ligament reconstruction with single bundle quadrupled semitendinosus tendon were performed in the same landmark that proof in fresh cadaveric study. The minimally invasive semitendinosus tendon harvesting is performed with the patient in the supine position. Hip and knee flexion position can be adjusted to improve the ability to palpate the tendons medial across popliteal fossa (Fig.3). A 2.5 – 3 cm. longitudinal incision at 1 finger breadth below the tibial tuberosity and  $\approx$  the width of the medial metaphysic at this level lateral to the medial tibial crest were performed. Sharp incision was carried out through skin, and the popliteal fascia was penetrated bluntly and spread. The semitendinosus tendon usually the most lateral tendon. Distal palpation of semitendinosus tendon confirms its attachment to the tibia at the pes anserinus.

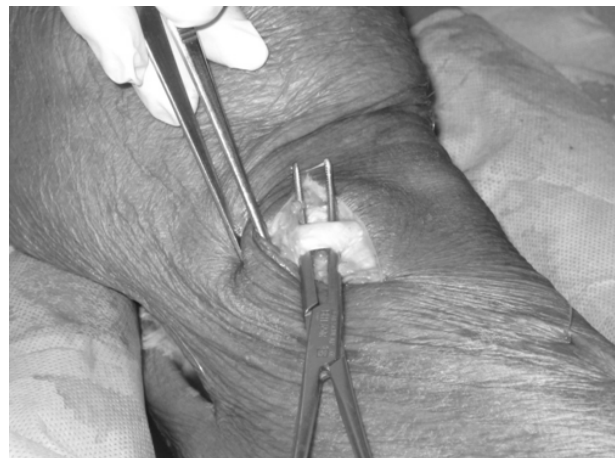The semitendinosus tendon was identified and delivered into the wound. A right-angle clamp was placed around the tendon, and a loop used to tag the tendon. Peritendinous soft tissue was resected to cleanly expose the tendon. Blunt dissection and sharp dissection proximally and distally were performed until there are no adhesions. The surgeon finger can fully circle the tendon. Once the tendon was free of any soft tissue attachment, an opened-ended tendon stripper is carefully progressive proximally advancement. Critically, the harvester must be directed precisely in line with the tendon, toward ischial tuberosity, the proximal attachment



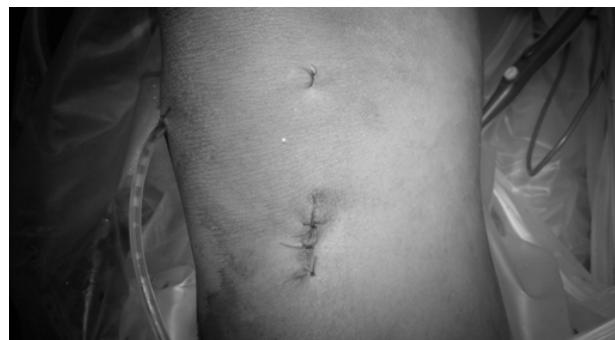**Figure 1** Pes anserinus insertion(Sartorius, Gracilis and



**Figure 2** Landmark for incision : 1 finger breadth below the tibial tuberosity and  $\approx$  the width of the medial metaphysic at this level lateral to the medial tibial crest



**Figure 3** Semitendinosus tendon harvesting



**Figure 4** Surgical wound after surgery

of semitendinosus. To release the distal aspect of the tendon, the proximal stump is retrieved with a tendon stripper. As well as serving as a stripper, the closed harvester had a sharp tip as periosteal elevator. The harvester was advanced distally toward tendon insertion on the pes anserinus that tendon was release from the tibial cortex. After that the tibial tunneling was performed through the same incision in conventional arthroscopic assisted ACL reconstruction trans-tibial technique.

### Results

Sixty-two cadaveric study revealed that all semitendinosus tendon rest at the lateral most tendon and anatomic correlation of semitendinosus tendon can be describe easily as 1 finger breadth below the tibial tuberosity and 1/4 the width of the medial metaphysic at this level lateral to the medial tibial crest that all semitendinosus tendon could be found at this landmark.

Thirty-six fresh cadaveric knees dissecting for the new technique at the same landmark 1 finger breadth below the tibial tuberosity and ¼ the width of the medial metaphysic at this level lateral to the medial tibial crest. After sharp incision was carried out through skin, and

the popliteal fascia was penetrated bluntly and spread, the semitendinosus tendon was easily harvested through this approach. But for complete tendon harvesting, the incision should be extended distally 0.5 – 1 cm. In observation this approach was the same as tibial tunneling of ACL reconstruction. All 36 fresh cadaveric dissections we can harvest via that incision 2.5 -3 cm successfully.

Thirty-two cases arthroscopic assisted anterior cruciate ligament reconstruction with single bundle quadrupled semitendinosus tendon were performed by one doctor. Demographic data of the patients were presented in Table 1. All 32 cases were performed ACL reconstruction with quadrupled semitendinosus tendon. And also performed harvesting and tunneling through the same incision as the new technique that had described above. We could harvest semitendinosus tendon without premature graft harvest and necessary procedures were performed successfully. Arthroscopic assisted anterior cruciate ligament reconstruction were success all 32 cases. Meniscal repairs were done for 8 cases. And also had partial meniscectomy in the same period for 9 cases. Semitendinosus grafts diameter were 8.7±2 mm. Operative time for harvesting were 12±3 min. And operative time were 72±14 min. that shown as Table 2. After surgery we found that 10 cases complain numbness at medial aspect of their shin. But all 32 cases appreciate for their surgical scar (Fig.4). All 32 cases have no pain at harvesting wound after 1 month. No wound dehiscence or others wound complication on 2 months follow up.

**Table 1** Patient's characteristics, n=32

Male (%)	26 (81.25)
Height (cm.)	173 ±5*
Weight (kg.)	72 ±12*
Age of injury (yr.)	26 ±6*
Sport injury (%)	24 (75)
Right side affected (%)	16 (50)

\* mean with standarad deviation

**Table 2** Operation results, n=32

Operation :	
ACL reconstruction (%)	15 (46.87)
ACLR and meniscal repair (%)	8 (25)
ACLR and meniscectomy (%)	9 (28.12)
Time for semitendinosus graft harvesting(min.)	12±3*
Total operating time(min.)	72±14*
Success of operation (%)	32 (100)

\* mean with standarad deviation

### Discussion

The study showed that the semitendinosus tendon harvesting in new technique could bring the graft successfully all cases for ACL reconstruction without graft morbidity as premature harvesting that compared to another literatures about 7-15 %<sup>1-3</sup>. Although 10 out of 32 cases (31.25%) had numbness at medial aspect of shin that was common complication in semitendinosus graft harvesting. Numbness after graft harvesting especially in minimally invasive technique had incidence 20 - 40 %<sup>3,8</sup> from saphenous nerve injury. This study

show that arthroscopic assisted anterior cruciate ligament reconstruction, transtibial technique and semitendinosus graft can harvest in the same incision. The landmark 1 finger breadth below the tibial tuberosity and the width of the medial metaphysis at this level lateral to the medial tibial crest is useful to identify semitendinosus tendon and tunneling for ACL reconstruction. Therefore many of surgeons still use different technique for harvesting graft and tunneling.<sup>6,7</sup>

Limitations of this technique may cause saphenous nerve injuries because the incision quite small. But the exposure is enough for semitendinosus graft harvesting. Graft amputation or pre-mature harvesting always concern for surgeons. Tendon strippers must apply gently and carefully to the tendon direction appropriate to mitigate against this. Iatrogenic saphenous nerve injury is a risk and has been previously described in the literature<sup>8</sup> 20 – 40 % of cases. Careful superficially dissection to identify saphenous nerve and appropriate protection during deep dissection would minimize risk<sup>9</sup>.

In conclusion, Alternative landmark 1 finger breadth below the tibial tuberosity and 1/4 the width of the medial metaphysis at this level lateral to the medial tibial crest is a good incision landmark for harvesting semitendinosus tendon and tunneling for anterior cruciate ligament reconstruction in the same incision.

## References

1. Kodkani PS, Govekar DP, Patankar HS. A new technique of graft harvest for anterior cruciate ligament reconstruction with quadruple semitendinosus tendon autograft. *Arthroscopy* 2004;20:e101-4.
2. Prodomos CC, Han YS, Keller BL, Bolyard RJ. Posterior mini-incision technique for hamstring anterior cruciate ligament reconstruction graft harvest. *Arthroscopy* 2005;21:130-7.
3. Biau DJ, Katsahian S, Kartus J, Harilainen A, Feller JA, Sajovic M, et al. Patellar tendon versus hamstring tendon autografts for reconstruction of the anterior cruciate ligament: A meta-analysis based on individual patient data. *Am J Sports Med* 2009;37:2470-8.
4. William RJ III, Heyman J, Petrigliano F, Rozental T, Wickiewicz TL. Anterior cruciate ligament reconstruction with a four-strand hamstring tendon autograft. Surgical technique. *J Bone Joint Surg Am* 2005;87 (suppl 1, pt 1):51-66 (published erratum appears in *J Bone Joint Surg Am* 2007;89:1826).
5. Taylor DC, DeBerardino TM, Nelson BJ, Duffey M, Tenuta J, Stoneman PD, et al. Patellar tendon versus hamstring tendon autografts for anterior cruciate ligament reconstruction: a randomized controlled trial using similar femoral and tibial fixation methods. *Am J Sports Med* 2009;37:1946-57.
6. Sun K, Zhang J, Wang Y, Xia C, Zhang C, Yu T, et al. Arthroscopic anterior cruciate ligament reconstruction with at least 2.5 years' follow-up comparing hamstring tendon autograft and irradiated allograft. *Arthroscopy* 2011;27: 1195-202.
7. Pallis M, Svodoba SJ, Cameron KL, Owens BD. Survival comparison of allograft and autograft anterior cruciate ligament reconstruction at the United States Military Academy. *Am J Sports Med* 2012;40:1242-6.
8. Shelton WR, Fegan BC. Autografts commonly used in anterior cruciate ligament reconstruction. *J Am Acad Orthop Surg* 2011;19:259-64.
9. Sanders B, Rolf R, McClelland W, Xerogeaners J. Prevalence of saphenous nerve injury after autogenous hamstring harvest: An anatomical and clinical study of sartorial branch injury. *Arthroscopy* 2007;23:956-63.



