

อุบัติการณ์กล้ามเนื้อ sternalis ในคนไทยภาคตะวันออกเฉียงเหนือ

วรรณิ ชัยจรูญคุณารักษ์, ปัทมา อมาตยคง, วันสนันท์ แป้นนางรอง, จริยา อัมคา, มะลิวัลย์ นามกิง,
โกวิท ไชยสีวามงคล, ฮิซาทาเกะ คอนโดะ, ปาริฉัตร ประจะเนย์*
ภาควิชากายวิภาคศาสตร์ คณะแพทยศาสตร์ มหาวิทยาลัยขอนแก่น 40002

Incidence of the sternalis muscle in Northeastern Thais

Wunnee Chaijaroonkhanarak, Pattama Amartayakong, Wanassanun Pannangrong, Jariya Umka,
Malivalaya Namking, Kowit Chaisiwamongkol, Hisatake Kondo, Parichat Prachaney*
Department of Anatomy, Faculty of Medicine, Khon Kaen University, Khon Kaen, 40002, Thailand

หลักการและวัตถุประสงค์: กล้ามเนื้อ sternalis มีลักษณะเป็นแถบแบนเล็ก ๆ พบบริเวณด้านหน้าของผนังทรวงอก ซึ่งอาจทำให้เข้าใจผิดว่าเป็นก้อนเนื้ออกที่บริเวณเต้านม ได้มีการศึกษาถึงรูปแบบต่าง ๆ ของกล้ามเนื้อชนิดนี้ในคนต่างเชื้อชาติ รวมทั้งคนไทยในภูมิภาคอื่น แต่ยังไม่พบรายงานเกี่ยวกับกล้ามเนื้อ sternalis ในคนไทยทางภาคตะวันออกเฉียงเหนือ การศึกษานี้จึงมีวัตถุประสงค์เพื่อสำรวจหาอุบัติการณ์ของกล้ามเนื้อ sternalis และความผันแปรของรูปแบบของกล้ามเนื้อนี้ในคนไทยภาคตะวันออกเฉียงเหนือ

วิธีการศึกษา: เป็นการศึกษาเชิงพรรณนาจากการชำแหละศพของคนไทยที่ใช้ในการเรียนวิชามหาวิทยาลัยวิทยาศาสตร์ ห้องปฏิบัติการมหาลัยวิทยาศาสตร์ คณะแพทยศาสตร์ มหาวิทยาลัยขอนแก่น จำนวน 117 ร่าง จากผู้บริจาคร่างกายที่มีภูมิลำเนาในภาคตะวันออกเฉียงเหนือ เพศชาย 70 ร่าง และเพศหญิง 47 ร่าง อายุเมื่อถึงแก่กรรมอยู่ระหว่าง 19-97 ปี โดยชำแหละหากกล้ามเนื้อ sternalis ศึกษารูปร่างลักษณะและการวางตัวของกล้ามเนื้อ พร้อมทั้งศึกษาเส้นประสาทที่มาเลี้ยง

ผลการศึกษา: พบกล้ามเนื้อ sternalis ทั้งสิ้นจำนวน 10 ราย จาก 117 ร่าง คิดเป็นร้อยละ 8.5 (เพศชาย 9 ราย และหญิง 1 ราย) พบกล้ามเนื้อ sternalis ทางด้านขวาของผนังทรวงอกด้านเดียวจำนวน 9 ราย และพบทั้งสองข้างเพียง 1 ราย ในเพศชาย กล้ามเนื้อดังกล่าวมีลักษณะเป็นแถบแบน มีการวางตัวแบบขนานกับกระดูกอก หรือทอดตัวขึ้นบนเบนเข้าหา

Background and Objective: The sternalis muscle is a small supernumerary muscle of the pectoral region. It may make misdiagnosis as a breast mass or tumor in the mammograph. Previous studies reported different types of sternalis muscles. There has not been reported of the sternalis muscle in Northeastern Thais.

Methods: This is a descriptive study based on anatomical dissection in embalmed cadavers using in gross anatomy subject at Gross Anatomy Laboratory Dissecting room of the Department of Anatomy, Faculty of Medicine, Khon Kaen University. One hundred seventeen donated, embalmed Northeastern Thai cadavers (70 males; 47 females) ranging between 19-97 years of age at decease were used. The pectoral region of each cadaver was carefully dissected and examined for the sternalis muscle. The shape, location and nerves supply were investigated and recorded.

Results: Sternalis muscles presented in 10 cases (8.5%) of 117 cadavers (9 males and 1 female). The right unilateral sternalis was observed in 9 specimens. Bilateral sternalis was detected in only 1 male cadaver. Each muscle was strap-like and located either parallel or upward medially to the sternum. All muscles were supplied by the 2nd - 4th intercostal nerves.

Conclusions: The incidence of sternalis muscle in Northeastern Thais was 8.5 %. Most of these (90%) were

*Corresponding Author: Parichat Prachaney, Department of Anatomy, Faculty of Medicine, Khon Kaen University, Khon Kaen, 40002, Thailand Tel: 63173, 043-348381, 086-8561124 E-mail: prapra@kku.ac.th

กระดูกอก และได้รับแขนงประสาทมาเลี้ยงจาก เส้นประสาท intercostal ที่ 2-4

สรุป: คนไทยในภาคตะวันออกเฉียงเหนือมีอุบัติการณ์ของกล้ามเนื้อ sternalis คิดเป็นร้อยละ 8.5 ส่วนมาก (ร้อยละ 90) พบกล้ามเนื้อ sternalis อยู่ทางด้านขวา และมักพบในผู้ชายมากกว่าผู้หญิง

right unilateral sternalis and were found more often in male than in female.

Keywords: Anatomical variant, Northeastern Thais, sternalis muscle, sternum

ศรีนครินทร์เวชสาร 2556; 28(1): 62-5 • Srinagarind Med J 2013; 28(1): 62-5

Introduction

Sternalis muscle is a thin strap-like muscle located in the anterior chest wall. It is a rare muscle, therefore it is insufficiently mentioned in most Anatomical textbook. However, its shadow may be visible as an irregular structure medially on the craniocaudal projection and can give rise to diagnostic confusion with breast cancer during routine mammography¹. In addition, the muscle itself may interfere the surgeon during performing operative procedure at the anterior thoracic wall. Considering the recent trend of increasing cases of mammography examination and more reliable diagnosis, it is interesting to study the sternalis muscle in Thailand. Although the sternalis muscle has been studied in different race, there are only two reports concerning the incidence of sternalis muscle in Thais who lived in lower part of the Southern region² and in Bangkok³. However, there is no report of this muscle in Northeastern Thais. Therefore, the aim of the present study is to investigate the incidence of the Thais' sternalis in this region.

Methods

One hundred and seventeen embalmed Northeastern Thai cadavers were included. They were 47 females and 70 males, age ranging from 19 to 97 years at the time of deceased. All of them had donated their bodies to the Department of Anatomy, Faculty of Medicine, Khon Kaen University. The anterior chest

walls of these cadavers were exposed during routine dissection in Gross Anatomy courses for undergraduate, medical and physiotherapy students. The sternalis muscle at the pectoral region and its nerves supply were carefully identified, photographed and recorded. This study was approved by Human Ethics Committee of Khon Kaen University (reference No. HE551118).

Results

The sternalis muscles were detected in 10 (8.5%) of 117 Northeastern Thai cadavers. The muscles were found in 9 (7.7%) male specimens whereas only 1 (0.8%) sample was detected in female.

All muscles were strap-like and located in the subcutaneous plane of the pectoral region. They were run either parallel (Fig 1A) or upward medially (Fig 1B-D) to the sternum. The right unilateral sternalis was observed in 9 (8 males and 1 female) specimens (Fig 1A-C). One male cadaver exhibited well developed bilateral sternalis (Fig 1D). Most sternalis muscles consisted of a mixture of original fleshy fibers and inserted tendinous band (Fig 1A, B). Some of those were well-defined fleshy fibers (Fig 1C, D).

The sternalis muscles were innervated by branches of the 2nd- 4th intercostal nerves which penetrated the deep surface of the muscle without any involvement of the pectoral nerves. Pectoralis major and minor muscles were normally placed.

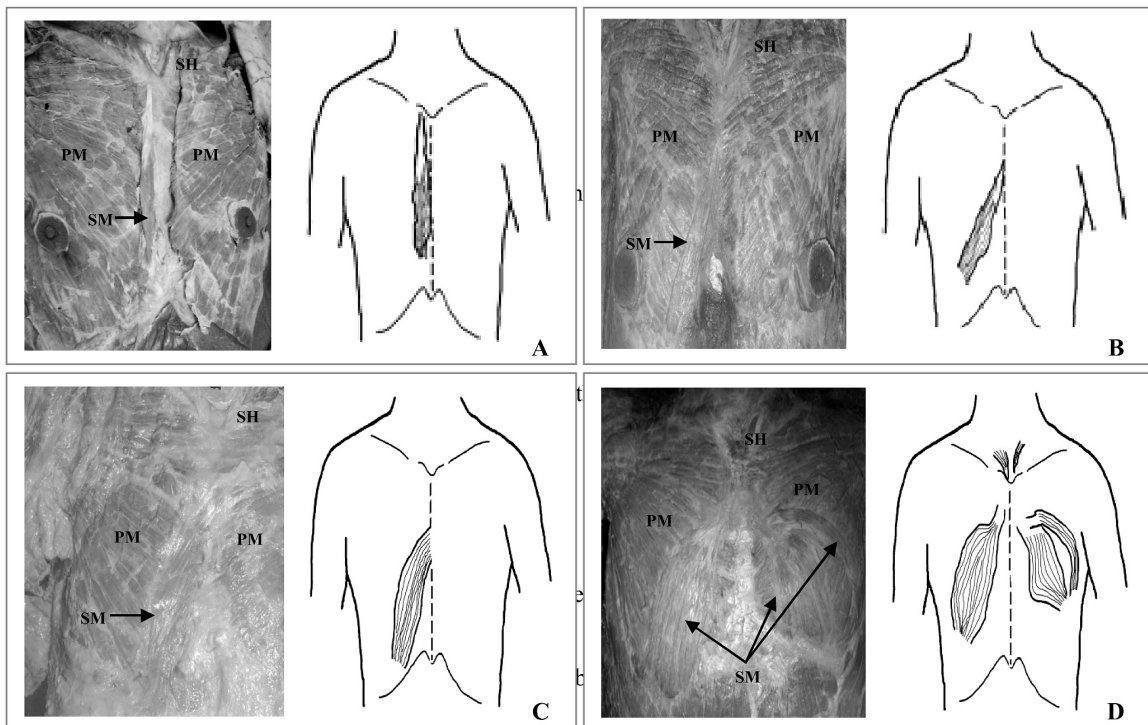


Figure 1 Photographs and schematic drawings of the unilateral (A-C) and bilateral types (D) of sternalis muscles, anterior view.

A: The muscle runs parallel to the sternum. **B:** The muscle composed of fleshy fibers and inserted tendinous end or **C:** Well-defined fleshy fibers. Both muscles in figures B and C run upward medially. **D:** Well-developed fleshy fibers of bilateral sternalis. The left sternalis bifurcated into two parts, a small gap is also observed (*SM*, sternalis muscle; *SH*, sternal head of left sternocleidomastoid muscle; *PM*, pectoralis major muscle).

Discussion

The sternalis is a rare normal anatomic variation of rudimentary muscle of the anterior thoracic wall in human. Many previous studies have been published as case report⁴⁻⁸. This is the report of first noticed of sternalis muscle in Northeastern Thais. The frequency rate is 8.5% which is higher in male than in female. Most of the sternalis muscles (9 out of 10 cases) were right unilateral type. Bilateral type was rare. The incidence of the sternalis muscle has been varied wildly among different population. The highest incidence rate is found in North Chinese⁹, ranging from 11.1% - 23.5%. It was presented in 6.2% of Korean people¹⁰ whereas in Kingdom of Saudi Arabia (KSA) it incidence was 4%⁹. The rare observation was only 1.2% in the Taiwanese^{11,12}

as well as in people who live in Southern part of Thailand². While in the middle part of Thailand, the incidence rate of sternalis muscle was 7.1%³. The sternalis muscle which was studied in three different regions of Thailand, the highest incidence rate (8.5%) being observed in people who lived in Northeastern part. In addition, the frequency rate was also higher than other previous reports in Asian race such as Korean and KSA including Taiwanese people. However, the sternalis was detected in 8% of the American whites Negroes¹³ which is very close incidence rate compare to the present study. Several studies have been reported that the sternalis muscle originates from neighboring muscles such as sternocleidomastoid muscle^{14, 15}, pectoralis major muscle¹⁶ or rectus abdominis muscle¹⁴.

The pectoralis origin of the sternalis muscle has been reported as a replacement of some missing part of the pectoralis muscle. In this study, the pectoralis muscle was intact and the sternalis muscles were covered by superficial fascia of the anterior thoracic region.

The nerve innervation of the sternalis is still under debate. They may supply by branches from the intercostal nerve, the anterior thoracic nerve¹⁷⁻¹⁹, or the pectoral nerve^{20,21}. The nerve innervation of the sternalis was claimed to be related to the possible origin of the muscle^{15, 20}. In the present study all sternalis muscles were supplied by the 2nd - 4th intercostal nerves.

The present of this small muscle usually does not cause any serious functional disturbance. Although this muscle seem to have weak clinical significance²², it might have benefit to the radiologists and the surgeons to be aware of the diagnostic confusion with the breast tumor. In addition, it may require for the thoracic surgeon to know about this variation in order to avoid of an unnecessary exploratory surgery in the anterior thoracic region.

References

- Bradley FM, Hoover HC Jr, Hulka CA, Whitman GJ, McCarthy KA, Hall DA, et al. The sternalis muscle: an unusual normal finding seen on mammography. *AJR Am J Roentgenol* 1996; 66:33-6.
- Kirirat P, Thaweethamsewee P, Subhadhirasakul P, Puriwathanakul K, Tanomkiat W. The sternalis muscle in the Thai population. *Songkalo Med J* 2005; 23:255-9.
- Plakornkul V, Viravud Y. Sternalis muscle: anatomical variations in Thais. *Siriraj Med J* 2012;64 (suppl1): s19-s21.
- Khan UD. Use of the rectus sternalis in augmentation mammoplasty: case report and literature search. *Aesth Plast Surg* 2008; 32:21-4.
- Sarikcioglu L, Demire BM, Oguz N, Ucar Y. Three sternalis muscles associated with abnormal attachments of the pectoralis major muscle. *Anatomy* 2008; 2:67-71.
- Zaher WA, Darwish HH, Abdalla AME, Vohra MS, Khan MM. Sternalis: A clinically important variation. *Pak J Med Sci* 2009; 25:325-8.
- Bhat KMR, Potu BK, Gowda S. Sternalis muscle revisited in South Indian male cadaver: a case report. *Cases J [serial online]* 2009; 6318-20.
- Raikos A, Paraskevas GK, Tzika M, Faustmann P, Triaridis S, Kordali P, et al. Sternalis muscle: an underestimated anterior chest wall anatomical variant. *J Cardiothorac Surg* 2011; 6:73-6.
- Saeed M, Murshid KR, Rufai AA, Elsayed SE, Sadiq MS. Sternalis: an anatomic variant of chest wall musculature. *Saudi Med J* 2002; 23:1214-21.
- Bae YL, Jae YB, Hak HK, Hyun SK, Song MC, Kang HL, et al. The sternalis muscles: incidence and imaging findings on MDCT. *J Thorac Imag* 2006; 21:179-83.
- Shen CL, Chien CH, Lee SH. A Taiwanese with a pair of sternalis muscles. *Kaibogaku Zasshi* 1992 Oct; 67(5): 652-4.
- Jeng H, Su SJ. The sternalis muscle: an uncommon anatomical variant among Taiwanese. *J Anat* 1998; 193:287-8.
- Barlow R. The sternalis muscle in American whites and negros. *Anat Rec* 1935; 61:413-26.
- Blees G. A peculiar type of sternalis muscle. *Acta Morphol Neerl Scand* 1968; 7:69-72.
- Kida MY, Izumi A, Tanaka S. Sternalis muscle: topic for debate. *Clin Anat* 2000; 13:138-40.
- Novakov SS, Yotova NI, Petleshkova TD, Muletarov SM. Sternalis muscle: a riddle that still awaits an answer short communication. *Folia Med (Plovdiv)* 2008; 50:63-6.
- Jelev L, Georgiev G, Surchev L. The sternalis muscle in the Bulgarian population: classification of sternaes. *J Anat* 2001; 199:359-63.
- O'Neill M, Folan-Curran C. Case report: bilateral sternalis muscle with a bilateral pectoralis major anomaly (letter). *J Anat* 1998; 193:289-92.
- Yap S. Musculus sternalis in Filipinos. *Anat Rec* 1921; 21:353-71.
- Harish K, Gopinath KS. Sternalis muscle: importance in surgery of the breast. *Surg Radiol Anat* 2003; 25:311-4.
- Morita M. Observations of the muscle sternalis and musculi pectoralis in mammals and morphological interpretation of the essence of the musculus sternalis. *Acta Anat Japon* 1944; 22:357-66.
- Loukas M, Bowers M, Hullett J. Sternalis muscle: a mystery still. *Folia Morphol* 2004; 63:147-9.

