

ความผิดปกติของต้นกำเนิดหลอดเลือดแดง subclavian ข้างขวา ร่วมกับความผิดปกติของ thoracic duct : รายงาน 1 ราย

มะลิวัลย์ นามกิ่ง, วรวิณี วรพุทธร, โกวิท ไชยสีวามงคล, สุภาวดี ชีระกุล, วรวิณี ชัยจรูญคุณารักษ์, วิไลวรรณ หม้อทอง
ภาควิชากายวิภาคศาสตร์ คณะแพทยศาสตร์ มหาวิทยาลัยขอนแก่น 40002

Anomalous Origin of the Right Subclavian Artery Associated with Right-sided Thoracic Duct: A Case Report

Malivalaya Namking, Worawut Woraputtaporn, Kowit Chaisiwamongkol, Supawadee Teerakul, Wunnee Chaijaroonkhanarak, Wilaiwan Mothong

Department of Anatomy, Faculty of Medicine, Khon Kaen University, Khon Kaen, 40002, Thailand

หลักการและเหตุผล: ความผิดปกติของแขนงหลอดเลือดแดงจาก arch of aorta ส่วนใหญ่เกิดจากการเจริญที่ผิดปกติของ branchial arches ของเอ็มบริโอ

วัตถุประสงค์: เพื่อรายงานความผิดปกติของต้นกำเนิดหลอดเลือดแดง subclavian ข้างขวาร่วมกับความผิดปกติของ thoracic duct และเส้นประสาท recurrent laryngeal ข้างขวา

วิธีการศึกษา: ทำการชำแหละศพใหญ่บริเวณกลางทรวงอกอย่างระมัดระวังเพื่อศึกษาแขนงหลอดเลือดแดงจาก arch of aorta วัดเส้นผ่าศูนย์กลางและความยาวของหลอดเลือดแดง subclavian ข้างขวาที่มีต้นกำเนิดที่ผิดปกติและค้นหาความผิดปกติอื่นที่เกิดร่วมกัน

ผลการศึกษา: พบความผิดปกติของต้นกำเนิดหลอดเลือดแดง subclavian ข้างขวาที่เกิดเป็นแขนงที่ 4 ของ arch of aorta ในร่างศพใหญ่เพศหญิงอายุ 80 ปี หลอดเลือดนี้แตกแขนงออกจากส่วนปลายของ arch of aorta และทอดข้ามแนวกึ่งกลางตัวที่ระดับกระดูกสันหลังอกที่ 3 ผ่านด้านหลังของหลอดอาหารเพื่อไปเลี้ยงแขนขวาโดยเป็นแขนงที่ใหญ่ที่สุดของ arch of aorta และพบร่วมกับความผิดปกติของ thoracic duct ที่ไปสิ้นสุดบริเวณรอยต่อระหว่างหลอดเลือดดำ internal jugular และ subclavian ข้างขวา และไม่มีเส้นประสาท recurrent laryngeal ข้างขวา

สรุป: กรณีศึกษาในร่างศพใหญ่เพศหญิงอายุ 80 ปี มีความผิดปกติของต้นกำเนิดหลอดเลือดแดง subclavian ข้างขวาโดยเกิดเป็นแขนงที่ 4 ของ arch of aorta พบร่วมกับความผิดปกติ

Background: Variations of the branches of the arch of aorta are mostly resulted from abnormal development of the branchial arches.

Objective: To present the abnormal origin of the right subclavian artery associated with abnormal thoracic duct and the right recurrent laryngeal nerve

Methods: Dissection of the mediastinum was carefully done to investigate the great vessels of the arch of aorta. The outer diameter and length of the anomalous right subclavian artery were measured. The other abnormally related structures were identified.

Results: The anomalous right subclavian artery was incidentally found in a female cadaver of 80 year-old. It arose as the fourth branch of the distal part of the arch of aorta and traveled across the midline at T3 retroesophageally to reach the right upper extremity. This anomalous artery was the biggest branch of the great vessels of the arch of aorta. It was associated with the abnormal right-sided thoracic duct and the absence of the right recurrent laryngeal nerve.

Conclusions: A case of 80 year-old female cadaver showed the abnormal origin of the right subclavian artery arising as the fourth branch of the distal part of the arch of aorta. It was associated with the abnormal right-sided thoracic duct and the absence of the right recurrent laryngeal nerve.

ของ thoracic duct ที่สิ้นสุดที่รอยต่อระหว่างหลอดเลือดดำ internal jugular และ subclavian ข้างขวา และไม่มีเส้นประสาท recurrent laryngeal ข้างขวา

Keywords: Anomalous subclavian artery, arch of aortic, abnormal development, anatomical variation

ศรีนครินทร์เวชสาร 2552; 24(1): 60-3 • Srinagarind Med J 2009; 24(1): 60-3

Introduction

Variation of the branches of the arch of aorta occurred as a result of abnormal development of certain branchial arches during embryonic life. Typically, there are three branches of the arch of aorta namely brachiocephalic trunk, left common carotid artery and left subclavian artery. The brachiocephalic trunk gives rise to the right subclavian and right common carotid artery. Anomalous right subclavian artery arising as the fourth branch of the arch of aorta is a relatively rare arch anomaly, occurring about 0.5% of individuals¹. However, this is the first case report of this type of anomalous found in the Department of Anatomy, Faculty of Medicine, Khon Kaen University since 1996.

Materials and Methods

Since 1996 to 2008, we looked for the incidence of the abnormal origin of the vertebral artery arising from the arch of aorta in the donated cadavers dissecting in gross anatomy laboratory. During cleaning the great vessels of the arch of aorta, we accidentally found an anomalous right subclavian artery arising as the fourth branch of the arch of aorta. Other abnormally related structures were also carefully identified. The width and length of the anomalous right subclavian artery were measured and compared to the other great vessels of the arch of aorta.

Results

The female cadaver, aged 80 years at the time of death, presented the anomalous origin of the right subclavian artery. It originated as the fourth branch of the arch of aorta distal to the left subclavian artery, then coursed posterior to the left subclavian artery retroesophageally and crossed the midline at the level of T3 vertebra to assume its position to reach the right upper extremity (Figure 1, 2). Therefore, the first branch of the arch of aorta was the right common carotid, the second branch was the left common carotid, the third was the left subclavian and the fourth was the anomalous right subclavian artery (Figure 2). The right recurrent laryngeal nerve was absent while the left recurrent laryngeal nerve was normal. We found that the right vagus nerve gave a branch directly entering the larynx in place of the absent right recurrent laryngeal nerve. Surprisingly, the thoracic duct joined to the right lymphatic duct, did not empty into the junction of the left internal jugular and left subclavian veins as it normally did. The morphometry of the great arteries is tabulated in table 1. Notice that the anomalous right subclavian artery was bigger and longer than the left subclavian artery.

Table 1 The diameter of the great vessels and the length of the subclavian arteries.

Outer diameter (cm) at the root of the great vessels	
Right common carotid artery	1.48
Left common carotid artery	0.85
Anomalous right subclavian artery	1.54
Left subclavian artery	0.87
Length (cm) of the subclavian arteries from their origins to roots of the vertebral arteries	
Anomalous right subclavian artery	6.49
Normal left subclavian artery	2.96

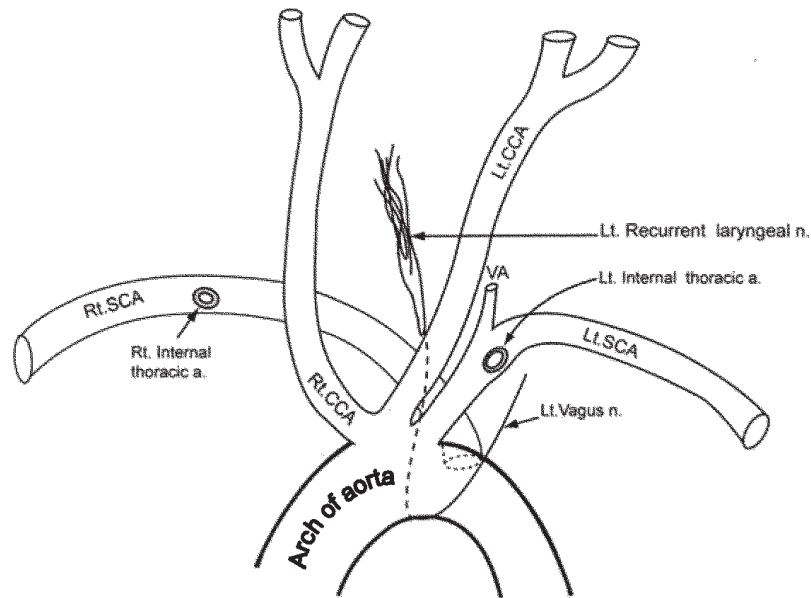


Figure 1 Diagram showing anomalous right subclavian artery (Rt. SCA) arising as the fourth branch from posterior part of distal aortic arch. Rt. CCA, right common carotid artery; Lt. CCA, left common carotid artery; Lt. SCA, left subclavian artery; VA, vertebral artery.

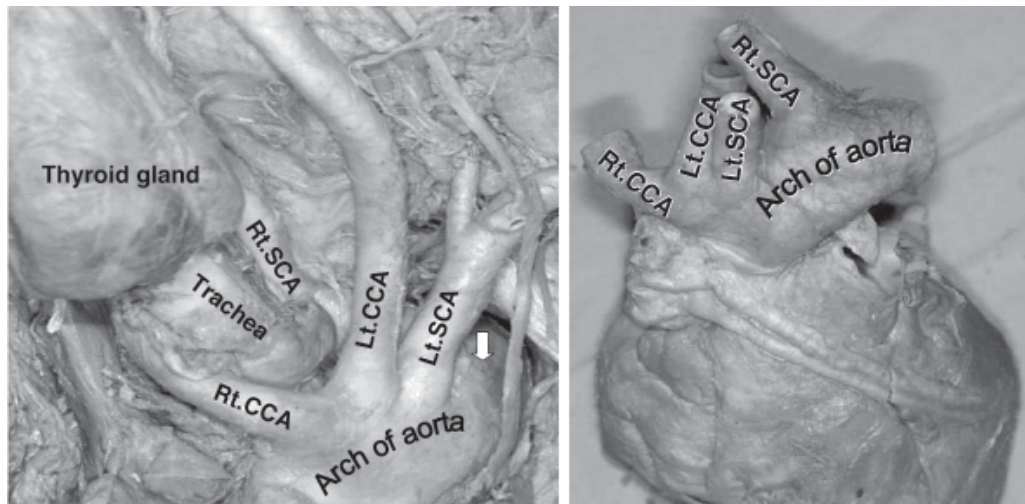


Figure 2 Aortic arch with four branches. Rt. CCA = right common carotid artery; Lt. CCA = left common carotid artery; Lt. SCA = left subclavian artery; Rt. SCA = anomalous right subclavian artery; arrow = root of anomalous Rt. SCA (left picture = the heart in situ; right picture = isolated heart).

Discussion

Anomalous origin of right subclavian artery arising as the fourth branch of distal part of the arch of aorta is about 0.5% of the general population¹. It is the first report of this type of anomaly in Khon Kaen University since 1996. In our series, the incidence is about 0.3% of Northeast population. The possible mechanism can be explained embryologically.

In the normal development, the fourth aortic arch on the right side, the right dorsal aorta, and the seventh intersegmental artery joined to form the right subclavian artery while the right dorsal aorta between the origin of the seventh intersegmental artery and the junction with the left dorsal aorta obliterated. The case we are reporting, the fourth aortic arch on the right side and the proximal part of the right dorsal aorta obliterated

while the right dorsal aorta from the seventh intersegmental artery to the junction with the left dorsal aorta developed further to become the right subclavian artery. Its position was shifted to the left by the shortening of the aorta between the left common carotid and the left subclavian arteries. The origin of the right subclavian artery is, therefore, on the left of the midline of the body as referred to the vertebral column. Because the stem of the artery derived from the right dorsal aorta, its course to the right upper extremity had to be posterior to the esophagus or foregut². The other abnormal findings associated with this anomaly were the absence of the right recurrent laryngeal nerve and a right-sided thoracic duct which was corresponded to Kieffer's report³ in 1994. Most cases of this particular anomaly are asymptomatic. Only few patients have feeding problems, asphyxia induced by feeding, dysphagia and failure to thrive⁴. However, this case who survived 80 years is quite a remarkable example of anatomical adjustment and defense mechanism of human body. When symptoms do occur, they are usually related to aneurysmal or occlusive sequelae of this variation. The symptoms are dysphagia, chest pain, dyspnea, cough, hoarseness, torticollis, and vertigo⁵. Such cases require the awareness of the varied right subclavian artery. Prior to surgical intervention, the radiologist and the surgeons should be aware of the anomalies associated with anomalous SCA to carry out an accurate diagnosis and most effective management.

Conclusion

The authors reported the first case of abnormal origin of the right subclavian artery arising as the fourth branch of the arch of aorta in a female cadaver (80 years by the time of

death) donated to the Medical School Department of Anatomy, Khon Kaen University. The anomalous right subclavian artery arose from the distal part of the arch of aorta and traveled across the midline at the level of T3 vertebra retroesophageally to reach the right upper extremity. It was associated with the abnormal right-sided thoracic duct and the absence of the right recurrent laryngeal nerve. The possible embryonic mechanism and the clinical importance of this anomalous was discussed.

Acknowledgements

The authors thanks Emeritus Professor Dr. Somboon SrungBoonmee for his preparation of this manuscript and Assistant Professor Songpol Oopachitkul for the diagram drawing.

References

1. Edwards LE. Malformations of the aortic arch system manifested as "vascular ring". *Lab Invest* 1953; 2:56-75.
2. Sadler TW. *Langman's Medical Embryology*. 6th ed. Philadelphia: Williams and Wilkins, 1990; 213-4.
3. Kieffer E, Bamini A, Koskas F. Aberrant subclavian artery: surgical treatment in thirty-three adult patients. *J Vasc Surg* 1994; 19:100-11.
4. Jan S, Hwang B, Fu Y, Chi C. A rare vascular ring caused by an aberrant right subclavian artery concomittant with the common carotid trunk: a report of two cases. *Int J Cardiovas Imag* 2006; 22:253-6.
5. Poulosides GA, Lolis ED, Vasques J, Drezner AD, Venieratos D. Common origins of carotid and subclavian arterial systems: report of a rare aortic arch variant. *Ann Vasc Surg* 2004; 18:597-600.

