

การศึกษานำร่อง : ผู้ป่วย 10 รายที่ประสบผลสำเร็จจากการผ่าตัดโดยวิธีดัดแปลง การผ่าตัดมดลูกทางช่องคลอดโดยใช้กล้องส่องช่วย ร่วมกับอุปกรณ์ศัลยกรรมมดลูก และคีมคีบมดลูก

โกวิท คำพิทักษ์¹, สิริวิชญ์ เตชะเจษฎารังสี², อัญชลี สิทธิเวช¹

¹ภาควิชาสูติศาสตร์และนรีเวชวิทยา คณะแพทยศาสตร์

²ภาควิชาวิศวกรรมเครื่องกล คณะวิศวกรรมศาสตร์ มหาวิทยาลัยขอนแก่น

A PILOT STUDY: The Ten Successful Cases of Modified Laparoscopically Assisted Vaginal Hysterectomy, Using Uterine Screw and Forceps

Kovit Khampitak¹, Sirivit Taechajedcadarungri², Anchulee Sittivech¹

¹Department of Obstetrics and Gynecology, Faculty of Medicine

²Department of Mechanical Engineering, Faculty of Engineer, Khon Kaen University, Khon Kaen, Thailand.

หลักการและเหตุผล: การผ่าตัดมดลูกทางช่องคลอดโดยใช้กล้องส่องช่วย ได้รับความนิยมเพิ่มขึ้นเรื่อยๆ อย่างไรก็ตาม การผ่าตัดวิธีนี้ยังคงมีข้อจำกัดในมดลูกขนาดใหญ่ ดังนั้น คณะผู้วิจัยจึงได้ดัดแปลงวิธีการผ่าตัดโดยใช้ร่วมกับอุปกรณ์ศัลยกรรมมดลูก และคีมคีบมดลูก เพื่อให้สามารถผ่าตัดผู้ป่วยที่มีมดลูกขนาดใหญ่ได้

วัตถุประสงค์: เพื่อประเมินประสิทธิผล และความปลอดภัยของการผ่าตัดโดยวิธีดัดแปลงการผ่าตัดมดลูกทางช่องคลอดโดยใช้กล้องส่องช่วย ร่วมกับอุปกรณ์ศัลยกรรมมดลูก และคีมคีบมดลูก

รูปแบบการวิจัย: การวิจัยเชิงพรรณนา

สถานที่วิจัย: โรงพยาบาลศรีนครินทร์ คณะแพทยศาสตร์ มหาวิทยาลัยขอนแก่น

กลุ่มตัวอย่าง: ผู้ป่วยที่เข้ารับการผ่าตัดมดลูกที่โรงพยาบาลศรีนครินทร์ด้วยข้อบ่งชี้ที่ไม่ใช่มะเร็ง หรือมีพังผืดติดแน่นในช่องท้อง และไม่สามารถผ่าตัดทางช่องคลอดตามปกติได้

ผลการศึกษา: จากการศึกษาผู้ป่วยจำนวน 10 ราย พบว่าผู้ป่วย 8 ราย เข้าผ่าตัดด้วย ข้อบ่งชี้ว่ามีก้อนเนื้ออกมดลูกที่มีขนาดมากกว่าหรือเท่ากับการตั้งครรภ์ 12 สัปดาห์ ผู้ป่วย 1 รายมีเลือดออกผิดปกติทางช่องคลอดเรื้อรังจากเนื้องอกมดลูกอยู่ในตำแหน่งใต้ต่อเนื้อเยื่อโพรงมดลูก และผู้ป่วย 1 ราย เข้ารับการผ่าตัดด้วยภาวะเลือดออกผิดปกติจาก

Background: Laparoscopically asisted vaginal hysterectomy (LAVH) has continued to gain popularly. However, one of the limitations is a huge leiomyoma. Modified LAVH, using uterine screw and forceps, was designed and introduced by our research team for solving this problem.

Study objective: To evaluate the effectiveness and safety of modified laparoscopically assisted vaginal hysterectomy (M- LAVH), using uterine screw and forceps.

Design: Descriptive study.

Setting: Srinagarind Hospital, Faculty of Medicine, Khon Kaen University.

Patients: Patients scheduled for hysterectomy for a benign condition, in whom a vaginal hysterectomy was not possible and no moderate to severe adhesion.

Interventions: Modified laparoscopically assisted vaginal hysterectomy (M- LAVH), using uterine screw and forceps.

Results: Ten patients were recruited in this study. Huge leiomyoma (≥ 12 week-size) was diagnosed in 8 patients. The others were recurrent uterine bleeding, caused by submucous leiomyoma, and recurrent dysfunctional uterine bleeding. The operative procedures were M- LAVH in 6 patients, additionally with unilateral salpingo-oophorectomy in 3 patients and bilateral salpingo-

โพรงมดลูกซ้ำโดยไม่พบพยาธิสภาพอื่น ผู้ป่วยได้รับการผ่าตัดเฉพาะมดลูก 6 ราย ตัดมดลูกร่วมกับปีกมดลูกและรังไข่ 1 ซ้ำ 3 ราย และ ร่วมกับตัดปีกมดลูกและรังไข่ออก 2 ซ้ำ 1 ราย ระยะเวลาผ่าตัดโดยเฉลี่ย คือ 194 นาที (S.D. = 54, 95% CI: 155.4, 232.6) เวลาเฉลี่ยของการใช้เข็มคีมและตัดมดลูก คือ 27 นาที (S.D. = 9.2; 95% CI: 20.4, 33.6) มัธยฐานของน้ำหนักมดลูกรวมปากมดลูก คือ 315 กรัม (พิสัย 270-750 กรัม) มีผู้ป่วย 2 ราย ที่มีผลข้างเคียงจากการผ่าตัด ผู้ป่วยรายที่หนึ่งมีการคลายปมของด้ายผูกเส้นเลือดเลี้ยงมดลูกเองภายหลังผ่าตัด 12 ชม. และได้ทำการส่องกล้องซ้ำเพื่อจี้เส้นเลือด อีก 1 รายมีภาวะติดเชื้อในอุ้งเชิงกรานในสัปดาห์ที่ 3 หลังผ่าตัด และได้เข้ารับการรักษากลับมา ผู้ป่วยเกือบทั้งหมดกลับบ้านในวันที่ 3 หลังผ่าตัด (พิสัย 2-5 วัน)

สรุป: การผ่าตัดโดยวิธีดัดแปลงการผ่าตัดมดลูกทางช่องคลอดโดยใช้กล้องส่องช่วย ร่วมกับอุปกรณ์สกรูยึดมดลูกและคีมคีมมดลูก เป็นวิธีที่มีความปลอดภัย และมีประสิทธิผลในการผ่าตัดมดลูก โดยเฉพาะเนื้องอกมดลูกที่มีขนาดใหญ่ จึงได้นำเสนอรายงานการศึกษา นำร่อง เพื่อให้ร่วมกันศึกษาถึงวิธีการผ่าตัดวิธีนี้ต่อไป

oophorectomy in 1 patient. The mean operative time was 194 minutes (S.D. = 54, 95% CI: 155.4, 232.6). The mean duration of forceps applied throughout the procedure was 27 minutes (S.D. = 9.2, 95% CI: 20.4, 33.6). The median weight of uterus, including cervix, was 315 gm (range 270-750 gm). Two patients developed post operative complications. One, whose the suture material of uterine artery had spontaneously slipped in 12 hours after surgery, was repeated laparoscopic electrocoagulation for homeostasis. Another developed pelvic inflammatory disease at the third week after operation. Almost all patients were discharged from the hospital on the third day after operation (range 2- 5 days).

Conclusions: M-LAVH, using uterine screw and forceps, is a safe and effective method for treatment the patient who indicated hysterectomy, especially due to large leiomyoma. Therefore we would like to distribute this new procedure to the gynecological laparoscopists for further study and further evaluate for improving the success of LAVH.

Keywords: Uterine forceps, LAVH, Laparoscopic hysterectomy

ศรีนครินทร์เวชสาร 2552; 24(1): 36-42 • Srinagarind Med J 2009; 24(1): 36-42

Introduction

Before laparoscopic hysterectomy (LH) was introduced for female pelvic surgery by Reich¹ total abdominal hysterectomy (TAH) had been recognized as a common operation. Since then, the variability for laparoscopic hysterectomy procedures have been developed by many physicians.²⁻⁶ Because of increase of operative complications, laparoscopically assisted vaginal hysterectomy (LAVH) was recommended in limited indications, as well as other types of LH.⁷ The LAVH was not recommended in leiomyoma larger than 13 cm.⁸ In Srinagarind Hospital since 1998, many patients with large leiomyoma (≥ 12 week- size) had been operated by LAVH. Two significant problems were detected in the operative field. The first issue was how to evaluate and clear the screen. The other concern was how to remove the uterine mass from the abdominal cavity. To resolve these problems, the Modified-LAVH (M-LAVH), using uterine screw and forceps, was introduced in early 2006 by Department of Obstetrics and Gynecology, Khon Kaen University.

In this article, we report our ten successful experience of M-LAVH with uterine screw and forceps. This research was approved by Ethic Committee and supported by Commission on Higher Education-Fund.

Materials and methods

This research was carried out from June to September 2006 at Srinagarind Hospital. The inclusion criteria were the patient, age over 18 year-old, with a strong indication of TAH that could not be operated by vaginal hysterectomy (V-hyst). All of the participants would not have moderate to severe endometriosis or chronic pelvic inflammatory disease (PID). The patients were preoperatively counseled on the risks versus the benefits of this operation. We recorded the duration of forceps application till finishing the sawing process, total operative time, actual uterine (included cervix) weight, and post-operative complications.

Surgical procedure

Under general anesthesia with endotracheal intubations, the urinary bladder was emptied and retained by a non-inflated balloon Foley catheter. Pneumo-peritoneum was performed via Verres needle with approximately 2 liters of CO₂. The four-puncture technique was used, a 10 mm. reusable cannula was placed supraumbilically for laparoscopic camera. After which, two 5 mm. cannulas were placed laterally in each lower quadrant and finally, a 5 mm. cannula was placed approximately 2 inches below the umbilicus.

If each side of adnexa was planed to remove, the uterine screw (5 mm.) would be inserted into the opposite side of lateral cannula and crossed direction to the uterine surface that located between uterine fundus and cornu. After screwing, the screw was pulled upward to expose adnexa and round ligament. The plasma kinetic (PK) coagulating and cutting device was used, through the lower umbilical cannula, to coagulate and transect the round ligaments and the infundibulopelvic ligaments (whenever the ovary was to be removed). Whenever the ovary was retained, the same technique was repeated to coagulate and transect the round ligaments, proximal fallopian tubes and ovarian ligaments. The same procedure was done on another side. The laparoscopic scissor was then inserted to dissect the vesico-uterine (peritoneal) reflex.

The vaginal procedure was started by using A-P retractors to expose the vaginal canal and cervix. First, the diluted-adrenaline (1:100,000) was injected around the cervix to minimize unnecessary bleeding. Then, the outer-cervix was incised circularly by knife. After that, re-incised and stopped bleeding by monopolar electrocoagulation. Allis clamps were used to lift the anterior incised vaginal fornix and then the sponge with gauze was pushed into the space between bladder and cervix up to the cut peritoneal reflex and abdominal cavity.

For the posterior approach, the posterior incised fornix was grasped by Allis clamps. Then, the index finger was used to push into the space between the clamps and cervix until the tense purple-membrane was seen and cut to expose the peritoneal cavity. The uterosacral ligaments and cardinal ligaments were clamped by Heaney clamps. The PK clamps were placed medially to the Heaney and electrocoagulation started. The coagulated ligaments were transected closely to

uterus by a Mayo scissor. Except transecting, the same procedure was done to the uterine vessels.

The uterine puncture was inserted through the cervical canal and screwed up to the estimated uterine division-point. Before the tip of puncture protruded into the abdominal cavity, by observing the whitening point on the uterine surface, the puncture-direction was pointed to the camera. These processes had to be done carefully under laparoscopic monitor. After the puncture was removed, the saw-hooker was inserted directly into the puncture hole to the peritoneal cavity.

Each branch of uterine forceps was prepared by inserting saw into the plastic shield and then into the forceps channel. The first branch of uterine forceps, with containing saw in place, was applied into the posterior space to cul-de-sac. Then, the second branch with containing saw was applied to anterior space to the abdominal cavity. After that, the forceps was locked. The next step, the anterior and posterior saw-rings, located near the tip of the forceps, were hooked by saw-hooker and pulled downward. After looking carefully via monitor, the uterus was slowly sawn, first by the posterior saw and then by the anterior saw. The forceps, plastic shield and saws were then removed. In order to prevent severe gas-leakage, this process should be done within 30 minutes. However, if the leakage was excessive, we should track the forceps downward until the pneumo-peritoneal was recovered.

The first part of uterus was then removed through the vaginal canal, and the uterine vessel stump was cut closely to uterine wall. The same process was repeated in another part. Then, the uterine vessel stumps were carefully checked for bleeding before closure of the vaginal stump. The vaginal stump was closed by delay absorbable suture. The inflated urinary catheter was retained until 24 hours after surgery.

The bleeding was rechecked via the laparoscopic monitor. The abdominal wall puncture sites were sutures and the patient was closely observed in the post operative room.

Antibiotic prophylaxis was used in every case. Preoperative ampicillin started with 2 gm intravenously and then, ampicillin 1 gm continued every 6 hours plus gentamicin 240 mg once a day until the patients were discharged. In the cases of febrile morbidity, we continued antibiotics by oral route for 14 days.

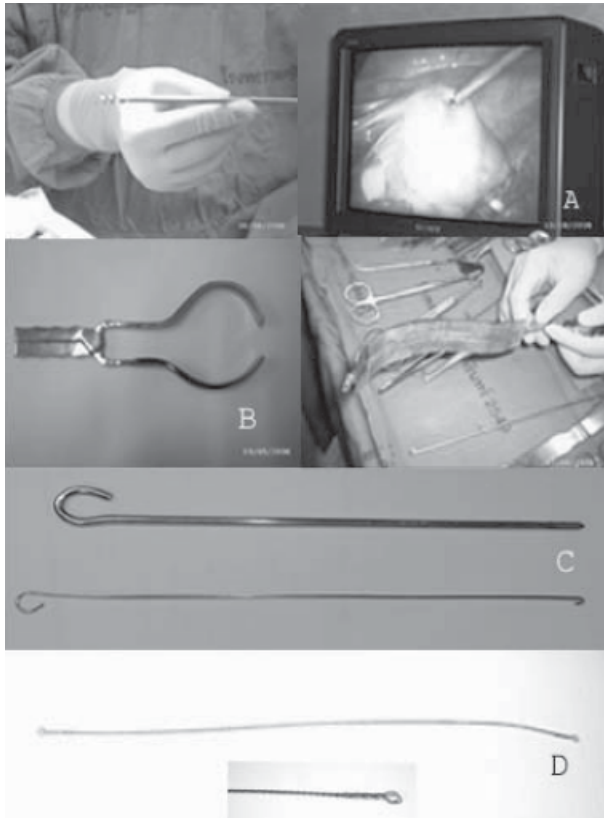


Figure 1 Innovative instruments in Modified laparoscopically assisted vaginal hysterectomy: A, Khampitak Uterine screw. B, Khampitak Uterine forceps. C, Uterine puncture and Saw hooker. D, Non-traumatic craniotomy-saw.

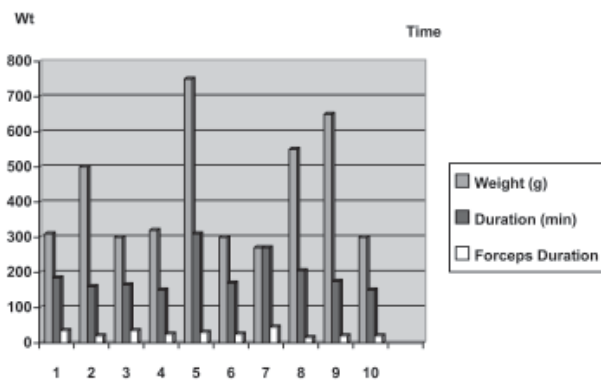


Figure 3 Uterine weight, duration of M-LAVH and duration of forceps application (by case numbers)

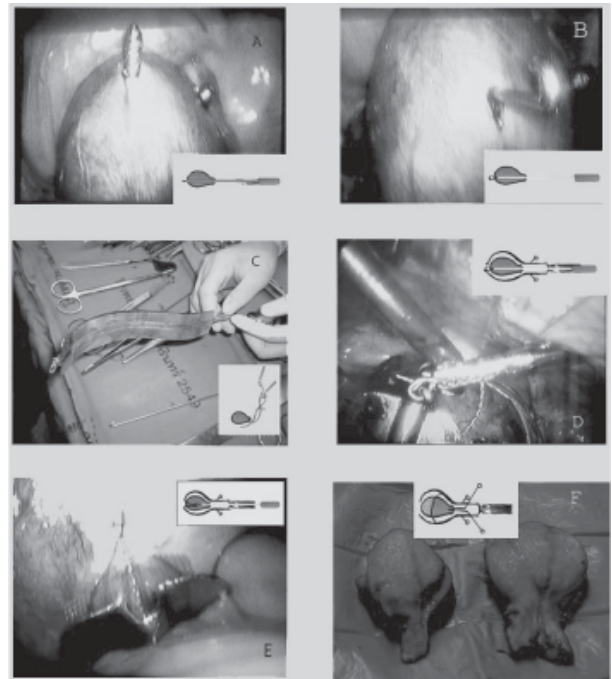


Figure 2 Illustration for transvaginal uterine removal process (After uterine arteries were electrocoagulated):

A, By traction on the cervix, uterine puncture was inserted through the cervical canal and screwed up to the estimated uterine division-point. Before the tip of puncture protruded into the abdominal cavity, by observing the whitening point on the uterine surface, the puncture-direction was pointing to the camera.

B, After removing the uterine puncture, saw hooker was inserted directly into the puncture hole to the peritoneal cavity.

C, Each branch of uterine forceps was prepared by inserting saw into the plastic shield and then into the forceps channel. The first branch of Uterine forceps, with containing saw in place, was applied into the posterior space to cul-de-sac. Then, the second branch with containing saw was applied to anterior space to the abdominal cavity. After that, the forceps was locked.

D, Next steps, the anterior and posterior saw-rings located near the tip of the forceps, were hooked by saw-hooker with the help of trans-abdominal laparoscopic grasper.

E, Then, saw-hooker was pulled downward.

F, After looking carefully via monitor, the uterus was slowly sawn, first at the posterior portion and then anterior portion. The forceps and saws were then removed. The first part of uterus was removed through the vaginal canal, and the uterine vessel stump was cut closely to uterine wall. The same process was repeated in another part.

Results

Of the 10 patients who were strongly indicated for total abdominal hysterectomy and were recruited for this study, a large leiomyoma (≥ 12 wk.) was diagnosed in 8 patients. The others suffered from recurrent uterine bleeding caused by submucous leiomyoma and recurrent dysfunctional uterine bleeding. The median age of the patients was 48.5 years (range 32-55 years). All were married and the median of parity was 2 (range 1-5). Almost all of the patients had no underlying disease except one, had diabetes mellitus and hypertension. The operative procedures were hysterectomy in 6 patients, additional with unilateral salpingo-oophorectomy in 3 patients and bilateral salpingo-oophorectomy in 1 patient. The mean operative time was 194 minutes (S.D.= 54, 95% CI: 155.4, 232.6). The mean duration of forceps applying throughout the procedure was 27 minutes (S.D. = 9.2, 95% CI: 20.4, 33.6). The median weight of uterus, including cervix, was 315 gm (range 270-750 gm).

The patient started the oral feeding 36 hours and started ambulation 14 hours after the operation. Almost all patients were discharged from the hospital on the third day after surgery (range 2-5 days).

Two patients had complications after operation and resolved after that. There was one case, the suture material of uterine artery had spontaneously disrupted and presented with a hypovolumic shock 12 hours after surgery and had a repeat laparoscopic re-electrocoagulation. Another developed a pelvic inflammatory disease in the third week after operation.

Discussion

Laparoscopic hysterectomy was first reported by Reich et al in 1989.¹ In the classical LAVH, the procedure is divided into two parts: laparoscopic and vaginal. The laparoscopic procedure did not include uterine vessel ligation.⁶ The uterine morcellation was required in all patients who underwent LAVH in uterine leiomyoma larger than 6 cm in diameter or uterine weighting at least 450 gm.⁸ Even though, the uterine leiomyoma larger than 13 cm were the contraindications to LAVH⁸, by the new method, the uterine screw and forceps are designed to operate on the uterine leiomyoma of any size, except for accompanying with moderate to severe intra-abdominal adhesion. In M-LAVH, surgical saw is applied through the intra-forceps channel and divides the uterus into

2 or 3 parts. This will make it easier and take shorter time in practice. In contrast to a very small piece of uterine tissue from the morcellation, the removed part of the uterus is close to normal sample for histo-pathological evaluation.

Laparoscopic subtotal hysterectomy (LSH) is one of various methods of laparoscopic hysterectomy described by Semm.⁹ However, the cervix is normally removed in nearly all cases of leiomyoma because of the high incidence of abnormal Pap smear and cervical carcinoma in Thailand.¹⁰ We also reported that the patients who had a total abdominal hysterectomy had a better sexual life than before.¹¹

ACOG committee recommended that the benefits of LAVH must be weighed against the potentially increased risk and expenses of two distinct operative procedures, laparoscopy and vaginal hysterectomy, each with its own risks.⁷

The uterine screw was also designed for traction of the huge and heavy uterus that was difficult to move or control by laparoscopic grasper or trans-vaginal uterine manipulator. It can provide high traction force making adequate operative field and able to leave the screw inside the uterus and electrocoagulate to prevent after-screw-removing hemorrhage.

The preoperative ultrasonographic examination was done in every cases.⁸ The advantages are to exclude the presence of a large ovarian tumor or ovarian endometriosis and to assess the size and position of the leiomyoma that allows adequate planning and selecting the proper point for cutting through with the uterine forceps. To be easily removed through the vaginal canal, the width of the sawn uterus should not more than 5 cm.

After incision around cervix, we used sponge with gauze to separate the bladder from cervix and uterine corpus, as we have had three cases experience in bladder injuries that were caused by using the classical process of LAVH (putting sponge with gauze at anterior fornix and cutting the vaginal wall via the laparoscopic procedure).

The mean operative time was 194 minutes and that was longer than other studies (mean 120 minute).¹² This phenomenon can be expected to be shorter according to the learning curve. In general, abdominal hysterectomy was performed significantly faster than laparoscopic hysterectomy (WMD 10.6 minutes, 95% CI: 7.4, 13.8) and vaginal hysterectomy also had a shorter operative time than laparoscopic hysterectomy (WMD 41.5 minutes, 95%

CI: 33.7, 49.4).¹³ However, the mean duration of forceps maneuver was 27 minutes, considered shorter than the first case report (35 minutes).¹⁴

One case developed late onset pelvic inflammatory disease while the urinary tract was evaluated normally by IVP, so that we had changed the duration of prophylactic antibiotics from 24 hours to three days after operation. McDonald PJ and his colleague reported that prophylactic antibiotics for hysterectomy should be given at least 7 doses, every 12 hour of Cefotaxime, to prevent post operative urinary tract infection.¹⁵ In addition, we had changed the procedure to close the vaginal cuff rather than leaving open to prevent the ascending infection.

After one case of post-operative arterial hemorrhage, we use the PK electrocoagulating clamps to the cardinal, uterosacral ligaments and uterine artery. It is assumed that the tension of all uterine sustained ligaments and vessels, and the located depth into the vaginal canal which were different from the relaxed and prolapsed ligaments in V-hyst-patient; electrocoagulation was more convenient and reliable than manually suture and ligation. In LAVH, the blood loss is usually less than total abdominal hysterectomy (TAH) and vaginal hysterectomy (V-hyst) except for the huge leiomyoma.^{4, 8, 13, 16}

However, the increased incidence of the urinary tract injury in LAVH would have to be closely observed in the following cases.¹⁷

The hospital stays for LAVH was generally shorter than V-hyst or TAH.^{6, 13, 16} In this study, almost all of the patients were able to return home 3 days after surgery.

Conclusion

M-LAVH with uterine screw and forceps was an effective and safe maneuver for laparoscopically assisted vaginal hysterectomy, especially for huge leiomyoma. The operative time are expected to be improved when the surgeon gained more skill. However, it is recommended that other complications should be closely observed. We would like to report the results and process of the study so that the procedure can be re-studied and re-evaluated by other gynecological laparoscopist for further recommendation.

Acknowledgement

The authors would like to thanks the Head of the Department of Obstetrics and Gynecology, Faculty of

Medicine, Khon Kaen University for giving permission to conduct this study Ms.Dararat Khampusaen for checking the English manuscript and the Commission on Higher Education for financial support of this study.

References

1. Reich H, DeCaprio J, McGlynn F. Laparoscopic hysterectomy. *J Gynecol Surg* 1989; 2:213-6.
2. Tintara H, Choobun T, Geater A. Gasless laparoscopic hysterectomy: A comparative study with total abdominal hysterectomy. *J Obstet Gynecol Res* 2003; 29: 38-44.
3. Kriplani A, Malhotra B, Meena S. One-step hysteroscopic myomectomy: Unusual cases and a review of the literature. *J Laparoendosc Adv Surg Tech* 2004; 14:390-4.
4. Sinha R, Hedge A, Warty N, Patel N. Laparoscopic excision of very large myomas. *J Am Assoc Gynecol Laparosc* 2003; 10:461-8.
5. Schultz K, Passover M, Merker A, Michel's A, Schneider A. Prospective randomized comparison of laparoscopic-assisted vaginal hysterectomy (LAVH) with abdominal hysterectomy (AH) for the treatment of uterus weighing >200g. *Surg Endosc* 2002; 16:121-5.
6. Johnson N, Barlow D, Lethaby A, Tavender E, Curr L, Garry R. Methods of hysterectomy: systematic review and meta-analysis of randomized controlled trials. *BMJ* 2005; 330:1478-81.
7. Committee Opinion, Appropriate Use of Laparoscopically Assisted Vaginal Hysterectomy. *Obstet Gynecol* 2005; 105:929-30.
8. Hwang J, Seow K, Tsai Y, Hsieh B, Lee C. Comparative study of vaginal, Laparoscopically assisted vaginal and abdominal hysterectomies for uterine myoma larger than 6 cm in diameter or uterus weighing at least 450 g: prospective randomized study. *Acta Obstet Gynecol Scand* 2002; 81:1132-8.
9. Danielle JF, Channel C, Staggs S, Lindsay J, Henry T. Early evaluation of an electromechanical Morcellator for laparoscopic supracervical hysterectomy. [Online] 2006 [cited 2006 April 20] Available from:URL: <http://www.obgyn.net>.
10. Srisomboon J. HPV and cervical cancer in Thailand. *CME PLUS* 2006; 50:7-14.
11. Punushapai U, Khampitak K. Sexuality after total abdominal hysterectomy in Srinagarind Hospital. *J Med Assoc Thai* 2006; 89:S112-7.

12. East M, VALH or LAVH? [online] 2006 [Cited March 25, 2006] Available from : URL: <http://www.obgyn.net>
13. Johnson N, Barlow D, Lethaby A, Tavender E, Curr E, Carry R. Surgical approach to hysterectomy for benign gynaecological disease. Cochrane Database of Systematic Review 2006, Issue 2. Art. No.:CD003677.DOI:10.1002/14651858.CD003677. pub3.
14. Khampitak K, Techajedcadarungri S. The first case: a success of using Khampitak uterine forceps in modified laparoscopically assisted vaginal hysterectomy. Srinagarind Med J 2007; 22: 105-16.
15. McDonald PJ, Sander R, Turnidge J, Hakendorf P, Jolley P, McDonald H, et al. Optimal duration of cefotaxime prophylaxis in abdominal and vaginal hysterectomy. Drugs 1988; 35:216-20.
16. Marana R, Busacca M, Zupi E, Garcea N, Paparella P, Catalano GF. Laparoscopically assisted vaginal hysterectomy versus total abdominal hysterectomy: a prospective, randomized, multicenter study. Am J Obstet Gynecol 1999; 180: 270-5.
17. Kadar N, Emmerling L. Urinary tract injuries during laparoscopically assisted hysterectomy: causes and prevention. Am J Obstet Gynecol 1994; 170: 47-8.

