

## ไตรูปเกือกม้าที่มีท่อไต 1 ท่อ : รายงาน 1 ราย

กิมภาพร ขมะณะรงค์, สุภาวดี ธีรกุล, สมศิริ รัตนสุวรรณ, กิตติศักดิ์ ศรีพานิชกุลชัย  
ภาควิชากายวิภาคศาสตร์ คณะแพทยศาสตร์ มหาวิทยาลัยขอนแก่น

# Horseshoe Kidney with Pyelic Fusion and Single Ureter: A Case Report

Kimaporn Khamanarong, Supawadee Teerakul, Somsiri Ratanasuwan, Kittisak Sripanidkulchai  
Department of Anatomy, Faculty of Medicine, Khon Kaen University, Khon Kaen 40002, Thailand

**หลักการและเหตุผล:** ความผันแปรของอวัยวะในร่างกาย เป็นสิ่งที่พบได้ในระหว่างการชำแหละศพ ในห้องปฏิบัติการ มหกายวิภาคศาสตร์

**วัตถุประสงค์:** เพื่อบันทึก และรายงาน ไตรรูปเกือกม้า ที่พบ ในห้องปฏิบัติการมหกายวิภาคศาสตร์ ซึ่งเป็นการพบรายแรก ของคณะแพทยศาสตร์ มหาวิทยาลัยขอนแก่น

**ผลการวิจัย:** พบไตรูปเกือกม้าในศพหญิงอายุ 82 ปี ซึ่งมี ท่อไตหนึ่งท่อ และ มีหลอดเลือดแดงหลายแขนงที่เข้ามาเลี้ยงไต

**คำสำคัญ:** ไตรรูปเกือกม้า หนึ่งท่อไต

**Background:** The variation of the organs in the body are some time found during dissection of formalin-embalmed cadavers in the practical class of Gross Anatomy.

**Objective:** To record and report the first case in 5 years of horseshoe kidney from the practical class of Gross Anatomy, Faculty of Medicine, Khon Kaen University.

**Results:** A horseshoe kidney was found in an 82-year-old female cadaver. The single ureter was found on the right side. The multiple segmental arterial supply to the horseshoe kidney were observed.

**Keywords:** horseshoe kidney, single ureter

---

ศรีนครินทร์เวชสาร 2551; 23(3): 317-9 • Srinagarind Med J 2008; 23(3): 317-9

---

### Introduction

The history of horseshoes kidney could be traced as far back as 1,552 when Berengario da Carpi first mentioned in the medical literature as quoted by Bordie<sup>1</sup>. It is the congenital anomaly resulted from the fusion of the inferior poles of the developing right and left metanephic blastemas to appear as an isthmus. Rarely the isthmus is formed between the superior poles, hence the inverted horseshoe is resulted. In either case, the isthmus thus formed is caught between the abdominal aorta and the inferior mesenteric artery. The prevalence is very low according to a presentation

by Bordei et al<sup>1</sup>: one in two hundred (Ferko), (Papin), 1/400 (Langman and Sadler), and 1/800 (Allen). This abnormality has not been reported in 5 years of KCU Medical school history of dissection of the Northeast Thailand cadavers totaled to 750 bodies.

### Objective

To record and report the first case of horseshoe kidney from Khon Kaen University Medical School dissecting room with unique anatomical features compatible with life for 82 years.

## Material and method

The authors surprised the case in the medical class dissection and were called attention to the posterior abdominal wall of a female cadaver aged 82 years at the time of death. After a thoroughly dissection, they found the strange structure bulging from the posterior abdominal wall into the peritoneal cavity. An additional cleaning revealed a horseshoe kidney and it was removed en masse the abdominal aorta with its renal branches and the inferior vena cava with its renal tributaries for further studies.

## Results

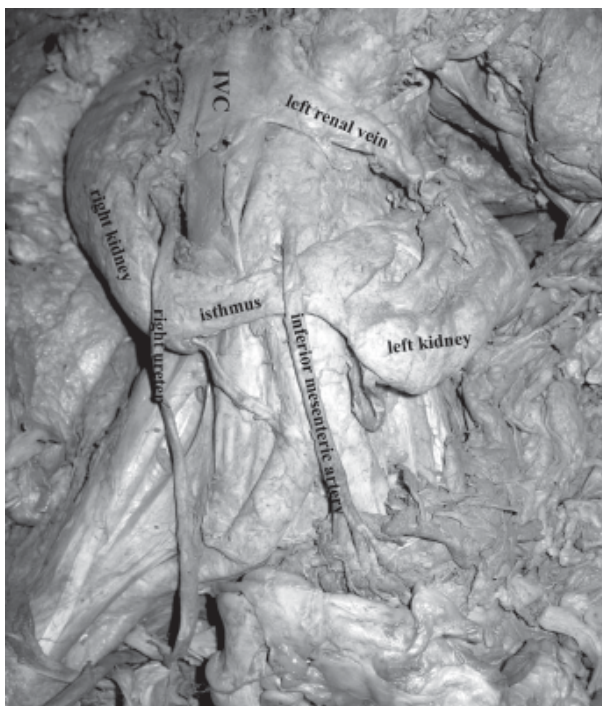
The authors observed that this horseshoe kidney was resulted from the fusion of the inferior poles by a narrow part or isthmus. The isthmus was seen to be parenchymatous tissue occupying the inferior portion while the superior portion portrays a renal pelvis. As it has been described, the isthmus was caught between the inferior mesenteric artery anteriorly and the abdominal aorta posteriorly. The arterial supply remained primitive just like the embryonic mesonephros, they are 1) superior renal artery, 2) middle

renal artery, and 3) inferior renal artery. The single ureter was found on the right side or from the right renal pelvis and continued down to the right side of the urinary bladder. (Figure 1,2)

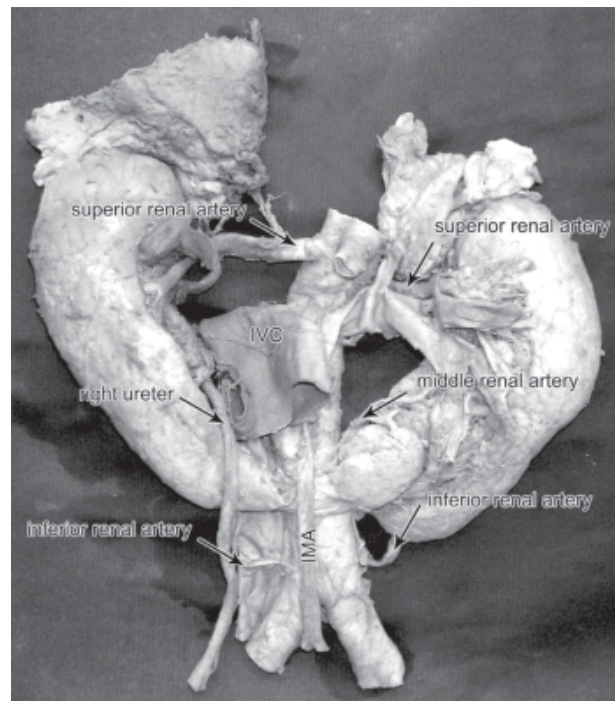
The left renal pelvis was observed as an underdeveloped cavity receiving major calices with a reduced sized and short ureter communicating with a pelvis in the isthmus. Examining the outer surface of the urinary bladder, they found no stump or opening of the ureter (ureteric orifice). The finding, therefore, are qualified to be a horseshoe kidney with pyelic fusion and single ureter.

## Discussion

The highest level that the horseshoe kidney can move upward or ascend is the level of the lower lumbar vertebrae because its isthmus is caught by the root of inferior mesenteric artery<sup>2</sup>. The appearances of metanephrogenic blastemas of right and left sides were observed at the ends of the metanephric buds, right and left, marked the beginning of the development of the metanephros or kidney. The sequences of events of this development take place in contrast to the



**Figure 1** Illustrates the horseshoe kidney with single ureter on the right side



**Figure 2** Shows the horseshoe kidney with multiple renal arteries

normal deterioration of the mesonephros. The metanephros must take over the function of mesonephros in the removal of waste products of the developing embryo. Molament<sup>3</sup> suggested the possible cause of horseshoe kidney as because of the growth rate between the slow metanephrogenic mass (from the intermediate mesoderm to become parenchyma) and the faster mesonephrogenic duct lengthening cranialward. The authors would like to propose the mechanism of the horseshoe kidney formation that the metanephrogenic masses of bothsides somehow, grow into the midline simultaneously with the metanephric buds sprouting out from the mesonephric duct possibly medially. The fusion could, therefore, be possible for the metanephrogenic mass from both sides. The subsequent development process goes on after the right and left metanephrogenic masses have fused. The progress corresponds with the development of the other parts of the kidney. The morphology of the horseshoe is increasingly obvious while the inferior part forms the isthmus that is caught at the root of the inferior mesenteric artery.

## Conclusion

This report shows that knowledge of anomalies is very important in planning and conducting surgical procedure on the colon and kidney. This is because of the displaced, abnormally shaped kidney together with its primitive segmental blood supply similar to that of the adrenal gland.

## Acknowledgement

We would like to thank Emeritus Professor Somboon SrungBoonmee for his editing this manuscript in the capacity of an English language Editor.

## References

1. Bordei P, Antohe DT, Iliescu D, Aapte E. "Horseshoe kidney" in an ectopic position. A case report. *Surg Radiol Anat* 2003; 25:345-9.
2. SrungBoonmee S. *Human embryology (Thai Textbook)*. Bangkok: Chulalongkorn University Press; 2000.
3. Molament M, Schwartz B, Nagamatsu G. External calyces, their relationship to renal disease. *Am J Roentgenol* 1961; 86:823-9.

