

## การศึกษานำร่องถึงผลของ hyaluronan ร่วมกับการเจาะกระดูกใต้ผิวข้อต่อ full-thickness defect ของข้อเข่าในกระต่าย

วัลวิสาช์ สุวรรณเลิศ<sup>1</sup>, วิรุพห์ เหล่าภัทรเกษม<sup>2</sup>, พีระพล สุขอ้วน<sup>3</sup>, ประวิทย์ บุตรอุดม<sup>4</sup>, พิสมย์ เหล่าภัทรเกษม<sup>1\*</sup>

<sup>1</sup>ภาควิชาเภสัชวิทยา, <sup>2</sup>ภาควิชาออร์โธปิดิกส์, คณะแพทยศาสตร์

<sup>3</sup>ภาควิชากายวิภาคศาสตร์, <sup>4</sup>ภาควิชาอายุรศาสตร์, คณะสัตวแพทยศาสตร์ มหาวิทยาลัยขอนแก่น 40002

## Combined Effect of Hyaluronan and Subchondral Bone Drilling on Full-Thickness Chondral Defect of the Knee in Rabbits: a Pilot Study

Wanwisa Suwannaloet<sup>1</sup>, Wiroom Laupattarakasem<sup>2</sup>, Peerapol Suk-Uan<sup>3</sup>, Pravit Bududom<sup>4</sup>, Pisamai Laupattarakasem<sup>1,\*</sup>

<sup>1</sup>Department of Pharmacology, <sup>2</sup>Orthopedics, Faculty of Medicine,

<sup>3</sup>Department of Anatomy, <sup>4</sup>Medicine, Faculty of Veterinary, Khon Kaen University 40002

**หลักการและเหตุผล:** กระดูกอ่อนผิวข้อมีข้อจำกัดในการซ่อมแซมตัวเอง เว้นแต่กรณีที่มีรอยโรคที่ทะลุผ่านชั้นกระดูกใต้ผิวข้อ อย่างไรก็ตาม fibrocartilage ที่เกิดขึ้นนี้จะมีคุณภาพต่อแรงกดได้น้อยกว่า hyaline cartilage ปกติ

**วัตถุประสงค์:** ศึกษาผลของการให้ hyaluronan (HA) ร่วมกับการเจาะกระดูกใต้ผิวข้อ (subchondral bone drilling, SBD) ต่อผลการซ่อมแซมรอยโรคของกระดูกอ่อนผิวข้อที่มีการหลุดร่อนถึงชั้นกระดูกใต้ผิวข้อ (full-thickness defect, FTD)

**วิธีการ:** ใช้กระต่ายเพศผู้ สายพันธุ์นิวซีแลนด์ อายุระหว่าง 3-4 เดือน เพื่อผ่าตัดข้อเข่าทั้งสองข้างและทำให้เกิดรอยโรคขนาด 5 มม x 12 มม แบบ FTD ตรงบริเวณ patellar groove เฉพาะข้อเข่าข้างซ้ายใช้สว่านเจาะรูกระดูกใต้ผิวข้อขนาด 1 มม จำนวน 6 รูให้มีเลือดไหลออกมาในพื้นที่ FTD เพื่อกระตุ้นการสร้าง fibrocartilage หลังการผ่าตัด 1 สัปดาห์ฉีด 0.3 มล HA เข้าไปในช่องข้อทุกสัปดาห์ติดต่อกัน 5 ครั้ง และฉีดน้ำเกลือในกลุ่มควบคุม หลังจากนั้นหนึ่งเดือนผ่ากระต่ายเพื่อนำเนื้อเยื่อบริเวณรอยโรคมาตรวจสอบดูลักษณะทางกายวิภาค จุลกายวิภาค และย้อมด้วยเทคนิคทางอิมมูโนวิทยาเพื่อตรวจหาคอลลาเจนชนิดที่ 1 และ 2 และ

**Background:** Articular cartilage has limited self-healing potential. The repair of a chondral lesion is often unsuccessful unless subchondral bone plate is penetrated. However, the quality of the regenerated fibrocartilage is mechanically inferior to that of hyaline cartilage.

**Objective:** To investigate the combined effect of hyaluronan (HA) and subchondral bone drilling (SBD) on the repair of full-thickness chondral defect (FTD) in rabbits.

**Materials and Methods:** Male New Zealand rabbits, 3-4 months old were used. A 5 mm x 12 mm FTD was created on the patellar groove of both knees and only the left knee was drilled to make six small holes (1 mm diameter) inside the FTD to induce fibrocartilage generation. A week after the surgery, the animals were treated weekly with 0.3 ml intra-articular HA injection for 5 consecutive weeks while the control group was injected with normal saline solution (NSS). One month after the treatment, the animals were sacrificed and the lesions were examined macroscopically, histologically, and immunohistochemically

\* ผู้รับผิดชอบบทความ (corresponding author)

การแบ่งตัวของเซลล์กระดูกอ่อน

**ผลการศึกษา:** พบเนื้อเยื่อเกิดใหม่ตรงบริเวณที่เจาะรู และจากลักษณะทางจุลกายวิภาคเป็นชนิด fibrocartilage. รอยโรคร่วมกับการเจาะรูในกระต่ายกลุ่มที่ได้รับ HA จะมีลักษณะทางจุลกายวิภาคที่แสดงถึงการซ่อมแซมอย่างชัดเจน เมื่อเทียบกับกลุ่มที่ได้รับ HA อย่างเดียว เมื่อเปรียบเทียบรอยโรคของข้อที่มีการการเจาะรูในกลุ่มที่ได้รับ HA กับกลุ่มควบคุม แสดงให้เห็นว่าการให้ HA เพิ่มการแบ่งตัวของเซลล์กระดูกอ่อนและเพิ่มปริมาณของคอลลาเจนชนิดที่ 2

**สรุป:** การฉีด HA เข้าข้อร่วมกับการเจาะกระดูกได้ผิวข้อ จะเพิ่มศักยภาพการซ่อมแซมกระดูกอ่อนผิวข้อที่มีการทำลายถึงกระดูกได้ผิวข้อ โดยอย่างน้อยเพิ่มการแบ่งตัวของเซลล์กระดูกอ่อนและเพิ่มการสร้างคอลลาเจนชนิดที่ 2

for the presence of type-I and type-II collagen as well as for chondrocyte proliferation.

**Results:** New tissue grossly formed around SBD areas with histological appearance of fibrocartilage. FTD plus SBD in HA treated group showed significantly better histological grading than FTD treated with HA alone. Comparing the SBD lesion between HA-treated with the control group, the former showed histological evidence of better healing with increased chondrocyte proliferation and type II collagen content than the latter.

**Conclusions:** Intraarticular injection of HA administered after SBD can enhance, at least in part, the quality of the repaired chondral tissue for FTD by increasing chondrocyte proliferation and type II collagen production.

**Keywords:** Osteoarthritis, hyaluronan, subchondral drilling, full-thickness defect

ศรีนครินทร์เวชสาร 2551; 23(3): 296-303 • Srinagarind Med J 2008; 23(3): 296-303

## Introduction

Lesions of the articular cartilage can be produced by various causes. A localized lesion usually results from trauma or is found in the early stage of some rheumatic diseases<sup>1,2</sup>. Degeneration of the cartilage then starts or is enhanced and results in full-thickness chondral defect (FTD) when the subchondral bone is exposed.

Unless the subchondral bone plate is microfractured, partial-thickness chondral defect holds limited healing potential because chondral tissue is avascular and prohibits entry of systemic progenitor cells. Now a day, the introduction of marrow stem cells into the defect site can be simple and performed arthroscopically. Common techniques include subchondral bone drilling (SBD) or prickling with an awl in a procedure called microfracture<sup>3</sup>. The recruited stem cells will then generate chondral tissue covering the defect<sup>4</sup>. However, this new tissue is mainly fibrocartilage consisting of type I collagen. It is mechanically less durable than normal hyaline cartilage that contains mainly type II collagen. This is a significant disadvantage of these procedures<sup>5,6</sup> in addition to being limited to small-size defects.

Another method to heal a small focal FTD is by autologous chondrocyte implantation (ACI)<sup>7</sup>. However, this technique is restricted by the need of healthy chondrocytes for cell culture, and is still technically complicated and costly. Untreated cartilage lesions usually will progress to develop osteoarthritis (OA) with extensive cartilage destruction and subsequent changes of other articular structures.

On the other hand, intraarticular injection of hyaluronan (HA) has been increasingly used in current clinical practice for early OA. HA, a non-sulfated glycosaminoglycan, is a major component of the extracellular cartilage matrix and the synovial fluid. It is generally produced by chondrocytes, synoviocytes and fibroblasts. Aggregates formed by HA and aggrecan absorb water molecules into the articular cartilage rendering it elastic and contributing to the shock absorbing properties of the joint. HA was found *in vivo* to stimulate production of sulfated glycosaminoglycans, chondroitin-6-sulphate, type II collagen<sup>8,9</sup> and proteoglycan<sup>10</sup>; all of which are key components of the hyaline cartilage. Injection of HA into animal knee joints has been shown to produce inhibitory effect on chondrolytic substances such as

metalloproteinase-3 (MMP-3), interleukin-1 $\beta$  (IL-1 $\beta$ )<sup>11</sup> and nitric oxide (NO)<sup>12</sup> in the synovial fluid. Other studies show that HA increases the expression of type II collagen mRNA<sup>13,14</sup> and type I procollagen mRNA<sup>15</sup>. Intraarticular HA can produce an analgesic effect comparable with that of NSAIDs and intraarticular corticosteroids<sup>16</sup>, and in addition, stimulates chondrocytes to produce type II collagen<sup>17</sup>. However, in late stage OA with FTD, intraarticular HA alone cannot stimulate cartilage regeneration<sup>18</sup> unless accompanied with scaffold filling in the defect.

In this study, we postulated that intraarticular injection of HA might stimulate or enhance the quality of chondral regeneration in FTD after SBD or microfracture and that HA would improve the properties of the fibrocartilage to be more comparable with that of normal hyaline cartilage.

Although arthroscopic microfracture is technically easier in humans, in this study we had to use open SBD rather than microfracture due to the smaller size and hardness of the subchondral bone in rabbits.

## Materials and Methods

### 1. Animals

Male New Zealand White rabbits (3-4 month old, 2.5-3.0 kg body weight) from National Experimental Animal Center, Mahidol University (Salaya), Thailand, were transported to Khon Kaen University by airplane. The animals were kept and fed under standard conditions in the Faculty of Veterinary Medicine. Permission for this experiment was granted by the Ethics Committee for Experimental Animal Utilization of Khon Kaen University (AE 006/50).

### 2. Creation of FTD and SBD in rabbits

FTD were created in both knees in each rabbit. SBD was additionally performed inside the FTD area on the left knee only. The operative technique was modified from that reported by Messner and Gillquist<sup>19</sup>. The method includes the following steps:

Each rabbit was fasted for 12-18 hours and pre-treated with intramuscular oxytetracycline (20 mg/kg) prior to the operation. The animal was anesthetized by intramuscular injection of ketamine (Calypsol<sup>®</sup>, 15 mg/kg), xylazine (L.B.S Laboratory Ltd., Part., 5 mg/kg) and acepromazine (Phenix Pharmaceutical, 1 mg/kg). The anterior part of both knees was shaved and cleaned using betadine solution. The animal was then secured on the operating table in supine position.

The knee was approached through an anterior patellar longitudinal incision, then by medial parapatellar arthrotomy. The patella was then retracted laterally without eversion. FTD was created along the patellar groove of the femoral condyle with a small curette. The defect was approximately rectangular (5 mm x 10 mm), removing only the covering articular cartilage to expose the subchondral bone. In many specimens, the articular cartilage was quite thin and therefore curettage was performed very carefully so as not to penetrate the subchondral layer and cause bleeding. Drillings were carried out on the left knee using a small drill bit (Chondropick<sup>®</sup>). Six drill holes (2 longitudinal rows, 3 holes in each row) were made inside the bare subchondral area. The operative field was irrigated clean and the wound was then closed in layers. Bleeding was usually not active while making sutures and therefore neither a drainage system nor external compression was required. Oxytetracycline (20 mg/kg) was given intramuscularly for 6 days and the stitches were removed on day 7 without anesthesia.

### 3. Study of effects of hyaluronan (HA)

At one week post-surgery, the animals were divided into two groups, the experimental group and the control group with 4-5 animals in each group. In experimental group, each animal received one intraarticular injection of 0.3 ml sodium hyaluronate (Hyalgan<sup>®</sup>; FIDIA Pharmaceutical, Italy) in both knee joints per week for 5 consecutive weeks at the superolateral corner of the patella. In control group, 0.3 ml NSS was injected similarly instead of hyaluronan. The animals were sacrificed at postoperative week 9 to investigate both morphological and histological results. Two investigators were assigned to examine the specimens blindly and independently. Morphology of the new cartilage was recorded by high power photography and the microanatomy of the tissue was processed using Hematoxylin-Eosin (H&E) staining according to the Dorotka<sup>20</sup> criteria (Table 1). Healing properties of the tissue was assessed by measuring proliferating-cell nuclear antigen (PCNA, Dako<sup>®</sup>, USA) and collagen type tested for immunohistochemistry to indicate chondrocyte division.

### 4. Analytical statistics

Number of PCNA was analyzed using Student's t-test, while quantity of collagen type was analyzed by chi-square test and Fisher's exact test. Statistical significance was determined when p-value was less than 0.05.

**Table 1** Histological criteria used to demonstrate tissue types (Dorotka et al., 2005)

Tissue type	Histological criteria
Fibrous tissue	<ul style="list-style-type: none"> <li>- Highly orientated type-I collagen fibrous structure.</li> <li>- Cells with elongated shape, not in lacunae.</li> </ul>
Hyaline cartilage	<ul style="list-style-type: none"> <li>- Ground glass-like appearance of the matrix.</li> <li>- Type-II collagen staining (with variable intensity of the latter).</li> <li>- Spherical chondrocytes in mature lacunae.</li> </ul>
Fibrocartilage	<ul style="list-style-type: none"> <li>- Encompassed a wide range of tissues between fibrous tissue and hyaline cartilage, including fibrocartilage.</li> <li>- Oval and spherical cell shapes with and without lacunae.</li> <li>- Varying intensity of staining for proteoglycans and type-I and -II collagen.</li> <li>- No hyaline appearance of the matrix.</li> </ul>
Articular cartilage	<ul style="list-style-type: none"> <li>- Hyaline cartilage with columnar arrangement of the cells.</li> <li>- Matrix staining typical of articular cartilage.</li> </ul>

## Results

### 1. Morphological and histological characteristics of FTD in animal knees

Normal articular cartilage from the rabbit knee aged 3-4 months appeared white, clear and glistening (Fig 1A). FTD site was grossly dull and pale-yellowish (Fig 1B). Chondrocytes (H&E stain) in superficial zone in normal cartilage lined up tangentially to the articular surface and aligned as vertical columns in deeper zone (Fig 1C). In the base of FTD, only the subchondral bone plate was seen as cartilage cells had been removed (Fig 1D).

### 2. Result of SBD in FTD site at postoperative week 9

#### 2.1 Morphological and histological characteristics

Spot of new cartilaginous tissue, surrounding the central drill hole, was seen in FTD plus drilling (Fig 2B) compared with FTD alone (Fig 2A). When compared histologically (H&E stain) the latter showed only fibrosis (Fig 2C) while drilling stimulated fibrocartilage formation (Fig 2D). Cell pattern appeared scattered with irregular cell sizes, round or oval shape. Some of them did not show lacunae specific to chondrocytes. On PCNA staining, there

was a significant increase in cell division activities in FTD with drilling (which stimulated fibrocartilage formation) compared with the FTD-alone group ( $p < 0.001$ ).

#### 2.2 Collagen type

Immunohistochemistry revealed higher amount of type I collagen in FTD-alone area (Fig 3C) compared to FTD with drilling (Fig 3E) and normal cartilage (Fig 3A). In contrast, type II collagen was found mostly in normal cartilage (Fig 3B) which was more than that of FTD-only (Fig 3D) and FTD with drilling areas (Fig 3F). Quantitative scoring of each collagen type according to the amount of staining indicated that FTD with drilling showed a significantly lower amount of type II collagen compared with normal articular cartilage ( $p < 0.001$ ) while it had higher amount of type I collagen but this was not statistically significant ( $p > 0.05$ ).

### 3. Result of intraarticular HA injection at postoperative week 9

#### 3.1 Result of HA on FTD

H&E staining showed fibrosis of the tissue obtained from the FTD treated with HA and in control (treated with NSS). This result was concordant with that of PCNA staining ( $p = 0.054$ ). The amount of type I and type II collagens were also not significantly different in these groups ( $p = 0.24$  and  $p = 0.10$ , respectively).

H&E staining of the regenerated tissue obtained in HA-treated group compared with control showed an increase in cartilage formation. Noticeably, the new cartilage was thicker in HA-treated group, which agreed with the result indicated by PCNA staining ( $p=0.03$ ). Morphologically, lacuna formation was obvious and chondrocyte alignments were similar to normal articular cartilage pattern. In addition, the matrix was stained pinkish and was comparable with appearance of the hyaline cartilage.

Quantitative assessment for collagen using immunohistochemical staining reveals that HA-treated group contains significantly higher amount of type II collagen (Fig 4D) compared with the control (Fig 4B) ( $p < 0.0001$ ). Besides, HA also significantly enhanced type I collagen formation (Fig 4C) ( $p = 0.003$ ).

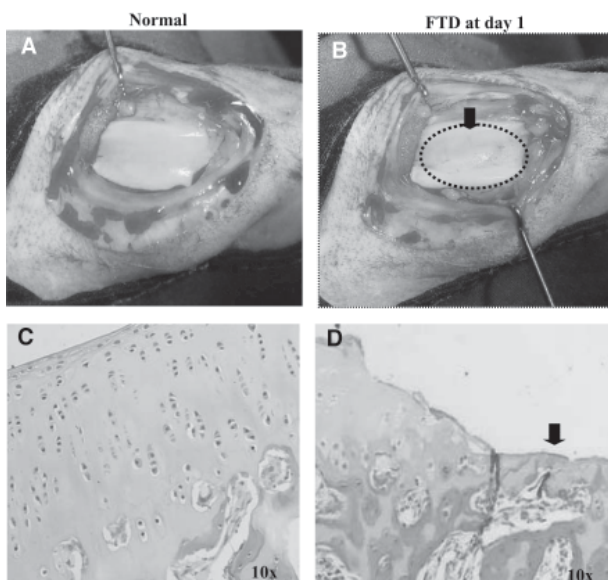
### Discussion

Artificial FTD on the patellar groove of rabbit knees performed using the curette to simulate pathologic articular cartilage lesion produced chondral loss at the curetted area (Fig 1D). Nine weeks after the operation, fibrous tissue (Fig 2C) high in type I collagen content (Fig 3C) was formed to heal the FTD site. This phenomenon was concordant with

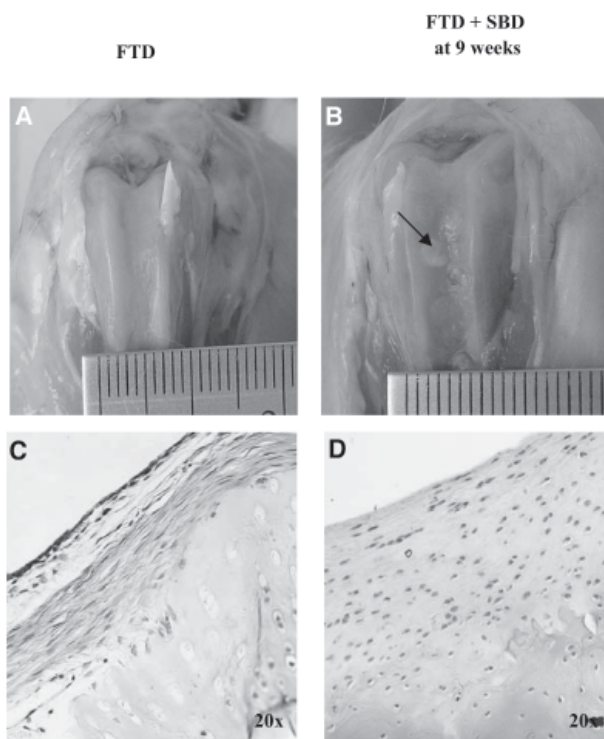
results reported by Furukawa that high content of type I collagen was found in the healing tissue within the cartilage defect<sup>21</sup>.

In this experiment, new chondral tissue grew around the drilled holes in the FTD site (Fig 2B). The new tissue was by nature a fibrocartilage proven histologically by H&E stain (Table 1 and Fig 2D) as well as PCNA stain. Content of type I collagen was higher than that of type II in this tissue (Fig 3E and 3F, respectively), in contrast to normal hyaline cartilage (Fig 3A and 3B). These findings agree with the study reported by Freemont and Hoyland<sup>22</sup>.

Friability and mechanical weakness of the fibrocartilage challenge the search of more appropriate substance to modify the quality of cartilaginous healing stimulated by subchondral bone penetration. In this experiment, we choose HA which is a common medication currently used to treat early stage



**Figure 1** Morphology and H&E-stained histological sections of normal articular cartilage (A, C) compared with FTD (B, D). The arrows indicate the defect.



**Figure 2** Morphology and H&E-stained histological sections of FTD (A, C) and FTD plus SBD (B, D) at 9 weeks after surgery. The arrow demonstrates the newly formed cartilage induced by drilling (B). According to Dorotka's criteria, H&E-staining shows fibrosis and fibrocartilage in FTD and FTD plus SBD, respectively (C, D).

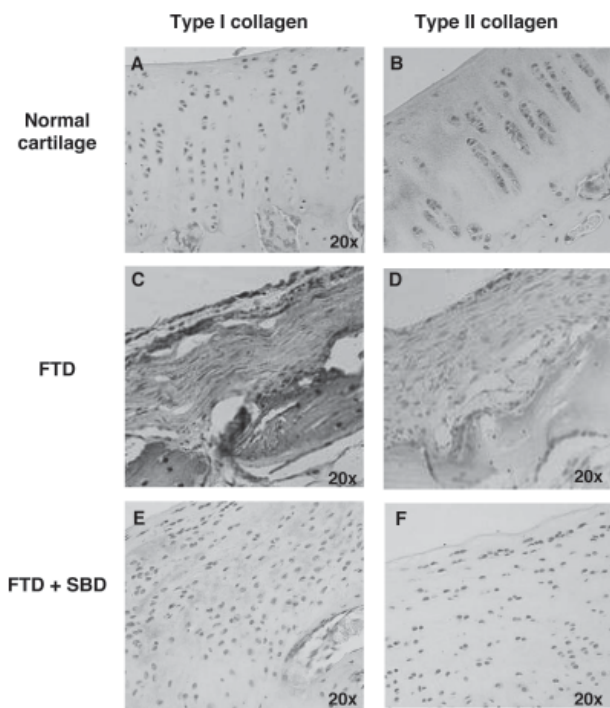
of OA for analgesic effect and to decelerate the disease process<sup>23</sup>.

In our study, HA alone did not stimulate chondral regeneration in FTD as had been reported by Evanich<sup>24</sup>. Therefore, it is inadvisable to treat late stage OA patients under such indication, although symptomatic relieves which help delay replacement arthroplasty have been reported. Anyhow, chondrocyte division can be stimulated by HA plus beta fibroblast growth factor (b-FGF)<sup>25</sup>. In an earlier study, Steadman noted that microfracture introduced access of mesenchymal stem cells and many growth factors, such as transforming growth factor- $\beta$  (TGF- $\beta_1$ ) and b-FGF, into the joint<sup>3</sup>. These growth factors would then help transform mesenchymal stem cells into chondrocytes and increase chondrocyte proliferation<sup>26-28</sup>. In our study, we also found that

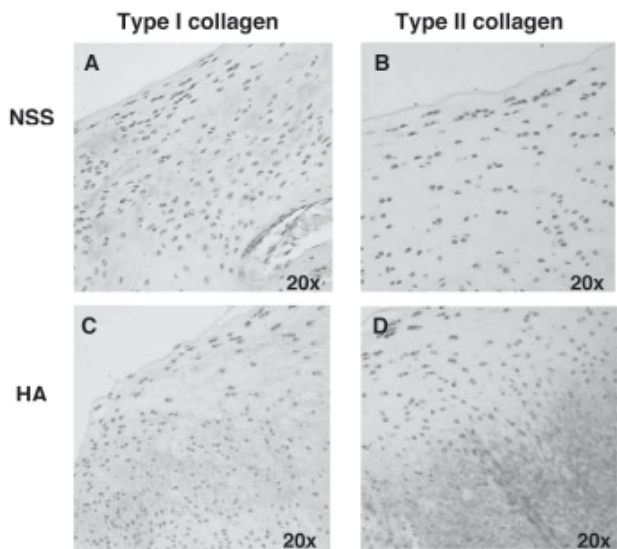
HA treatment after SBD significantly enhanced chondrocyte division compared with control. This was evidenced by the significant increase of PCNA value ( $p=0.03$ ). HA in this model enhanced type II collagen content (Fig 4D) in agreement with Karna et al. who had similar findings and suggested that HA might facilitate prolydase function in collagen biosynthesis<sup>9</sup>. Therefore, our results show an increase of both type I and type II collagen (Fig 4C and 4D, respectively). Nonetheless, the biosynthesis of type II collagen is more pronounced than that of type I collagen.

### Conclusion

We used full-thickness chondral defect (FTD) at the patellar groove in rabbit knees as a model in this study. Our findings suggest that five successive weekly intraarticular injections of hyaluronan (HA) a week after subchondral bone drilling (SBD) stimulates chondrocyte division and increases type II collagen content. We believe that this procedure is feasible to improve the properties of the fibrocartilage



**Figure 3** Immunological staining for collagen type in normal, FTD-only and FTD plus SBD. Type I collagen (stained in brown) was seen predominantly in FTD (C) and FTD plus SBD (E) compared with normal cartilage (A); while type II collagen (also stained in brown) was found mostly in normal cartilage (B), which was more intense than that of FTD (D) or FTD plus SBD (F).



**Figure 4** Immunological staining for collagen type in HA-treated group compared with control in FTD plus SBD. Significantly higher amount of type II collagen was noted in HA-treated group compared with control. Notice that the amount of type I collagen is also increased in HA-treated group.

regenerated as a result of ordinary healing process to a quality closer to that of hyaline cartilage. This finding opens a new prospect of combining with SBD or comparably, microfracture, as a treatment of FTD in the human joint.

### Acknowledgement

We thank Associate Professor Banchob Sripana, Assistant Professor Sirikachorn Tangkawattana, Ms. Em-orn Phanomsri and Ms. Preeyaporn Sangjun for their assistance in tissue processing and staining technique, the Clinical Epidemiology Unit for data analysis and Khon Kaen University for funding this research.

### References

1. Elsaid KA, Jay GD, Chichester CO. Detection of collagen type II and proteoglycans in the synovial fluids of patients diagnosed with non-infectious knee joint synovitis indicates early damage to the articular cartilage matrix. *Osteoarthritis Cartilage* 2003; 11:673-80.
2. Fraser A, Fearon U, Billingham RC, Ionescu M, Reece R, Barwick T, et al. Turnover of type II collagen and aggrecan in cartilage matrix at the onset of inflammatory arthritis in humans: relationship to mediators of systemic and local inflammation. *Arthritis Rheum* 2003; 48:3085-95.
3. Steadman JR, Rodkey WG, Rodrigo JJ. Microfracture: surgical technique and rehabilitation to treat chondral defects. *Clin Orthop Relat Res* 2001; S362-9.
4. Pittenger M, Mackey A, Beck S. Multilineage potential of adult human mesenchymal stem cell. *Science* 1999; 284:143-7.
5. Minas T, Nehrer S. Current concepts in the treatment of articular cartilage defects. *Orthopedics* 1997; 20:525-38.
6. Gilbert JE. Current treatment options for the restoration of articular cartilage. *Am J Knee Surg* 1998; 11:42-6.
7. Brittberg M, Lindahl A, Nilsson A, Ohlsson C, Isaksson O, Peterson L. Treatment of deep cartilage defects in the knee with autologous chondrocyte transplantation. *N Engl J Med* 1994; 331:889-95.
8. Akmal M, Singh A, Anand A, Kesani A, Aslam N, Goodship A, et al. The effects of hyaluronic acid on articular chondrocytes. *J Bone Joint Surg Br* 2005; 87:1143-9.
9. Karna E, Milyk W, Palka JA, Jarzabek K, Wolczynski S. Hyaluronic acid counteracts interleukin-1-induced inhibition of collagen biosynthesis in cultured human chondrocytes. *Pharmacological Research* 2006; 54:275-81.
10. Kikuchi T, Yamada H, Fujikawa K. Effects of high molecular weight hyaluronan on the distribution and movement of proteoglycan around chondrocytes cultured in alginate beads. *Osteoarthritis and Cartilage* 2001; 9:351-6.
11. Takahashi K, Goomer RS, Harwood F, Kubo T, Hirasawa Y, Amiel D. The effects of hyaluronan on matrix metalloproteinase-3 (MMP-3), interleukin-1[beta](IL-1[beta]), and tissue inhibitor of metalloproteinase-1 (TIMP-1) gene expression during the development of osteoarthritis. *Osteoarthritis and Cartilage* 1999; 7:182-90.
12. Takahashi K, Hashimoto S, Kubo T, Hirasawa Y, Lotz M, Amiel D. Hyaluronan suppressed nitric oxide production in the meniscus and synovium of rabbit osteoarthritis model. *Journal of Orthopaedic Research* 2001; 19:500-3.
13. Allemann F, Mizuno S, Eid K, Yates KE, Zaleske D, Glowacki J. Effects of hyaluronan on engineered articular cartilage extracellular matrix gene expression in 3-dimensional collagen scaffolds. *J Biomed Mater Res* 2001; 55:13-9.
14. Ohno S, Schmid T, Tanne Y, Kamiya T, Honda K, Ohno-Nakahara M, et al. Expression of superficial zone protein in mandibular condyle cartilage. *Osteoarthritis and Cartilage* 2006; 14:807-13.
15. Sonoda M, Harwood FL, Wada Y, Moriya H, Amiel D. The effects of hyaluronan on the meniscus and on the articular cartilage after partial meniscectomy. *Am J Sports Med* 1997; 25:755-62.
16. Altman RD. Intra-articular sodium hyaluronate in osteoarthritis of the knee. *Seminars in Arthritis and Rheumatism* 2000; 30:11-8.
17. Pasquali RI, Guerra D, Taparelli F, Boraldi F, Bergamini G, Mori G, et al. Morphological analysis of knee synovial membrane biopsies from a randomized controlled clinical study comparing the effects of sodium hyaluronate (Hyalgan) and methylprednisolone acetate (Depomedrol) in osteoarthritis. *Rheumatology (Oxford)* 2001; 40:158-69.

18. Barr AR, Duance VC, Wotton SF, Waterman AE. Influence of intra-articular sodium hyaluronate and polysulphated glycosaminoglycans on the biochemical composition of equine articular surface repair tissue. *Equine Vet J* 1994; 26:40-2.
19. Messner K, Gillquist J. Cartilage repair. A critical review. *Acta Orthopaedica Scandinavica* 1996; 67:523-9.
20. Dorotka R, Windberger U, Macfelda K, Bindreiter U, Toma C, Nehrer S. Repair of articular cartilage defects treated by microfracture and a three-dimensional collagen matrix. *Biomaterials* 2005; 26:3617-29.
21. Furukawa T, Eyre DR, Koide S, Glimcher MJ. Biochemical studies on repair cartilage resurfacing experimental defects in the rabbit knee. *J Bone Joint Surg Am* 1980; 62:79-89.
22. Freemont AJ, Hoyland J. Lineage plasticity and cell biology of fibrocartilage and hyaline cartilage: Its significance in cartilage repair and replacement. *European Journal of Radiology Cartilage Transplantation - Cartilage Transplantation* 2006; 57:32-6.
23. Miltner O, Schneider U, Siebert CH, Niedhart C, Niethard FU. Efficacy of intraarticular hyaluronic acid in patients with osteoarthritis'a prospective clinical trial. *Osteoarthritis and Cartilage* 2002; 10:680-6.
24. Evanich JD, Evanich CJ, Wright MB, Rydlewicz JA. Efficacy of intraarticular hyaluronic acid injections in knee osteoarthritis. *Clin Orthop Relat Res* 2001; 173-181.
25. Maniwa S, Ochi M, Motomura T, Nishikori T, Chen J, Naora H. Effects of hyaluronic acid and basic fibroblast growth factor on motility of chondrocytes and synovial cells in culture. *Acta Orthop Scand* 2001; 72:299-303.
26. Kang SW, Bada LP, Kang CS, Lee JS, Kim CH, Park JH, et al. Articular cartilage regeneration with microfracture and hyaluronic acid. *Biotechnol Lett* 2007.
27. Im GI, Jung NH, Tae SK. Chondrogenic differentiation of mesenchymal stem cells isolated from patients in late adulthood: the optimal conditions of growth factors. *Tissue Eng* 2006; 12:527-36.
28. Hutchison MR, Bassett MH, White PC. Insulin-like growth factor-I and fibroblast growth factor, but not growth hormone, affect growth plate chondrocyte proliferation. *Endocrinology* 2007; 148: 3122-30.

