

Multi-detector Computed Tomography versus Endoscopic Ultrasonography for the Detection of Pancreatic Cancer

Pradermchai Kongkam MD¹, Veeravich Jaruvongvanich MD¹, Khin Ave MD²,
Satimai Aniwana MD¹, Surachai Amornsawadwattana MD¹, Akira Aso MD¹,
Shuji Shimizu MD, PhD¹, Pinit Kullavanijaya MB, ChB¹, Rungsun Rerknimitr MD¹

* Pancreas Research Unit, Gastrointestinal Endoscopy Excellence Center, Department of Medicine, Faculty of Medicine, Chulalongkorn University and King Chulalongkorn Memorial Hospital, Thai Red Cross Society, Bangkok, Thailand

** Department of Endoscopic Diagnostics and Therapeutics, Kyushu University Hospital, Fukuoka, Japan

Objective: Endoscopic ultrasonography [EUS] has been claimed to be superior to computed tomography in detecting pancreatic cancer. However, there have been only few studies comparing multi-detector computed tomography [MDCT] with EUS. This study aims to compare the detection rate of EUS with that of MDCT for pancreatic cancer.

Materials and Methods: This retrospective study took place in January 2009 to January 2014 at King Chulalongkorn Memorial Hospital, Bangkok, Thailand. Patients who underwent both EUS and MDCT for suspected or known pancreatic cancer were included. Patients with insufficient data, cystic pancreatic lesion, benign masses and/or other malignant masses were excluded. Only patients with pathologically proven pancreatic ductal adenocarcinoma were included for analysis. The detection rates of EUS and MDCT for pancreatic cancer were compared.

Results: Sixty-eight patients with pathologically proven pancreatic adenocarcinoma (mean age 63.2±10.9 years) were analyzed. The mean maximal diameters of lesions identified (n = 60) and missed (n = 8) by MDCT were 43.7±15.6 mm and 18.4±2.9 mm, respectively. EUS and MDCT detection rate for pancreatic cancer was 98.5% and 88.2%, respectively. In pancreatic tumors 2 cm in diameter, EUS and MDCT detection rate was 83.3% and 0%, respectively. The pancreatic tumors that were missed by EUS were associated with baseline calcified chronic pancreatitis.

Conclusion: EUS had a higher detection rate than MDCT for detection of pancreatic cancer, particularly for small pancreatic tumors. However, it missed pancreatic tumor in a patient with calcified chronic pancreatitis.

Keywords: Endoscopic ultrasonography, Endoscopic ultrasound, Endosonography, EUS, Pancreatic cancer, Pancreatic neoplasm, Solid pancreatic lesion,

J Med Assoc Thai 2018; 101 (Suppl. 4): S59-65

Full text. e-Journal: <http://www.jmatonline.com>

Pancreatic cancer is the tenth most common cancer, and is ranked as the fourth or fifth most common cause of cancer-related death^(1,2). Consequently, it is

Correspondence to:

Kongkam P, Gastrointestinal Endoscopy Excellence Center, Department of Medicine, Faculty of Medicine, Chulalongkorn University and King Chulalongkorn Memorial Hospital, Thai Red Cross Society, 1873, Rama 4 Road, Pathumwan, Bangkok 10330, Thailand.

Phone: +66-2-2564356. Fax: +66-2-6524219

E-mail: kongkam@hotmail.com

considered to be one of the most aggressive cancers. The majority of pancreatic cancer cases consist of advanced-stage disease, with 5% of patients surviving longer than 5 years^(3,4). Complete surgical resection is currently the only curative treatment, given that only small pancreatic cancer tumors without major vessel involvement can be curatively treated, the detection of these small tumors is crucial for increasing pancreatic cancer survival rates.

In practice, computed tomography [CT] is the most commonly used imaging modality for identifying

How to cite this article: Kongkam P, Jaruvongvanich V, Ave K, Aniwana A, Amornsawadwattana S, Aso A, Shimizu S, Kullavanijaya P, Rerknimitr R. Multi-detector computed tomography versus endoscopic ultrasonography for the detection of pancreatic cancer. J Med Assoc Thai 2018;101;Suppl.4:S59-S65.

pancreatic cancer. Nevertheless, endoscopic ultrasound [EUS] has been increasingly used worldwide in the detection, staging and diagnosis of pancreatic cancer. The efficacy of both methods in the detection of pancreatic cancer has been compared in several studies. A systematic review of 11 studies concluded that EUS was superior to CT in detecting pancreatic cancer⁽⁵⁾, however, only one of these studies used multi-detector CT [MDCT] for detecting pancreatic cancer⁽⁶⁾. As has been established, MDCT has higher resolution than non-MDCT modalities in the evaluation of the pancreas, however, the majority of the available studies have compared non-MDCT modalities with EUS in the detection of pancreatic masses⁽⁷⁻¹⁴⁾. To the best of our knowledge, only 5 studies to date have compared the sensitivity of MDCT and EUS in detecting malignant pancreatic masses^(6,15-18). Additionally, there have only been 3 studies whose inclusion criteria included proven pancreatic cancer^(6,15,16). Given the fact that the number of previous studies is limited, it is of value to compare the efficacies of MDCT and EUS in identifying pancreatic cancer, which is the primary objective of our study.

Materials and Methods

In this retrospective study, we evaluated January 2009 to January 2014 data from the EUS database at King Chulalongkorn Memorial Hospital, Chulalongkorn University, Bangkok, Thailand. The inclusion criteria involved patients who underwent EUS for known or suspected pancreatic cancer with available MDCT results. Exclusion criteria were patients with a diagnosis of pancreatic neuroendocrine tumors [PNET], cystic pancreatic lesions, pathologically proven non-adenocarcinoma of the pancreas, a malignant pancreatic mass with unknown pathology and benign solid pancreatic lesions.

The baseline demographic data, clinical and imaging parameters of all eligible patients were collected from their electronic medical records and information previously entered in the EUS database. To simulate daily clinical practice, patients were not contacted for the purpose of this study. Images obtained using MDCT and EUS were not additionally reviewed, and the interpretation of all images was based on official reports regarding eligible patients. Data were analyzed using Excel and SPSS (version 16) programs. The results from MDCT examinations were compared with those from EUS. The diagnostic value was calculated. Related information concerning patients and the

features of their lesions were compared among the lesions detected and missed using MDCT.

MDCT examination

Multi-detector helical CT scanners (GE CT750 HD, GE Medical System, Milwaukee; WI, USA) are used in this current study with a 0.5-second gantry rotation time. All MDCTs were done in our hospital. Following is the standard procedure of CT in our institution.

Before the procedure, patients drink 350 mL of tap water as non-opaque oral intra-luminal contrast media. A total of 100 mL (300 mg iodine/mL of nonionic contrast media, Ultravist 300, Bayer Schering, Berlin; Germany) is injected by a power injector (CT Envision Injector, Medrad, Pittsburg, PA, USA) at the rate of 3 mL/second with a 20-gauge catheter. Each phase is obtained from the level of dome of diaphragm to both kidneys. Examination is performed in a dual-phase mode. SmartPrep monitoring scan (GE Healthcare, Milwaukee, WI, USA) is set up at mid-liver with the threshold of 100 Hounsfield units. The diagnostic delay time is 8-10 sec. The first phase is performed during the arterial phase (35 seconds after the start of contrast infusion) at 2.5 mm slice thickness using a 2.5 mm scanning collimation. Images are reconstructed at a 2.5 mm slice thickness. The second phase is obtained during the venous phase (70 seconds after the start of contrast infusion) 40 sec after finishing first phase.

The pancreatic protocol was done in some patients, especially with the suspicion of neuroendocrine tumor providing better evaluation. There is slight different from the dual-phase protocol. A 120 mL (350 mg iodine/mL) of nonionic contrast media (Omnipaque 350, GE Healthcare; USA) was used with the flow rate of 4 mL/second. The arterial phase is divided to early and late arterial phase which are obtained at 20 and 40 seconds after contrast injection. Other techniques are similar.

Image was transferred to a Picture Archiving and Communication System or PACS (Synapse, Fujifilm Medical Systems; USA). The images were interpreted by an on-service radiologist in the hospital at the time of the CT procedure. Analyzed data were obtained from the results detailed in online medical record official reports. Positive results of pancreatic lesions were diagnosed when a definite mass was identified and reported by radiologists. If official reports stated that an ill-defined or infiltrative lesion was identified, these were also registered as positive for pancreatic masses for the purpose of the present analysis. In this current

study, radiologist interpreted the MDCT images based on routinely provided clinical information as daily practice.

EUS examination

The EUS procedure was performed using either radial or linear probes by an experienced endosonographer (PK). In our center, we used either one of the echoendoscopes (EG-530UT2; FUJIFILM Corporation, Tokyo, Japan, GF-UCT140-AL5; Olympus Medical System Corp., Japan). When any hypoechoic masses were identified using EUS, this was classified as a positive result. Practically, if pathological diagnoses were not made from other pre-procedural studies, EUS-guided fine needle aspiration [EUS-FNA] was performed. Positive or suspicious results from EUS-FNA led to a diagnosis of pancreatic cancer. To obtain a pathological diagnosis, negative or inadequate EUS-FNA results that were highly suspected of malignancy warranted a repeated EUS-FNA procedure or the use of a different method, such as exploratory laparotomy or lymph node biopsy. Special immunohistochemical stains were used depending on the individual judgment of clinicians and pathologists. If adequate pathological diagnoses were still not possible, close follow-up was then undertaken. In patients with probable benign pancreatic lesions, adequate follow-up involving clinical information and imaging was mandatory regardless of positive or negative results from EUS-FNA.

Final diagnoses and follow-up

Diagnoses of pancreatic lesions were classified into benign, malignant, lesions of unknown cause, PNET and other specific cancers such as lymphoma. Malignant pancreatic lesions were definitively diagnosed when tissue pathology from surgery, core biopsy or cytopathology showed malignancy. Probable diagnosis of malignancy was made when progression of disease or lesions was demonstrated during a 12-month follow-up period. However, only pancreatic ductal adenocarcinoma that was confirmed by pathology was included for analysis. For benign second primary malignancies, diagnoses were made with the criteria of stable disease confirmed by clinical follow-up and serial cross-sectional imaging for at least 12 months, with or without benign cytological or histological pathology. For other diseases including PNET and non-adenocarcinoma of the pancreas, diagnoses were made based on the results of cytopathology or histopathology. Cystic lesions of the pancreas were diagnosed using imaging and

excluded from the present study as described in the aforementioned section.

The diameter of the lesions was determined from MDCT images. However, if these images were not available, the diameter was calculated from the maximal diameter obtained from EUS examination. The protocol of the study was written and approved by the Internal Review Body of Chulalongkorn University Hospital. No contact with patients was required during the study. Informed consent from all individual participants was waived as this current study was a retrospective one.

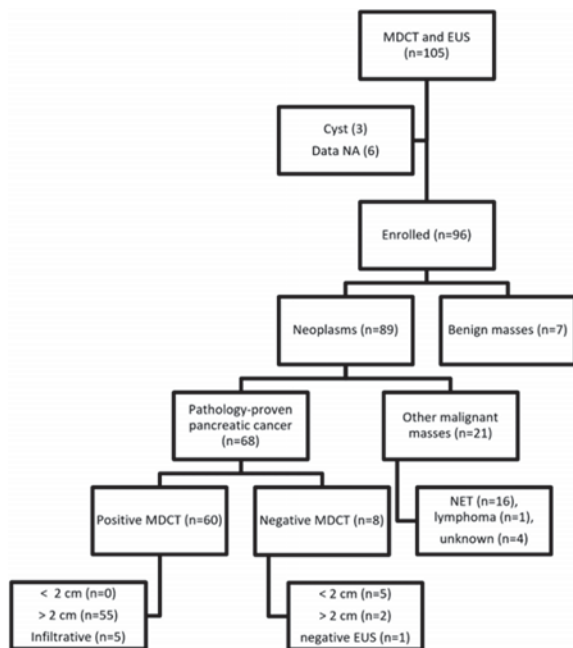
Statistical analysis

All data were collected from data sheets and subsequently transferred to Excel files (Microsoft 2007). Categorical variables presented as percentages were compared between both groups and analyzed using the Chi square or Fisher's exact test when appropriate. Continuous variables were calculated as the mean and standard deviation, and the independent T test was used for analysis. Statistical analysis was carried out using SPSS (version 16).

Results

From the EUS database, 105 patients were registered for EUS examination with indications of suspected or known pancreatic cancer. After initial review, 9 patients were excluded; 3 for reasons of cystic lesions in the pancreas and 6 because there were insufficient data for review. A total of 96 patients were recruited for the study. Seven were eventually diagnosed as having benign pancreatic lesions, with final diagnoses of mass-forming chronic pancreatitis ($n = 4$), autoimmune pancreatitis ($n = 2$) or another benign lesion that was stable for >12 months ($n = 1$). A total of 89 patients had malignant pancreatic neoplasms including PNET ($n = 16$), lymphoma ($n = 1$) or lesions of unknown pathology diagnosed by disease progression ($n = 4$), as shown in Figure 1. Finally, 68 patients (40 females and 28 males, mean age, 63.2 ± 10.9 years) were enrolled for analysis. All were pathology-proven pancreatic ductal adenocarcinoma, who presented with jaundice ($n = 31$), pain ($n = 35$), weight loss ($n = 15$) and incidental findings ($n = 3$). The baseline characteristics are detailed in Table 1.

The mean maximal diameters of the lesions that were identified ($n = 60$) or missed ($n = 8$) by using MDCT were 43.7 ± 15.6 mm (range 22 to 81 mm) and 18.4 ± 2.9 mm (range, 15 to 22 mm), respectively. Reasons for subsequent EUS despite negative MDCT were suspicious either symptoms or signs of pancreatic



EUS = endoscopic ultrasound; MDCT = multi-detector computer tomography; NA = not available; NET = neuroendocrine tumor

Fig. 1 Patient diagnosis flow diagram.

Table 1. Characteristics of the 68 patients with pancreatic cancer

Age (years), mean \pm SD	63.2 \pm 10.9
Gender (M:F)	28: 40
Clinical presentation, n (%)	
Jaundice	31 (45.6)
Pain	35 (51.5)
Weight loss	15 (22.1)
Incidental mass on MDCT	3 (4.4)
Tumor characteristics, n (%)	
Diameter (mm), mean \pm SD	40.9 \pm 16.7
Range (mm)	15 to 81
Diameter range (mm)	
Not detected	1 (1.5)
<20	5 (7.4)
21 to 30	11 (16.2)
>30	46 (67.6)
Infiltrative lesions	5 (7.4)

MDCT = multi-detector computed tomography; SD = standard deviation

cancer. Details concerning the 8 patients whose pancreatic cancer was missed using MDCT are

presented in Table 2. Nevertheless, only 1 from these 8 patients underwent MDCT with pancreatic protocol. From the 60 pancreatic cancers identified using MDCT, 5 were described as being infiltrative or ill-defined in the official report. The diagnoses of all of these 5 lesions were confirmed pathologically. Details of each case are given in Table 3.

The detection rate of EUS and MDCT in identifying pancreatic cancer was 98.5% (67/68) and 88.2% (60/68), respectively. Pancreatic cancer was missed using EUS in a 71-year-old man (patient number 8 in Table 2) who presented with obstructive jaundice from calcified chronic pancreatitis. Calcification was prominent in head of the pancreas. EUS-FNA was randomly performed in the head area of the pancreas with negative results. Two months later, peripancreatic and supraclavicular lymphadenopathy were identified. Biopsy specimen from the supraclavicular lymph node demonstrated metastatic adenocarcinoma.

Discussion

It is widely considered that EUS is more effective than non-MDCT in the identification of pancreatic cancer, which is one of the most aggressive cancers. However, it could be argued that given the higher diagnostic efficacy of the currently used MDCT, EUS might no longer be superior to MDCT. Few studies have attempted to clarify this issue. To the best of our knowledge, only 1 prospective study and 2 retrospective studies involved patients with pancreatic cancer as part of their inclusion criteria. Consequently, more studies are needed. This retrospective study aimed to address this requirement. Additionally, to simulate the daily practice of physicians who use both MDCT and EUS for the identification of pancreatic cancer and to prevent bias, we decided not to re-interpret the original results obtained using these 2 modalities in our analysis.

Findings from the current study confirmed the superior sensitivity of EUS relative to MDCT in the identification of pancreatic cancer. A prospective study by DeWitt et al reported that in 80 patients with pancreatic cancer, the sensitivity of EUS and MDCT were 98% and 86%, respectively⁽⁶⁾. A retrospective study carried out by Agarwal et al involving 71 patients with pancreatic cancer found that the sensitivities of EUS and MDCT were 100% and 86%, respectively⁽¹⁵⁾. In another study, Tamm et al conducted a retrospective analysis of 99 patients with suspected or known pancreatic cancer who had undergone both MDCT and EUS⁽¹⁶⁾. Ninety-five were pancreatic ductal

Table 2. Description of 8 patients whose pancreatic cancers were missed by multi-detector computed tomography

Case	Diameter (mm)	Location	Method of diagnosis	Operation	Pathology
1	15	Head/uncinate	Pathology	Whipple operation	Adenocarcinoma
2	16	Head	Pathology	Whipple operation	Adenocarcinoma
3	17	Head	Pathology	Whipple operation	Adenocarcinoma
4	17	Head	Pathology	Whipple operation	Adenocarcinoma
5	20	Head	Pathology	Whipple operation	Adenocarcinoma
6	22	Head/neck	Pathology	Whipple operation	Adenocarcinoma
7	22	Neck	Pathology	-	Adenocarcinoma (liver biopsy)
8	Not detected	Head	Pathology	-	Adenocarcinoma (lymph node)

Table 3. Description of 5 patients whose lesions were described using multi-detector computed tomography as either infiltrative or ill-defined lesions

Case	Location	Management	Pathology	EUS findings
1	Neck/body/tail	Pancreatectomy	Adenocarcinoma	Ill-defined large heterogenous hypoechoic pancreatic mass
2	Body/tail	Systemic therapy	Adenocarcinoma (gastric biopsy)	Heterogenous hypoechoic mass with antral gastric wall invasion
3	Uncinate	Systemic therapy	Adenocarcinoma	Ill-defined heterogenous hypoechoic mass
4	Diffuse	Systemic therapy	Adenocarcinoma (liver biopsy)	Multiple liver masses, heterogeneous hypoechoic mass in entire pancreas
5	Head	Systemic therapy	Adenocarcinoma (peritoneal biopsy)	Hypoechoic mass in the pancreas

adenocarcinoma and the sensitivity of EUS and MDCT were 99% and 93%, respectively⁽¹⁶⁾. After an extensive search of the PubMed database, we were only able to identify the above 3 studies, which had similar population characteristics that we could compare with our study. In other studies, inclusion criteria were not comparable with ours. Combining the findings of these 3 studies with those of the present study, we concluded that EUS is still more sensitive than MDCT in the identification of pancreatic cancer, and that current MDCT cannot totally exclude patients with a suspicion of pancreatic cancer. One might argue that this might be a weakness of the current study as if radiologist was informed before reviewing all images, results of MDCT might be more accurate. Nevertheless, as mentioned, we aimed to simulate the real practical

situation, we hence decided not to do second-round review of all images again.

There have been other studies that included patients with known or suspected pancreatic masses but that have not taken into consideration the benign or malignant nature of the mass. These studies were considered not to be comparable with our study because the inclusion criteria were different. Arabul et al carried out a prospective study involving 51 patients who had pancreatic masses with various diagnoses, e.g. pancreatic ductal adenocarcinoma, neuroendocrine tumors, and various benign lesions⁽¹⁷⁾. These authors concluded that there was a significant correlation between the sensitivities of EUS and MDCT⁽¹⁸⁾. Another retrospective study by Deerenberg et al involving 290 patients with suspected or known

pancreatic masses reported that the sensitivity of EUS and MDCT were 98% and 89%, respectively. However, the authors focused on patients with negative MDCT results, and consequently information regarding the diagnosis of all recruited patients was not available for review⁽¹⁷⁾.

In the present study, none of the small pancreatic cancers <2 cm in diameter could be identified using MDCT. In addition, most of the pancreatic tumors missed using MDCT were <2 cm in diameter (75%). This corresponded with the results from 2 other studies. In a prospective study by DeWitt et al, 19 pancreatic cancers were reported to be <2 cm in diameter, and the sensitivities of EUS and MDCT were 89% and 47%, respectively⁽⁶⁾. A retrospective study by Tamm et al involving the analysis of 27 malignant pancreatic masses which were <2 cm in diameter reported that the sensitivity of EUS and MDCT were 96% and 83%, respectively⁽¹⁶⁾. Given the aforementioned results, EUS can be considered more sensitive in detecting small pancreatic cancers than MDCT. Regarding ill-defined, peripancreatic and pancreatic lesions that exact measurement of the target lesions could not be performed, all these lesions were classified as positive by MDCT (detail in Table 3). Pathological diagnosis in majority of cases was obtained from organs outside of the pancreas. Based on these available information, MDCT is good enough to catch up ill-defined target lesions in the pancreas and peripancreatic area as well as EUS.

In the present study, in one pancreatic cancer where the lesion could not be identified by EUS, the patient had calcified chronic pancreatitis in the entire pancreatic parenchyma. He initially presented with biliary stricture requiring biliary stent placement. Both EUS and MDCT could not detect any distinctive lesion in the baseline calcified pancreatic parenchyma. Subsequently, disease progression occurred and the patient had a metastatic supraclavicular lymph node proven by pathology. In fact, chronic pancreatitis is a well-known limitation for the detection of lesions in the parenchyma using EUS. A multicenter retrospective study carried out by Bhutani et al recruited 20 cases of pancreatic neoplasms that were missed by experienced endosonographers at several institutions. The results indicated that 12 of them had EUS features characteristic of chronic pancreatitis⁽¹⁹⁾. In addition, a study conducted by Deerenberg et al reported on 5 patients with pancreatic masses that had been missed using EUS; 2 had chronic pancreatitis, 1 had acute pancreatitis with PNET and 2 had pancreatic adenocarcinoma⁽¹⁷⁾.

This is why, in daily practice, some endosonographers might sample pancreatic tissue around the stricture site to survey possible pancreatic cancer. Unfortunately, despite this approach, the sensitivity of EUS-FNA in diagnosing pancreatic cancer in patients with chronic pancreatitis is still inferior to that in patients who do not have chronic pancreatitis, as demonstrated in 2 large studies^(20,21). These results underline the fact that the detection of malignant lesions in the pancreas involving calcified chronic parenchyma is still a challenging problem. A new modality with higher sensitivity is truly needed.

Conclusion

EUS has a higher sensitivity than MDCT in detecting pancreatic cancer, particularly in the case of small pancreatic tumors. However, EUS can miss pancreatic cancer in patients with calcified chronic pancreatitis.

What is already known on this topic?

CT has lower detection rate of pancreatic cancer than EUS, however, limited clinical studies have compared the rate between MDCT and EUS.

What this study adds?

EUS is still superior to MDCT for detection of pancreatic cancer particularly in pancreatic cancer smaller than 2 cm in diameter. Nevertheless, EUS can miss pancreatic cancer in a patient with baseline chronic pancreatitis.

Acknowledgement

This work was supported by JSPS Core-to-Core Program, B. Asia-Africa Science Platforms and was funded in part by Grant-in-Aid No. 23256005 for Scientific Research from the Japan Society for the Promotion of Science.

Potential conflicts of interest

None.

References

1. Maisonneuve P, Lowenfels AB. Epidemiology of pancreatic cancer: an update. *Dig Dis* 2010; 28: 645-56.
2. Cascinu S, Falconi M, Valentini V, Jelic S. Pancreatic cancer: ESMO Clinical Practice Guidelines for diagnosis, treatment and follow-up. *Ann Oncol* 2010; 21 (Suppl 5): v55-8.
3. Eshuis WJ, van der Gaag NA, Rauws EA, van Eijck

- CH, Bruno MJ, Kuipers EJ, et al. Therapeutic delay and survival after surgery for cancer of the pancreatic head with or without preoperative biliary drainage. *Ann Surg* 2010; 252: 840-9.
4. Kongkam P, Benjasupattananun P, Taytawat P, Navicharoen P, Sriuranpong V, Vajragupta L, et al. Pancreatic cancer in an Asian population. *Endosc Ultrasound* 2015; 4: 56-62.
 5. Dewitt J, Devereaux BM, Lehman GA, Sherman S, Imperiale TF. Comparison of endoscopic ultrasound and computed tomography for the preoperative evaluation of pancreatic cancer: a systematic review. *Clin Gastroenterol Hepatol* 2006; 4: 717-25.
 6. Dewitt J, Devereaux B, Chriswell M, McGreevy K, Howard T, Imperiale TF, et al. Comparison of endoscopic ultrasonography and multidetector computed tomography for detecting and staging pancreatic cancer. *Ann Intern Med* 2004; 141: 753-63.
 7. Palazzo L, Roseau G, Gayet B, Vilgrain V, Belghiti J, Fekete F, et al. Endoscopic ultrasonography in the diagnosis and staging of pancreatic adenocarcinoma. Results of a prospective study with comparison to ultrasonography and CT scan. *Endoscopy* 1993; 25: 143-50.
 8. Yasuda K, Mukai H, Nakajima M, Kawai K. Staging of pancreatic carcinoma by endoscopic ultrasonography. *Endoscopy* 1993; 25: 151-5.
 9. Muller MF, Meyenberger C, Bertschinger P, Schaer R, Marincek B. Pancreatic tumors: evaluation with endoscopic US, CT, and MR imaging. *Radiology* 1994; 190: 745-51.
 10. Nakaizumi A, Uehara H, Iishi H, Tatsuta M, Kitamura T, Kuroda C, et al. Endoscopic ultrasonography in diagnosis and staging of pancreatic cancer. *Dig Dis Sci* 1995; 40: 696-700.
 11. Sugiyama M, Hagi H, Atomi Y, Saito M. Diagnosis of portal venous invasion by pancreatobiliary carcinoma: value of endoscopic ultrasonography. *Abdom Imaging* 1997; 22: 434-8.
 12. Gress FG, Hawes RH, Savides TJ, Ikenberry SO, Cummings O, Kopecky K, et al. Role of EUS in the preoperative staging of pancreatic cancer: a large single-center experience. *Gastrointest Endosc* 1999; 50: 786-91.
 13. Harrison JL, Millikan KW, Prinz RA, Zaidi S. Endoscopic ultrasound for diagnosis and staging of pancreatic tumors. *Am Surg* 1999; 65: 659-64; discussion 664-5.
 14. Mertz HR, Sechopoulos P, Delbeke D, Leach SD. EUS, PET, and CT scanning for evaluation of pancreatic adenocarcinoma. *Gastrointest Endosc* 2000; 52: 367-71.
 15. Agarwal B, Abu-Hamda E, Molke KL, Correa AM, Ho L. Endoscopic ultrasound-guided fine needle aspiration and multidetector spiral CT in the diagnosis of pancreatic cancer. *Am J Gastroenterol* 2004; 99: 844-50.
 16. Tamm EP, Loyer EM, Faria SC, Evans DB, Wolff RA, Charnsangavej C. Retrospective analysis of dual-phase MDCT and follow-up EUS/EUS-FNA in the diagnosis of pancreatic cancer. *Abdom Imaging* 2007; 32: 660-7.
 17. Deerenberg EB, Poley JW, Hermans JJ, Ganesh S, van der HE, van Eijck CH. Role of endoscopic ultrasonography in patients suspected of pancreatic cancer with negative helical MDCT scan. *Dig Surg* 2011; 28: 398-403.
 18. Arabul M, Karakus F, Alper E, Kandemir A, Celik M, Karakus V, et al. Comparison of multidetector CT and endoscopic ultrasonography in malignant pancreatic mass lesions. *Hepatogastroenterology* 2012; 59: 1599-603.
 19. Bhutani MS, Gress FG, Giovannini M, Erickson RA, Catalano MF, Chak A, et al. The No Endosonographic Detection of Tumor (NEST) study: a case series of pancreatic cancers missed on endoscopic ultrasonography. *Endoscopy* 2004; 36: 385-9.
 20. Varadarajulu S, Tamhane A, Eloubeidi MA. Yield of EUS-guided FNA of pancreatic masses in the presence or the absence of chronic pancreatitis. *Gastrointest Endosc* 2005; 62: 728-36.
 21. Fritscher-Ravens A, Brand L, Knofel WT, Bobrowski C, Topalidis T, Thonke F, et al. Comparison of endoscopic ultrasound-guided fine needle aspiration for focal pancreatic lesions in patients with normal parenchyma and chronic pancreatitis. *Am J Gastroenterol* 2002; 97: 2768-75.