

# A Cross-Sectional with Retrospective Review of Chronic Actinic Dermatitis: A Rare Photodermatosis in Thailand

Alita Sombatmaithai MD<sup>1</sup>, Narumol Silpa-archa MD<sup>1</sup>, Chanisada Wongpraparut MD<sup>1</sup>

<sup>1</sup> Department of Dermatology, Faculty of Medicine Siriraj Hospital, Mahidol University, Bangkok, Thailand

**Background:** Chronic actinic dermatitis [CAD] is an idiopathic photodermatosis that has been reported worldwide and occurs mainly in elderly men with a history of chronic exposure to sunlight.

**Objective:** To investigate the clinical characteristics, photobiological characteristics, and treatment outcomes of CAD patients in Thailand.

**Materials and Methods:** The present study was cross-sectional retrospective chart review conducted in patients that underwent phototesting at the Photodermatology clinic of Siriraj Hospital between 1997 and 2013. Data were collected from patient medical records and follow-up telephone interviews. Complete response was defined as 100% clinical improvement, and partial response was defined as 25% to 99% clinical improvement.

**Results:** Forty-five patients were included, of which 39 (86%) were male and six (14%) were female. The mean age was 57.5 (range 28 to 84) years. More than half of patients (51%) had decreased minimal erythema dose [MED] to both ultraviolet [UV] A and UVB, while 18 patients (40%) had decreased MED to UVB alone and four patients (9%) had decreased MED to UVA alone. Eleven patients (24%) had extensive skin involvement beyond the sun-exposed area. All patients showed some degree of clinical improvement after initiation of photoprotection and medical treatment. Analysis of clinical course was available in 35 patients, with a mean  $\pm$  standard deviation follow-up duration of 24.5 (range 1 to 72) months. Six patients (17%) achieved complete response and 29 patients (83%) showed partial response to treatment. In the complete response group, the mean duration of disease was 19.67 $\pm$ 15.15 (range 3 to 40) months and no systemic medication was required. Systemic corticosteroids and/or immunosuppressants were required in severe patients, particularly in patients who had exfoliative dermatitis or leonine facies. In patients with recalcitrant facial lesions, 0.1% tacrolimus ointment showed a promising response.

**Conclusion:** CAD had a chronic course in the present study and only a minority of patients achieved complete response. In severe cases, lesions demonstrated a tendency to spread beyond the sun-exposed areas. UVA and UVB were the most common action spectra. In patients with recalcitrant disease, 0.1% tacrolimus ointment should be considered, especially in patients with facial lesions.

**Keywords:** Chronic actinic dermatitis, Photodermatosis, Photosensitivity, Thailand

**J Med Assoc Thai 2018; 101 (1): 119-25**

**Website:** <http://www.jmatonline.com>

Chronic actinic dermatitis [CAD] is an idiopathic photodermatosis that was previously referred to as actinic reticuloid<sup>(1)</sup>. This condition mostly affects elderly males with a history of chronic exposure to sunlight. CAD has been reported worldwide<sup>(2-5)</sup>. A 2006 Chinese study reported the prevalence of CAD in four regions at different altitudes of 0.0018% (9/4,899)<sup>(6)</sup>. A Singaporean study reported CAD prevalence of 15.3% in all tested photosensitive dermatosis patients<sup>(7)</sup>. Clinically, CAD presents as pruritic eczematous plaques on sun-exposed areas

covering the face, ears, posterior neck, upper chest, and dorsum of forearms and hands. In severe cases, lesions can be found on sun-protected areas, but to a lesser extent than observed on sun-exposed areas. Causative action spectrum in CAD can be ultraviolet [UV] B, UVA, and visible light; however, combined UVB and UVA were found to be the most common action spectra<sup>(8,9)</sup>. CAD can be associated with contact allergy to airborne plant allergens (Compositae oleoresins) by exposure from gardening<sup>(10)</sup>. The pathogenesis of CAD involves delayed-type hypersensitivity reaction against endogenous sunlight-induced epidermal antigens<sup>(11-14)</sup>. The management of CAD is challenging, with the initiation of strict photoprotection combined with topical/systemic corticosteroids and/or immunosuppressants as a first-line treatment. The aim of

### Correspondence to:

Wongpraparut C. Department of Dermatology, Faculty of Medicine Siriraj Hospital, Mahidol University, 2 Wang Lang Road, Bangkokknoi, Bangkok 10700, Thailand.

**Phone:** +66-2-4194318, **Fax:** +66-2-4115031

**Email:** chanisada@hotmail.com

**How to cite this article:** Sombatmaithai A, Silpa-archa N, Wongpraparut C. A cross-sectional with retrospective review of chronic actinic dermatitis: a rare photodermatosis in Thailand. J Med Assoc Thai 2018;101:119-25.

the present study was to investigate the clinical characteristics, photobiological characteristics, and treatment outcomes of CAD patients in Siriraj Hospital, Thailand.

## Materials and Methods

The present study was cross-sectional retrospective chart review conducted in 45 CAD patients that underwent phototesting at the Photodermatology clinic, Department of Dermatology, Faculty of Medicine Siriraj Hospital, Mahidol University between 1997 and 2013. Siriraj Hospital is Thailand's largest national tertiary referral center. Diagnosis of CAD was based on clinical manifestation of photodistributed pruritic eczematous eruption and abnormal phototesting resulted in decreased minimal erythema dose [MED] for UVB and/or UVA. Collected data included demographic characteristics, outdoor habits and tendencies, clinical manifestations, laboratory investigations (anti-nuclear antibody, anti-HIV, and porphyrin analysis) to exclude other causes of photodermatosis, phototesting, patch testing, and photopatch testing results, treatments, and clinical outcome. In patients who, for whatever reason, continued follow-up at our clinic, telephone contact was used to gather information regarding clinical course during the follow-up period. The protocol for the present study was approved by the Siriraj Institutional Review Board [SIRB]. Verbal informed consents were obtained from all participants who were successfully contacted and from whom follow-up data were collected.

### Phototesting

MED testing for UVA and UVB was performed on the lower back, which is considered to be a sun-protected area. For UVA irradiation, polychromatic UVA (UVASUN 3000; Mützhals Productions GmbH, Munich, Germany) of 5 to 30 J/cm<sup>2</sup> was administered between 1997 and 2010. Between 2011 and 2013, a Dualight (Thera-Light, Inc., Carlsbad, CA, USA) was used, which is a high-pressure mercury lamp capable of emitting UVA. For UVB irradiation, polychromatic UVB (UV800, Walmann, Villingen-Schwenningen, Germany) of 50 to 280 mJ/cm<sup>2</sup> was administered during all years of the study period. MED was defined as the dose that produced perceptible erythema at 24 hours after irradiation. Abnormal MED was determined for both UVA and UVB from reference level/range data established from previous phototesting in Thai population, with normal MED to UVA considered to be 50 J/cm<sup>2</sup> and normal MED to UVB considered to

be 60 mJ/cm<sup>2</sup>(15). Monochromatic phototesting was not available at our center during the study period.

### Phototesting, patch testing, and photopatch testing

In cases of suspected photoallergic contact dermatitis, patch and photopatch testing were performed. For patch testing, "Siriraj Standard Series" [SiSS] screening series, which was modified from the European baseline series and the International standard series, was performed by placing aluminum Finn Chambers® (SmartPractice, Phoenix, AZ, USA) on unaffected skin for 48 hours(16). Reaction for erythematous papules was interpreted at 48 and 96 hours. Allergic contact dermatitis was diagnosed if patients had positive patch test reaction with clinical relevance.

Photopatch testing using screening series "Siriraj Photoallergens Series" (modified SP-1000 + SU-1000) was performed by placing two duplicated panels on the upper back. One panel was uncovered at 48 hours and irradiated with the lower of either of UVA 10 J/cm<sup>2</sup> or 50% of MED-UVA. Results were evaluated at 48 and 96 hours and were considered positive when erythematous papules were present at the irradiated site. Photoallergic contact dermatitis was then diagnosed. For phototesting, patch testing, and photopatch testing, systemic corticosteroids were avoided for at least two weeks prior to testing.

Clinical outcome of CAD treatment was defined using the method described in the study by Wolverton et al(3). Complete response was defined as 100% clinical improvement, and partial response was defined as 25% to 99% clinical improvement. No response was defined as clinical improvement less than 25%, no change was defined as no change in the clinical status of CAD, and worsened described as a worsening of clinical features.

### Statistical analysis

Demographic data, clinical and photobiological characteristics, patch testing, and photopatch testing are described as number, number and percentage (%), or mean and range. Data analysis was performed using SPSS Statistics version 18 (SPSS Inc., Chicago, IL, USA).

## Results

During the 17-year study period, 45 patients were diagnosed with CAD. The mean age of onset was 57.5 years (range 28 to 84). Thirty-nine patients (86%) were male and six (14%) were female. Twenty-seven patients (60%) had skin phototype [SPT] IV, while 12 patients (27%) and six patients (13%) had SPT V and III, respectively. The most common location of CAD was

face (82%), followed by forearm (78%), and V-shape of neck (73%). Eleven patients (24.4%) developed eczematous lesions on both sun-exposed and sun-protected areas. One case had erythrodermic manifestation and another case had leonine facies. It was noted that that 35% patients had history of chronic sun exposure due to outdoor activity lifestyle. One middle-aged male who had HIV infection receiving anti-retroviral therapy presented with widespread eruption on sun-exposed areas.

Phototesting was performed in all patients. Twenty-three patients (51%) had decreased MED to both UVA and UVB, 18 patients (40%) had low MED to UVB alone, and four patients (9%) had low MED to UVA alone. Patch testing was performed in eight patients (18%), with positive result and positive clinical relevance in four cases. The positive allergens were fragrance mix I, coal tar dye, p-phenylenediamine, and potassium dichromate. Photopatch testing was performed in five patients, all of which showed negative results.

All CAD patients were advised to enforce strict photoprotection by seeking shade at peak UV hours (10 am to 4 pm), and using fabric photoprotection and wearing broad-spectrum sunscreen of SPF 30 or higher when exposed to sunlight. Topical corticosteroids were the initial prescribed medication in every case. Five patients (11%) with hyperkeratotic lesions who were unresponsive to topical corticosteroids required topical keratolytic agents. Five cases had recalcitrant facial lesions and 0.1% tacrolimus ointment was prescribed twice daily with excellent response (Figure 1). However, one case that applied 0.1% tacrolimus on the forearms showed only partial response. Eighteen patients (40%) received systemic corticosteroids. Seven of these 18 patients received additional immunosuppressants, including azathioprine (5), cyclosporine (1), and chloroquine (1).

Analysis for clinical treatment outcome was performed in 35 patients. Mean duration of follow-up was 24.5 months (range 1 to 72). Six patients (17%) achieved complete response, while 29 patients (83%)

had only partial response to treatment. For the complete response group, mean duration of disease was  $19.7 \pm 15.10$  months and no systemic medication was required in these patients. All patients required systemic therapies had only partial response to treatment.

## Discussion

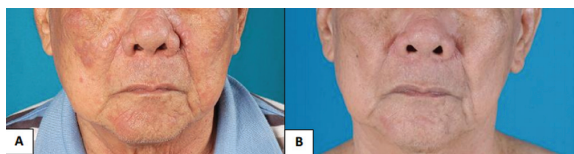
This study presented data of all CAD cases over 17-year period at a university-based national tertiary care center in Thailand. We found male gender predominance with a male to female ratio of 6.5:1, which is higher than gender ratios reported from other countries (Table 1)<sup>(4,5,9,17,18)</sup>. This may reflect a higher frequency of outdoor activity and inadequate photoprotection among males in Thailand. CAD can occur in all races and SPTs; however, type IV was the dominant SPT in the present study, which is similar to results from other studies in Asian populations<sup>(5-7)</sup>.

Most CAD patients presented with eczematous lesions on sun-exposed areas. However, and in this study, 11 patients (24.4%) also had rash on non-exposed areas. This is similar to other studies that reported eczematous rash on sun-protected areas<sup>(19-21)</sup>, even on palms and soles<sup>(19)</sup>. Moreover, we found that one patient had erythrodermic features and another had Leonine facies. It might be assumed that these patients having lesions on cover areas or presented with erythroderma or extensive lesion on facial area could be the severity marker of this condition.

A majority of patients in the present study had decreased MED to both UVB and UVA, which is similar to results from previous reports (Table 1). In addition to UV radiation, visible light [VL] was also found to influence this condition<sup>(9,21)</sup>. Accordingly, VL testing should be considered in cases of negative UVB and UVA testing.

Allergic contact dermatitis might be one of the factors that contributes to the pathogenesis of CAD. Compositae oleoresins, fragrances, sunscreen, and pesticides are the most common allergens reported from positive patch testing<sup>(10,11)</sup>. In our study, patch tests were performed in only eight patients suspected of having allergic contact dermatitis. Four of eight patients (50%) had positive patch testing results. Our 50% positive finding was lower than in previous studies<sup>(4,11,22)</sup>. As a result of the small number of the subjects in our study, we could not compare our data with the data from previous reports<sup>(11-13)</sup>.

Strict photoprotection is the mainstay treatment in CAD. Topical corticosteroids, as a first-line medical



**Figure 1.** Thai elderly male with chronic actinic dermatitis: (A) before 0.1% tacrolimus treatment, (B) after 0.1% tacrolimus treatment twice per day for 2 months.

treatment, were prescribed in all patients in the present study. Topical tacrolimus was another alternative that showed promising results in CAD<sup>(23,24)</sup>. A summary of CAD treated with tacrolimus ointment was shown in Table 2<sup>(23-26)</sup>.

Six patients with thin eczematous lesion unresponsive to topical corticosteroid or developed local side effects were treated with 0.1% tacrolimus ointment. Five of six patients (83%) had excellent response to treatment and all six patients had lesion on facial areas. These results were similar to those reported in the study from Japan that described very good response to 0.1% tacrolimus on facial lesions in CAD<sup>(25)</sup>. Topical calcineurin inhibitor can suppress

both T cells and inflammatory cytokines, such as interleukin-2 and tumor necrotic factor, which may be involved in the pathogenesis of CAD<sup>(27)</sup>.

Systemic corticosteroids, azathioprine, cyclosporine, and mycophenolate mofetil, were shown to be effective immunosuppressants in CAD<sup>(27-30)</sup>. Azathioprine was the steroid-sparing agent most commonly used in the present study. All patients who were insufficiently responsive to azathioprine were given systemic corticosteroid. One patient required an additional immunosuppressant (cyclosporine), which yielded only partial response.

Only six patients achieved complete response in the present study, while a majority of patients (83%)

**Table 1.** Demographic data and phototest results of chronic actinic dermatitis patients from different countries

Category	Lim et al <sup>(4)</sup>	Yap et al <sup>(9)</sup>	Kyu-Won et al <sup>(17)</sup>	Tan et al <sup>(5)</sup>	Que et al <sup>(18)</sup>	The present study
Country (year)	United States-Japan (1994)	Australia (2003)	Korea (2009)	Singapore (2011)	United States (2011)	Thailand (2016)
Number of cases	51	44	51	58	40	45
Study period (years)	USA 8, Japan 10	8.3	18	5	25	17
Age of onset (years), mean (range)	62.7 (27 to 85)	62.7 (26 to 85)	59.2 (43 to 71)	62 (35 to 83)	57.8 (N/A)	57.5 (28 to 84)
Male:female ratio	2.6:1	5.3:1	4.7:1	4.2:1	2.1:1	6.5:1
Reduced MED, n (%)						
UVB and UVA	33 (65.0)	31 (73.8)	32 (62.7)	32 (55.2)	32 (80.0)	23 (51.0)
UVB	1 (1.9)	4 (9.5)	16 (31.4)	23 (39.7)	1 (2.5)	18 (40.0)
UVA	14 (27.0)	6 (14.3)	2 (3.9)	3 (5.1)	7 (17.5)	4 (9.0)
UVA, UVB, and visible light	2 (3.9)	1 (2.3)	5 (9.8)	-	-	-
Visible light	1 (1.9)	-	-	-	-	-
Patch test, n (%)	12/44 positive (27.0)	24/33 positive (73.0)	35/51 positive (68.6)	-	12/18 positive (66.7)	4/8 positive (50.0)
Photo patch test, n (%)	16/48 positive (33.0)	9/33 positive (27.0)	41/51 positive (80.4)	0/1 positive (0.0)	17/30 positive (56.7)	0/5 positive (0.0)
HIV positive, n	N/A	N/A	N/A	3	1	1

N/A = not available; MED = minimal erythema dose; UV = ultraviolet; HIV = human immunodeficiency virus

**Table 2.** Studies in chronic actinic dermatitis treated with topical tacrolimus

Literature	Total cases	Area	Previous treatment	Results	Adverse effect
Uetsu et al <sup>(25)</sup> , 2002	6	Face and neck	Topical corticosteroids, sunscreen, and oral antihistamine	Marked improvement in 4 weeks	Local irritation
Gröne et al <sup>(23)</sup> , 2006	1	Face and neck	Topical and systemic corticosteroids, cyclosporine, and sunscreen	Effective in treating nodular lesion on face and neck	None
Ma and Lu <sup>(26)</sup> , 2010	40	Sun-exposed area	N/A	At 4 weeks, 2 cases (5%) had clinical cure and 23 cases (57.5%) had excellent results CD1a, CD11b, and CCR7 expression was significantly reduced after treatment.	Erythema pruritus
Busaracome et al <sup>(24)</sup> , 2011	1	Face	Oral corticosteroids	Effective in treating Leonine facies after 4 months	N/A
The present study, 2016	6	Face and forearm	Topical and systemic corticosteroids, sunscreen, and oral antihistamine	Five cases had excellent results on facial area after a mean time of 1 month	Local irritation

N/A = not available

achieved partial response. Dawe et al followed 178 patients up to 24 years from diagnosis and found that CAD generally persisted for a number of years before gradual resolution<sup>(31)</sup>. The probability of abnormal photosensitivity resolving by 10 years after diagnosis was reported to be 20%<sup>(31)</sup>. Differences in clinical outcomes between our study and other studies might be explained by variations in the definition of clinical response and variations among ethnic groups.

In conclusion, CAD had a chronic course in the present study and only a minority of patients achieved complete response. In severe cases, lesions demonstrated a tendency to spread beyond the sun-exposed areas. UVA and UVB were the most common action spectra. In patients with recalcitrant disease, 0.1% tacrolimus ointment should be considered, especially in patients with facial lesions.

### What is already known on this topic?

CAD is an idiopathic photodermatosis that has been reported worldwide and occurs mainly in elderly men with a history of chronic exposure to sunlight.

### What this study adds?

The clinical course of CAD is chronic and only a minority of the patients achieved complete response. UVA and UVB are the two most common action spectra in Thai CAD patients. Tacrolimus ointment should be considered in patients with recalcitrant disease, especially those with facial lesions.

### Acknowledgement

The authors gratefully acknowledge Miss Julaporn Pooliam, MSc of the Clinical Epidemiology Unit, Office for Research and Development, Faculty of Medicine Siriraj Hospital, Mahidol University for assistance with statistical analysis.

### Potential conflicts of interest

None.

### References

1. Frain-Bell W, Lakshmipathi T, Rogers J, Willock J. The syndrome of chronic photosensitivity dermatitis and actinic reticuloid. *Br J Dermatol* 1974;91:617-34.
2. Roelandts R. Chronic actinic dermatitis. *J Am Acad Dermatol* 1993;28:240-9.
3. Wolverson JE, Soter NA, Cohen DE. The natural history of chronic actinic dermatitis: an analysis at a single institution in the United States. *Dermatitis* 2014;25:27-31.
4. Lim HW, Morison WL, Kamide R, Buchness MR, Harris R, Soter NA. Chronic actinic dermatitis. An analysis of 51 patients evaluated in the United States and Japan. *Arch Dermatol* 1994;130:1284-9.
5. Tan AW, Lim KS, Theng C, Chong WS. Chronic actinic dermatitis in Asian skin: a Singaporean experience. *Photodermatol Photoimmunol Photomed* 2011;27:172-5.
6. Deng D, Hang Y, Chen H, Li H. Prevalence of photodermatosis in four regions at different altitudes in Yunnan province, China. *J Dermatol* 2006;33:537-40.
7. Wong SN, Khoo LS. Analysis of photodermatoses seen in a predominantly Asian population at a photodermatology clinic in Singapore. *Photodermatol Photoimmunol Photomed* 2005;21:40-4.
8. Menagé HD, Harrison GI, Potten CS, Young AR, Hawk JL. The action spectrum for induction of chronic actinic dermatitis is similar to that for sunburn inflammation. *Photochem Photobiol* 1995;62:976-9.
9. Yap LM, Foley P, Crouch R, Baker C. Chronic actinic dermatitis: a retrospective analysis of 44 cases referred to an Australian photobiology clinic. *Australas J Dermatol* 2003;44:256-62.
10. Lim HW, Cohen D, Soter NA. Chronic actinic dermatitis: results of patch and photopatch tests with Compositae, fragrances, and pesticides. *J Am Acad Dermatol* 1998;38:108-11.
11. Chew AL, Bashir SJ, Hawk JL, Palmer R, White IR, McFadden JP. Contact and photocontact sensitization in chronic actinic dermatitis: a changing picture. *Contact Dermatitis* 2010;62:42-6.
12. Dawe RS, Green CM, MacLeod TM, Ferguson J. Daisy, dandelion and thistle contact allergy in the photosensitivity dermatitis and actinic reticuloid syndrome. *Contact Dermatitis* 1996;35:109-10.
13. Menagé H, Ross JS, Norris PG, Hawk JL, White IR. Contact and photocontact sensitization in chronic actinic dermatitis: sesquiterpene lactone mix is an important allergen. *Br J Dermatol* 1995;132:543-7.
14. Murphy GH, White IR, Hawk JL. Allergic airborne contact dermatitis to Compositae with photosensitivity--chronic actinic dermatitis in evolution. *Photodermatol Photoimmunol Photomed* 1990;7:38-9.
15. Rajatanavin N, Tanyasithisunthorn P, Kitchawengkul O, Charuwijitratana S, Polnikorn N.

- Predictive value of skin type for minimal erythematous dose in Thai people. *Ramathibodi Med J* 1992;15:292-5.
16. Boonchai W, Kasemsarn P. Suitability of patch test allergens for standard series in Thai patients: ten-year retrospective review of patch test results. *J Dermatol* 2013;40:65-7.
  17. Kyu-Won C, Chae-Young L, Yeong-Kyu L, Young-Hun K, Ki-Ho K. A Korean experience with chronic actinic dermatitis during an 18-year period: meteorological and photoimmunological aspects. *Photodermatol Photoimmunol Photomed* 2009;25:286-92.
  18. Que SK, Brauer JA, Soter NA, Cohen DE. Chronic actinic dermatitis: an analysis at a single institution over 25 years. *Dermatitis* 2011;22:147-54.
  19. Somani VK. Chronic actinic dermatitis--a study of clinical features. *Indian J Dermatol Venereol Leprol* 2005;71:409-13.
  20. Sidiropoulos M, Deonizio J, Martinez-Escala ME, Gerami P, Guitart J. Chronic actinic dermatitis/actinic reticuloid: a clinicopathologic and immunohistochemical analysis of 37 cases. *Am J Dermatopathol* 2014;36:875-81.
  21. Healy E, Rogers S. Photosensitivity dermatitis/actinic reticuloid syndrome in an Irish population: a review and some unusual features. *Acta Derm Venereol* 1995;75:72-4.
  22. Que SK, Brauer JA, Soter NA, Cohen DE. Normal minimal erythema dose responses in patients with suspected photosensitivity disorders. *Photodermatol Photoimmunol Photomed* 2012;28:320-1.
  23. Gröne D, Kunz M, Zimmermann R, Gross G. Successful treatment of nodular actinic reticuloid with tacrolimus ointment. *Dermatology* 2006;212:377-80.
  24. Busaracome P, Wattanakrai P, Rajatanavin N. Chronic actinic dermatitis with leonine facies and iatrogenic adrenal insufficiency successfully treated with topical tacrolimus. *Case Rep Dermatol* 2011;3:49-54.
  25. Uetsu N, Okamoto H, Fujii K, Doi R, Horio T. Treatment of chronic actinic dermatitis with tacrolimus ointment. *J Am Acad Dermatol* 2002;47:881-4.
  26. Ma Y, Lu Z. Treatment with topical tacrolimus favors chronic actinic dermatitis: a clinical and immunopathological study. *J Dermatolog Treat* 2010;21:171-7.
  27. Zabawski EJ, Costner M, Cohen JB, Cockerell CJ. Tacrolimus: pharmacology and therapeutic uses in dermatology. *Int J Dermatol* 2000;39:721-7.
  28. Leigh IM, Hawk JL. Treatment of chronic actinic dermatitis with azathioprine. *Br J Dermatol* 1984;110:691-5.
  29. Dawe RS, Ferguson J. Diagnosis and treatment of chronic actinic dermatitis. *Dermatol Ther* 2003;16:45-51.
  30. Weidgang K, Diesler S, Krieg T, Hunzelmann N. Treatment of chronic actinic dermatitis with mycophenolate mofetil. *J Dtsch Dermatol Ges* 2005;3:702-4.
  31. Dawe RS, Crombie IK, Ferguson J. The natural history of chronic actinic dermatitis. *Arch Dermatol* 2000;136:1215-20.

---

การศึกษา ณ จุดใดจุดหนึ่งแบบตัดขวางร่วมกับการศึกษาย้อนหลังในโรคผื่นผิวหนังอักเสบเรื้อรังจากแสงแดด (chronic actinic dermatitis) ซึ่งเป็นโรคที่พบบ่อยในประเทศไทย

อลิตา สมบัติไหมไทย, นฤมล ศิลปอาษา, ชนิษฐา วงษ์ประภารัตน์

**ภูมิหลัง:** โรคผื่นผิวหนังอักเสบเรื้อรังจากแสงแดด เป็นโรคแพ้แสงที่ไม่ทราบสาเหตุชนิดหนึ่ง มีรายงานการพบได้ทั่วโลก และพบบ่อยในผู้ชายสูงอายุที่มีประวัติได้รับแสงแดดเป็นเวลานาน

**วัตถุประสงค์:** เพื่อศึกษาลักษณะทางคลินิก ลักษณะความผิดปกติต่อแสง และผลการรักษาของโรคผื่นผิวหนังอักเสบเรื้อรังจากแสงแดดในประเทศไทย

**วัสดุและวิธีการ:** การศึกษาย้อนหลังนี้รวบรวมเอกสารทางการแพทย์ของผู้ป่วยที่มารับการทดสอบแสงที่คลินิกโรคผิวหนังกับแสงแดด โรงพยาบาลศิริราชระหว่างช่วง พ.ศ. 2540 ถึง 2556 ข้อมูลถูกรวบรวมจากแฟ้มเวชระเบียน และการสัมภาษณ์ผู้ป่วยทางโทรศัพท์

**ผลการศึกษา:** ผู้ป่วยทั้งหมด 45 ราย ที่ทำการศึกษา พบว่า 39 ราย (86%) เป็นผู้ป่วยเพศชาย และ 6 ราย (14%) เป็นเพศหญิง อายุเฉลี่ย คือ 57.5 ปี (28-84 ปี) มากกว่าครึ่งหนึ่งของผู้ป่วย (51%) มีการลดลงของค่า minimal erythema dose [MED] ทั้งรังสีอัลตราไวโอเลตชนิดเอ และรังสีอัลตราไวโอเลตชนิดบี ในขณะที่ 18 (40%) ของผู้ป่วยมีค่า MED ของรังสีอัลตราไวโอเลตชนิดบีลดลงเท่านั้น ผู้ป่วย 4 ราย (9%) มีการลดลงของค่า MED ของรังสีอัลตราไวโอเลตชนิดเอเพียงอย่างเดียว ผู้ป่วย 11 ราย (24%) มีผื่นผิวหนังอักเสบลามไปในบริเวณที่ไม่โดนแสงแดด พบว่าผู้ป่วยทุกรายมีอาการของโรคดีขึ้นหลังจากได้ทำการหลบเลี่ยงแสงแดดควบคู่ไปกับการรักษาด้วยยา การวิเคราะห์การดำเนินโรคได้ทำในผู้ป่วย 35 ราย พบว่ามีระยะเวลาที่ได้รับการรักษาโดยเฉลี่ย 24.5 เดือน (1-72 เดือน) ผู้ป่วย 6 ราย (17%) ตอบสนองต่อการรักษา 100% และผู้ป่วย 29 ราย (83%) ตอบสนองต่อการรักษาบางส่วน สำหรับกลุ่มที่ได้รับการตอบสนองต่อการรักษา 100% ระยะเวลาเฉลี่ยของการเป็นโรค คือ  $19.67 \pm 15.15$  เดือน (3-40 เดือน) และไม่ได้รับการรักษาด้วยยารับประทานหรือยาฉีดเข้าหลอดเลือดดำ ยาคอร์ติโคสเตียรอยด์ชนิดรับประทาน และ/หรือ ยาคุมกำเนิดจำเป็นต้องใช้ในผู้ป่วยที่มีอาการรุนแรง โดยเฉพาะอย่างยิ่งผู้ป่วยที่มีรอยโรคกระจายทั่วทั้งตัวหรือผื่นกระจายบนใบหน้าลักษณะคล้ายสังโต ในผู้ป่วยที่มีผื่นเรื้อรังหายากบริเวณใบหน้า การใช้ยาทาขี้ผึ้งทาโครลิมีสให้ผลการตอบสนองที่ดี

**สรุป:** โรคผื่นผิวหนังอักเสบเรื้อรังจากแสงแดดมีการดำเนินโรคที่เรื้อรัง และมีเพียงส่วนน้อยของผู้ป่วยเท่านั้นที่หายจากอาการของโรคทั้งหมด ในรายที่อาการรุนแรง รอยโรคมักจะมีแนวโน้มกระจายออกไปจากบริเวณที่โดนแสงแดด รังสีอัลตราไวโอเลตชนิดเอและรังสีอัลตราไวโอเลตชนิดบี พบบ่อยว่าเป็นสาเหตุของการเกิดโรคในผู้ป่วยที่มีผื่นเรื้อรังหายาก ยาทาขี้ผึ้งทาโครลิมีสเป็นตัวเลือกที่ควรพิจารณาโดยเฉพาะอย่างยิ่งบนใบหน้า