

Efficacy of Balloon Angioplasty to Correct Intra-graft Stenosis during the Surgical Revision of Thrombosed Dialysis Graft: A Prospective Randomized Controlled Trial

Supachai Chanvitan MD*, Suthas Horsirimanont MD*,
Sopon Jirasiritum MD*, Surasak Leela-Udomlipi MD*, Piyanut Pootracool MD*,
Nutsiri Kittitirapong MD*, Sakda Arj-Ong Vallibhakara MD, PhD**, Wiwat Tirapanich MD*

* Division of Vascular Surgery and Transplantation, Ramathibodi Hospital, Mahidol University, Bangkok, Thailand.

** Section for Clinical Epidemiology and Biostatistics, Ramathibodi Hospital, Mahidol University, Bangkok, Thailand

Objective: To compare between surgical revision with adjunctive balloon angioplasty on intra-graft stenosis (intervention group) and surgical revision alone (control group) in post-intervention primary patency rate, the efficacy of balloon angioplasty on intra-graft stenosis and incidence of intra-graft stenosis in thrombosed dialysis graft.

Material and Method: Between March 2016 and January 2017, All thrombosed dialysis graft patients at Ramathibodi Hospital were analyzed (n = 104). Grafts created less than 3 months or more than 2 years, a graft with infection, contrast allergy, and surgical revision more than twice were excluded. Forty-two patients were enrolled and randomly assigned to control and intervention group. All patients underwent surgical revision and intraoperative fistulography. Adjunctive balloon angioplasty was performed in the intervention group if intra-graft stenosis with 50% or greater luminal narrowing was detected. Patency rates were estimated by Kaplan-Meier survival analysis.

Results: The two groups exhibited similar demographic features and comorbidities ($p > 0.05$). A median follow-up time is 124 days (95% CI 126 to 291). No significant difference in overall post-intervention primary patency rate between the two groups ($p = 0.973$), at 3-month follow-up of control group [75% (95% CI 0.57 to 0.86)] and intervention group [78% (95% CI 0.61 to 0.88)]. And at 6-month follow-up of control group [62% (95% CI 0.43 to 0.76)] and intervention group [58% (95% CI 0.38 to 0.73)]. In subgroup analysis of patients who had intra-graft stenosis, the post-intervention primary patency rate of the intervention group was higher than in the control group ($p = 0.009$). At 3-month follow-up of control group [62% (95% CI 0.23 to 0.86)] and intervention group [87% (95% CI 0.38 to 0.98)]. And at 6-month follow-up of the control group [0%] and the intervention group [31% (95% CI 0.04 to 0.64)]. Anatomic success rate after balloon angioplasty was 100%. The incidence of intra-graft stenosis was 28.5% (12/42).

Conclusions: Incidence of intra-graft stenosis was 28.5% and could be effectively corrected by balloon angioplasty, therefore resulting in prolonged vascular access function.

Keywords: Thrombosed grafts, Prosthetic arteriovenous graft, Thrombosed prosthetic hemodialysis grafts, Balloon angioplasty, Intra-graft stenosis

J Med Assoc Thai 2017; 100 (Suppl. 9): S236-242

Full text. e-Journal: <http://www.jmatonline.com>

Acute thrombosis of prosthetic arteriovenous (AV) graft for hemodialysis was a common complication led to morbidity, salvage procedures, new access placement, and additional costs^(1,2). The most common cause of acute thrombosis was the development of hemodynamically significant stenosis at venous anastomosis (58% to 90%)⁽³⁾. Pathogenesis of the

venous anastomosis, arterial anastomosis or outflow vein stenosis was the formation of neointimal hyperplasia that resulted in progressive luminal narrowing⁽⁴⁻⁶⁾. In contrast, stenosis that occurred within the prosthetic graft remote from the vascular anastomosis is related to the development of peri-graft scar and fibroblastic in growth through needle puncture tracts at the access cannulation sites^(5,6). Surgical treatment of acutely thrombosed AV graft was thrombectomy and selective local revision with 1-year patency rates of 3% to 36%^(7,8). In our center we performed surgical thrombectomy and selective local revision of stenosed venous anastomosis by venous

Correspondence to:

Tirapanich W, Vascular and Transplant Unit, Department of Surgery, Ramathibodi Hospital, Mahidol University, Bangkok 10400, Thailand.

Phone: +66-2-2011315, Fax: +66-2-2011316

E-mail: ramasurgeon@gmail.com

patch or jump graft. After thrombectomy and revision, we did not perform routine intraoperative fistulography if a good thrill was observed over the graft and the outflow vein. Therefore some intragraft stenoses might not be detected or corrected with our standard approach. The reported incidence of intragraft stenosis was around 2 to 28%⁽⁹⁾ in studies of dysfunctioning or failing graft. Primary access patency rates had been reported to be in the range of 56% to 75% after angioplasty of intragraft lesions⁽¹⁰⁻¹²⁾. There was lack of studies analyzing outcomes of interventions specifically on intragraft stenosis or incidence of intragraft stenosis in thrombosed dialysis graft. Although numerous studies reported postintervention access patency outcome between the endovascular and surgical treatment of thrombosed dialysis graft, there was no study analyzing outcomes of surgical revision combined with adjunctive balloon angioplasty on intragraft stenosis in thrombosed dialysis graft. Therefore, the purpose of this study was to compare surgical revision and adjunctive balloon angioplasty with surgical revision alone in terms of post-intervention primary patency rate, the efficacy of balloon angioplasty on intragraft stenosis and incidence of intragraft stenosis in thrombosed dialysis graft.

Material and Method

After the study protocol was approved by Ethical Committee of Ramathibodi Hospital all consecutive patients who came for treatment of acute AV graft thrombosis at Vascular Surgery and Transplantation division Ramathibodi Hospital during March 2016 to January 2017 were enrolled to our study. Dialysis graft thrombosis were confirmed by duplex ultrasound performed by vascular surgery fellows under supervision of the attending staffs. Exclusion criteria were grafts created less than 3 months or more than 2 years, graft with infection, contrast allergy, revision more than twice and patient refused to be enrolled. After providing informed consent, patients were randomized to the intervention and control group using a computer-generated list of four block random numbers and placed in opaque, sealed envelopes.

All thrombosed dialysis graft patients underwent surgical thrombectomy with or without graft revision and intraoperative fistulography. The procedures were performed in the operating room by vascular surgery fellows under local anesthesia as outpatient procedure. Thrombosed grafts were accessed by reopening the incision used to place the dialysis graft. The venous limb was exposed, controlled

and then opened for thrombectomy using No. 4 Fogarty thrombectomy catheter. The venous end was declotted first then the arterial plug and clot were removed. Following complete clot removal, a PTFE patch angioplasty was performed or alternatively, an interposition bypass graft was created to correct stenosis of venous anastomosis. Surgical thrombectomy alone was performed if no anatomic cause of graft thrombosis was found. Intraoperative fistulography was performed by placement of 6 French Brite-Tip™ sheath (Cordis International, Miami, FL, USA) at the arterial aspect of the graft in a direction toward the venous outflow then iodinated contrast was injected through the sheath to visualize the arterial anastomosis, intragraft, venous anastomosis, distal outflow vein, and central veins.

Patients with intragraft stenosis randomized to the intervention group (surgical revision with adjunctive balloon angioplasty) were treated if a 50% or greater reduction in lumen diameter was identified. Balloon angioplasty was performed with MUSTANG™ balloon (Boston Scientific Corporation, Boston, MA, USA). These balloons had diameters of 6 mm and length of 40 mm to 80 mm depending upon the lesion length. Balloon was inflated to maximal capacity, usually up to 24 atmospheres of pressure.

Patients randomized to the control group (surgical revision alone) were simply followed and monitoring the vascular access according to surveillance protocol. Our ethics committee recommended balloon angioplasty to be allowed in the control group if there was intragraft stenosis of greater than 75% in diameter.

Demographic data and cardiovascular risk factors were recorded in each patient, as were the number, location, and type of any current or previous access. Information regarding surgical intervention was also recorded.

Primary outcome of this study was to compare post-intervention primary patency rate after surgical revision with adjunctive balloon angioplasty on intragraft stenosis with surgical revision alone and the efficacy of balloon angioplasty to correct intragraft stenosis in thrombosed dialysis graft. The secondary outcome was the incidence of intragraft stenosis in thrombosed dialysis graft. All patients were followed-up at OPD Vascular Surgery according with standard postoperative care. Vascular access patency and function were evaluated per protocol monthly at patient's dialysis center for 12 months. Graft failure was defined as unable to use for dialysis or recurrent

thrombosis.

We anticipated 25 patients per treatment group. By diagnostic properties of ROC between R2A Application (ROC = 0.98) and 3Di (ROC = 0.89), alpha error = 5%, power = 80 percentage calculated sample size by Power and Sample size Program: version 3^(13,14).

All post treatment assessments were defined according to Reporting standards for arteriovenous accesses of the Society for Vascular Surgery and the American Association for Vascular Surgery⁽¹⁵⁾ and with Society of Interventional Radiology (SIR) reporting standards⁽¹⁶⁾. Anatomic success after angioplasty was defined as less than 30% residual stenosis. Clinical success after treatment of a thrombosed access was defined as the resumption of normal dialysis for at least one session. Technical success of surgical revision was defined a patent graft at the conclusion of the procedure, based on a good thrill in the vein distal to the surgical site. Post-intervention primary access patency was defined as the interval from the time of surgical intervention until thrombosis or the time of patency without secondary procedure.

The patient demographic and clinical factors were tabulated along with the graft features and angiographic findings. Baseline characteristics were compared using the Student t-test for continuous variables, and Fisher exact test for categorical variables. Post-intervention access patency rates were estimated by Kaplan-Meier technique and compared with the log-rank (Mantel-Cox) test. Censoring of endpoints occurred in the setting of death, renal transplantation, graft resection as a result of infection, functioning AV graft at the end of the study period, or loss to follow-

up. The Kaplan-Meier patency rates at 3 and 6 months were stated as estimated percentage patent \pm standard error in both groups. Statistical analysis was performed by using STATA 14.0 data analysis and statistical software (Stata Corporation, College Station, TX, USA).

Results

During the study period, 104 patients were diagnosed with acute thrombosed dialysis graft at Ramathibodi Hospital, Mahidol university (Fig. 1). Of these patients, 42 were eligible and agreed to participate in the trial. One patient who was randomized to the intervention group was lost to follow-up at 1 month. Patient demographic data and access characteristics are summarized in Table 1. Median follow-up was 124 days.

The overall technical success rate of surgical revision was 92.85% (39 of 42). Blood flow could not be

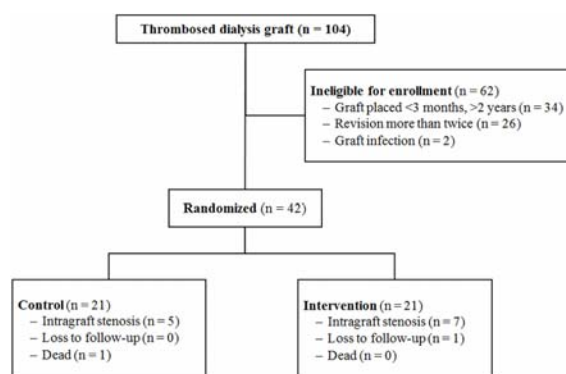


Fig. 1 Study enrollment and follow-up in the two treatment groups.

Table 1. Baseline characteristics of patients

Variable	Control (n = 21)	Intervention (n = 21)	p-value
Patient characteristics			
Age (year), mean (\pm SD)	56.05 (\pm 16.3)	59.10 (\pm 12.82)	0.504
Sex (male, %)	12 (57.4)	12 (57.4)	1.00
Diabetes mellitus (%)	23.80	33.34	0.495
Dyslipid (%)	14.29	33.34	0.147
CVD (%)	0	4.76	0.311
Previous hemodialysis catheter (%)	61.9	57.14	0.753
Previous vascular access (%)	38.1	19.05	0.172
Low cardiac output (%)	14.29	0	0.232
AV graft characteristics			
Forearm	16	14	0.495
Arm	5	7	

CVD = Cardiovascular disease

restored in 3 patients. Intra-operative fistulogram revealed that all three patients had significant intragraft stenosis; a reduction in lumen diameter of 50% or greater. One patient in the control group failed surgical revision had 90% intragraft stenosis. This patient required adjunctive balloon angioplasty to restored access function. The reason for crossing treatment group was based on our Institute Ethics Committee recommendation.

The location of stenosis was demonstrated in Table 2. The incidence of intragraft stenosis was 12/42 (28.5%). All intragraft stenosis (n = 7) in the intervention group were treated with balloon angioplasty. Intragraft stenoses (n = 5) in the control group were observed except for 1 patient described above. In the present study, we performed balloon angioplasty in 8 patients (7 from intervention group, 1 from control group) with 100% (8 of 8) anatomic success rates after balloon angioplasty (Fig. 2). Venous anastomotic stenoses were treated with patching (n = 22), interposition graft or bypass grafting (n = 19). Two patients had distal vein outflow stenosis and one required adjunctive balloon angioplasty to restored graft function. The overall clinical success rate was 97.6% (41 of 42).

Overall post-intervention primary patency rates were not significantly different between the two treatment groups (Log Rank, $p = 0.973$). The overall post-intervention primary patency rates at 3,6 month of control and intervention group were 75% (95% CI 0.57 to 0.86), 62% (95% CI 0.43 to 0.76) and 78% (95%

CI 0.61 to 0.88), 58% (95% CI 0.38-0.73), respectively. (Fig. 3).

Subgroup analysis of patients with intragraft stenosis demonstrated significantly better post-intervention primary patency rate in the intervention group than in the control group (Log Rank, $p = 0.009$). The post-intervention primary patency rates at 3,6 month of control and intervention group were 62% (95% CI 0.23 to 0.86), 0% and 87% (95% CI 0.38 to 0.98), 31% (95% CI 0.04 to 0.64), respectively (Fig. 4).

Discussion

The maintenance of functional vascular access remained an important and difficult problems for vascular surgeons who involved in the care of end stage renal disease patients. Timely intervention of acutely thrombosed access is therefore mandatory to re-establish the connection to the artificial kidney, precluding the need for placement of temporary dialysis

Table 2. The location of stenosis

Characteristic	n (%)
Venous anastomosis	40 (95)
Arterial anastomosis	1 (2)
Intragraft	12 (28)
Distal vein outflow	2 (5)
Central vein	2 (5)

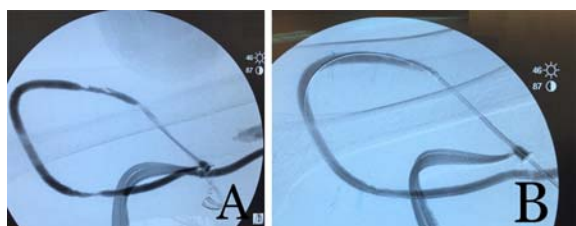


Fig. 2 A) Pre-balloon angioplasty, B) Post-balloon angioplasty.

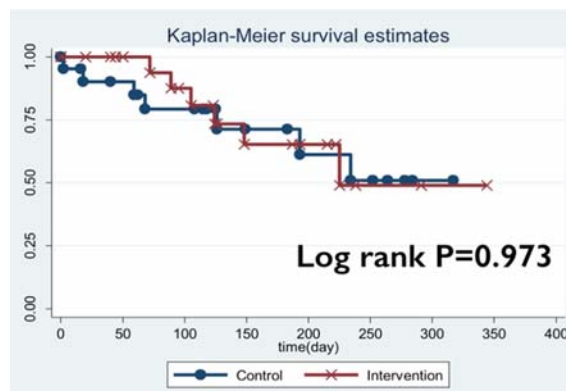


Fig. 3 The overall post-intervention primary patency rate.

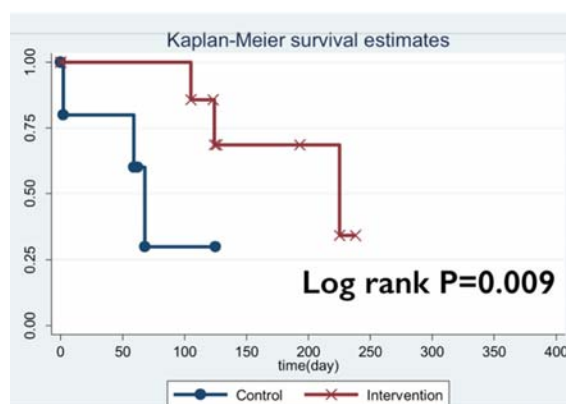


Fig. 4 The subgroup analysis of intragraft stenosis, post-intervention primary patency rate.

catheter. Salvage of grafts, rather than early abandonment and creation of new accesses, is important.

Although recent evidence from the literature^(17,18) showed that outcome of endovascular and surgical intervention for thrombosed vascular access were comparable particularly for thrombosed prosthetic grafts. Endovascular intervention currently did not offer superior result and might added cost. Our standard practice to salvaged thrombosed dialysis graft were surgical thrombectomy with or without revision of venous anastomoses. Surgical revision usually extended the access further up to some extent and offered a definite anatomical correction with superior durability⁽¹⁹⁾. Generally we did not perform routine intraoperative fistulography whenever we could palpated good thrills over the vein distal to the surgical site. However, some patients had early re-thrombosis with our standard approach.

The incidence of intragraft stenosis in thrombosed dialysis graft was 28.5% (12 of 42) in our study. Intragraft stenosis was one of the causes of technical failure of surgical revision to restored occluded vascular graft access. All three patients who failed surgical revision had significant intragraft stenoses and all were successfully salvaged with adjunctive balloon angioplasty. Our anatomic success rate of balloon angioplasty on intragraft stenosis was 100%. One other study of balloon angioplasty on intragraft stenosis reported the anatomic success of 85%⁽⁹⁾.

Although the overall post-intervention primary patency rate of both groups were not different, in the subgroup of AV grafts with intragraft stenoses the patency rate of the intervention group was significantly superior to the control group.

The National Kidney Foundation Kidney Disease Outcomes Quality Initiative⁽²⁰⁾ established target outcome thresholds for interventions aimed at maintaining dialysis graft patency. The target of a clinical success rate, which defined as the ability to use the AV graft for at least 1 HD cycle is 85%. The guidelines call for 50% unassisted patency at 6 months and 40% unassisted patency at 1 year of surgical thrombectomy and revision performed on thrombosed AV grafts. This recommendation was listed as evidence-based for the angioplasty guideline and opinion-based for the surgical revision guideline. In our study, post-intervention primary patency rate exceeded target outcomes from the guidelines, with a 62% unassisted patency at 6 months in thrombosed AV grafts. The

clinical success rate also exceeded target outcomes, with a 97.6% success rate after treatment of AV graft thrombosis.

The strengths of our study included a randomized design and the prospective collection of outcome data by a single investigator. Nevertheless, the present study also had limitations. One of the limitations was small sample size in intragraft stenosis. Another limitation was short follow-up time. The median time of follow-up was 124 days (95% CI 126 to 291). Therefore, we did not analyze assisted post-intervention primary patency rate and post-intervention secondary patency rates.

Conclusion

Intraoperative fistulography should be performed during the surgical revision of thrombosed dialysis graft in order to detect intragraft stenoses because the incidence was quite high (28.5%) in this group of patients.

Intragraft stenosis could be effectively (100%) corrected by balloon angioplasty with no morbidity, therefore resulted in prolong vascular access life.

What is already known on this topic ?

Acute thrombosis is a common complication of hemodialysis vascular access. The most common cause of thrombosis is venous anastomotic stenosis, 58% to 90% of the patients. However, the incidence of intragraft stenosis is around 2 to 28%.

The traditional treatment is surgical thrombectomy and selective local revision. In our center, we perform surgical thrombectomy and selective local revision alone if good thrill can be observed in the vein distal to the surgical site; no routine intraoperative fistulography. Therefore, intragraft stenoses can be missed in the traditional treatment.

The National Kidney Foundation Kidney Disease Outcomes Quality Initiative has established target outcome thresholds for interventions aimed at maintaining dialysis graft patency. The guidelines call for 50% unassisted patency at 6 months and 40% unassisted patency at 1 year if surgical thrombectomy with revision is performed in thrombosed AV grafts.

What this study adds ?

All thrombosed dialysis graft patients showed 28.5% incidence of intragraft stenosis.

Adjunctive balloon angioplasty, which demonstrated 100% anatomical success rate, increases the post-intervention primary patency rate in

thrombosed dialysis graft with surgical revision. In the present study, post-intervention primary patency rate exceeded target outcomes from the guidelines, with a 62% unassisted patency at 6 months in thrombosed AV grafts.

Acknowledgements

This work was supported by Division of Vascular Surgery and Transplantation, Faculty of Medicine, Ramathibodi Hospital, Mahidol University, Bangkok, Thailand. Thanks to all our staffs. Ms. Nipapan Choonu for assistance in the study. Ms. Suraida Aeesoa for statistical analysis.

Potential conflicts of interest

None.

References

1. Brenner L, Singh AK, Campbell D, Frei F, Winkelmayr WC. Associations between demographic factors and provider structures on cost and length of stay for hemodialysis patients with vascular access failure. *Clin J Am Soc Nephrol* 2006; 1: 455-61.
2. Sawant A, Mills PK, Dhingra H. Increased length of stay and costs associated with inpatient management of vascular access failures. *Semin Dial* 2013; 26: 106-10.
3. Kanterman RY, Vesely TM, Pilgram TK, Guy BW, Windus DW, Picus D. Dialysis access grafts: anatomic location of venous stenosis and results of angioplasty. *Radiology* 1995; 195: 135-9.
4. Bittl JA. Catheter interventions for hemodialysis fistulas and grafts. *JACC Cardiovasc Interv* 2010; 3: 1-11.
5. Mima A. Hemodialysis vascular access dysfunction: molecular mechanisms and treatment. *Ther Apher Dial* 2012; 16: 321-7.
6. Roy-Chaudhury P, Sukhatme VP, Cheung AK. Hemodialysis vascular access dysfunction: a cellular and molecular viewpoint. *J Am Soc Nephrol* 2006; 17: 1112-27.
7. Brotman DN, Fandos L, Faust GR, Doscher W, Cohen JR. Hemodialysis graft salvage. *J Am Coll Surg* 1994; 178: 431-4.
8. Marston WA, Criado E, Jaques PF, Mauro MA, Burnham SJ, Keagy BA. Prospective randomized comparison of surgical versus endovascular management of thrombosed dialysis access grafts. *J Vasc Surg* 1997; 26: 373-80.
9. Bautista AB, Suhocki PV, Pabon-Ramos WM, Miller MJ Jr, Smith TP, Kim CY. Postintervention patency rates and predictors of patency after percutaneous interventions on intragraft stenoses within failing prosthetic arteriovenous grafts. *J Vasc Interv Radiol* 2015; 26: 1673-9.
10. Beathard GA. Percutaneous transvenous angioplasty in the treatment of vascular access stenosis. *Kidney Int* 1992; 42: 1390-7.
11. Kariya S, Tanigawa N, Kojima H, Komemushi A, Shomura Y, Shiraishi T, et al. Primary patency with cutting and conventional balloon angioplasty for different types of hemodialysis access stenosis. *Radiology* 2007; 243: 578-87.
12. Saleh HM, Gabr AK, Tawfik MM, Abouellail H. Prospective, randomized study of cutting balloon angioplasty versus conventional balloon angioplasty for the treatment of hemodialysis access stenoses. *J Vasc Surg* 2014; 60: 735-40.
13. Dupont WD, Plummer WD Jr. Power and sample size calculations. A review and computer program. *Control Clin Trials* 1990; 11: 116-28.
14. Dupont WD, Plummer WD Jr. Power and sample size calculations for studies involving linear regression. *Control Clin Trials* 1998; 19: 589-601.
15. Sidawy AN, Gray R, Besarab A, Henry M, Ascher E, Silva M Jr, et al. Recommended standards for reports dealing with arteriovenous hemodialysis accesses. *J Vasc Surg* 2002; 35: 603-10.
16. Gray RJ, Sacks D, Martin LG, Trerotola SO. Reporting standards for percutaneous interventions in dialysis access. *J Vasc Interv Radiol* 2003; 14 (9 Pt 2): S433-42.
17. Dougherty MJ, Calligaro KD, Schindler N, Raviola CA, Ntoso A. Endovascular versus surgical treatment for thrombosed hemodialysis grafts: A prospective, randomized study. *J Vasc Surg* 1999; 30: 1016-23.
18. Tordoir JH, Bode AS, Peppelenbosch N, van der Sande FM, de Haan MW. Surgical or endovascular repair of thrombosed dialysis vascular access: is there any evidence? *J Vasc Surg* 2009; 50: 953-6.
19. Wellington JL. Salvage of thrombosed polytetrafluoroethylene dialysis fistulas by interposition grafting. *Can J Surg* 1983; 26: 463-5.
20. Kinney R. Centers for Medicare and Medicaid Services. 2005 Annual report: ESRD clinical performance measures project. *Am J Kidney Dis* 2006; 48 (4 Suppl 2): S1-106.

การศึกษาเปรียบเทียบประสิทธิภาพของบอลูนถ่างขยายในเส้นเลือดเทียมฟอกไตตีบร่วมกับการผ่าตัดแก้ไขในผู้ป่วยฟอกเลือดด้วยหลอดเลือดเทียมที่มีภาวะลิ่มเลือดอุดตัน

ศุภชัย จันทรวีรัตน์, สุทัศน์ ฮ่อศิริมานนท์, โสภณ จิรสิริธรรม, สุรศักดิ์ ลีลาอุดมลิปิ, ปิยนุช พุตรระกุล, ญัฐสิริ กิตติถิระพงษ์, ศักดา อาจองค์ วัลลภากร, วิวัฒน์ ธีระพานิช

วัตถุประสงค์: เพื่อเปรียบเทียบอัตราการเปิดหลังแก้ไข (post-intervention primary patency rate) ภาวะเส้นฟอกเลือดชนิดเส้นเลือดเทียม (dialysis graft) อุดตันเฉียบพลันระหว่างการรักษาด้วยการผ่าตัดแก้ไขอย่างเดียว (surgical revision) กับการผ่าตัดแก้ไขร่วมกับการขยายเส้นฟอกเลือดที่ตีบ (intragraft stenosis) ด้วยบอลูน (balloon angioplasty), ประสิทธิภาพของการขยายเส้นฟอกเลือดตีบด้วยบอลูน, และอุบัติการณ์ตีบของเส้นฟอกเลือดที่มาด้วยการอุดตันเฉียบพลัน

วัสดุและวิธีการ: ผู้ป่วยที่เส้นฟอกเลือดอุดตันมารับการรักษาที่ โรงพยาบาลรามารินทร์ ระหว่างเดือนมีนาคม พ.ศ. 2559 ถึง เดือนมกราคม พ.ศ. 2560 ทั้งหมด 104 ราย เจาะใจที่คัดออกจากการศึกษาคือ เส้นฟอกเลือดที่ทำนานน้อยกว่าสามเดือนหรือนานเกินกว่าสองปี, มีการติดเชื้อ, เคยได้รับการผ่าตัดแก้ไขการอุดตันมาก่อน, และแพทย์ที่รับส่งต่อผู้ป่วย 42 รายในการศึกษานี้ ถูกแบ่งแบบสุ่ม (randomly assign) เป็นสองกลุ่ม ผู้ป่วยทุกรายได้รับการผ่าตัดแก้ไขร่วมกับฉีดสารทึบรังสีเพื่อตรวจหาการตีบของเส้นฟอกเลือด และติดตามผลในผู้ป่วยกลุ่มแรก (control group) ส่วนกลุ่มที่สอง (intervention group) จะได้รับการขยายด้วยบอลูนถ้าพบการตีบของเส้นฟอกเลือดมากกว่า 50% อัตราการเปิด (patency rate) ของเส้นฟอกเลือดคำนวณโดยใช้ Kaplan-Meier survival analysis

ผลการศึกษา: ผู้ป่วยทั้งสองกลุ่มไม่มีความแตกต่างกันในลักษณะพื้นฐานและโรคประจำตัว ($p > 0.05$) ค่ามัธยฐานในการติดตามผลการรักษา (median follow-up time) 124 วัน (95% CI 126 ถึง 291) อัตราการเปิดโดยรวมหลังแก้ไข เส้นฟอกเลือดอุดตัน (overall post-intervention primary patency) ของทั้งสองกลุ่มไม่แตกต่างกัน ($p = 0.973$) ที่ 3, 6 เดือน ของกลุ่มแรก (control group) เทียบกับกลุ่มที่สอง (intervention group) คือ 75% (95% CI 0.57 ถึง 0.86), 62% (95% CI 0.43 ถึง 0.76) และ 78% (95% CI 0.61 ถึง 0.88), 58% (95% CI 0.38 ถึง 0.73) ตามลำดับ หากวิเคราะห์เฉพาะกลุ่มย่อย (subgroup analysis) ที่มีการตีบของเส้นฟอกเลือดพบว่า อัตราการเปิดหลังแก้ไขเส้นฟอกเลือดอุดตัน (post-intervention primary patency) ของกลุ่มที่สอง (intervention group) ดีกว่าของกลุ่มแรก (control group) อย่างมีนัยสำคัญ ($p = 0.009$) โดยที่ 3, 6 เดือน ของกลุ่มแรก (control group) เทียบกับกลุ่มที่สอง (intervention group) เป็น 62% (95% CI 0.23 ถึง 0.86), no data และ 87% (95% CI 0.38 ถึง 0.98), 31% (95% CI 0.04 ถึง 0.64), ตามลำดับ การขยายเส้นฟอกเลือดด้วยบอลูนสำเร็จ 100% และพบการตีบของเส้นฟอกเลือด 28.5% (12/42)

สรุป: อุตการณ์เกิดเส้นฟอกเลือดตีบสูงถึง 28.5% และสามารถแก้ไขด้วยบอลูน ซึ่งจะช่วยยืดอายุการใช้งานของเส้นฟอกเลือด
