

# Clinical Evaluation of a New Blue Nano-Silver Biocellulose Ribbon Dressing in Cavity Wounds

Surawej Numhom MD\*, Prapai Ariyaprayoon RN\*\*, Vichai Srimuninnimit MD\*

\* Division of Plastic and Maxillofacial Surgery, Department of Surgery, Faculty of Medicine Ramathibodi Hospital, Mahidol University, Bangkok, Thailand

\*\* Department of Surgical Nursing, Faculty of Nursing, Mahidol University, Bangkok, Thailand

**Background:** For optimal wound-healing process, antimicrobial ability and proper moisture balance appear to play vital roles in design of wound dressings. Ideal wound dressing should promote moist wound environment that supports the body's healing process. Pain-free removal, proper exudates absorption, suitable moisture and infection control serve as the benchmarks for ideal wound dressing. Biocellulose derived from *Acetobacter xylinum* has been found to provide decent moisture control and exudate absorption. By combining with impregnated silver nanoparticles, the resultant dressings obtain antimicrobial property. This study describes another innovative ribbon form of blue nano-silver biocellulose ribbon dressing (BNBR: BluRibbon®, Novatec Healthcare, Thailand) with effective wound healing property for deep or cavity wounds where extra care is required.

**Objective:** The present study aimed at evaluating the clinical efficacy of cavity wounds management using BNBR at 4 weeks.

**Material and Method:** 24 patients, aged over 18 years, who were presented at an outpatient wound clinic and treatment unit with cavity wounds of various etiologies, were included in this study. Patients were prospectively followed for 4 weeks or until healing completion for analysis of safety and efficacy endpoints. Wound surfaces were used to assess the initial sizes and evaluate the progress of healing. Evolution of wound size was conducted with tracing and standardized digital photographs using Image J image analysis software for determination of the healing rates.

**Results:** 24 patients (30 wounds) with an average age of 47.6 years old were evaluated. Cavity wounds enrolled has an average area of 2.4 cm<sup>2</sup> and approximately 1.4 cm in wound depth. BNBR enabled minimization of wound area in 90% (27 wounds) of wound samples, whereas 97% (29 wounds:  $p < 0.001$ ) demonstrated significant reduction in wound depth after an average of 20.7 days of treatment using BNBR dressing. All patients reported their experiences as pain-free both in situ and on removal.

**Conclusion:** BNBR significantly promotes cavity wound healing process by reducing both wound area and depth. Suitable moisture balance and antimicrobial function in BNBR contributed to fast healing process. The present findings appear encouraging for further randomized controlled trial in larger study groups.

**Keywords:** Cavity wound, Silver nanoparticles, Biocellulose dressing

**J Med Assoc Thai 2017; 100 (Suppl. 9): S212-S219**

**Full text. e-Journal:** <http://www.jmatonline.com>

The ideal wound dressing should be simple to apply, be available in various shapes and sizes, maintain appropriate moisture balance, sustain antimicrobial activity, activate autolytic debridement, and be non-painful in situ and on dressing removal<sup>(1-5)</sup>. Specifically, fluid-holding capacity has been reported as the key factor for optimal wound healing<sup>(6-8)</sup>. Various types of dressings for wounds have continuously been launched into the wound care market. Each contains

unique properties to serve different types of wounds. Sophisticated wound dressings with highly absorptive, nonadherent, and painless property (e.g. hydrocolloids, alginates, and foam) are widely used in current wound care. Nonetheless, most of them are not specifically designed for cavity wounds and they fulfilled very few properties of ideal cavity wound dressing.

Biocellulose, a polysaccharide synthesized by *Acetobacter xylinum*, contains nanostructure with high mechanical strength and moisture retention properties<sup>(1)</sup>. Due to these unique physical and mechanical properties, biocellulose shows great potential as novel wound dressing materials. It promotes good moisture balance and close adhesion as its soft texture allow it to good conformity to shape of the wound bed<sup>(10-13)</sup>. Biocellulose dressings show

---

#### Correspondence to:

Numhom S, Division of Plastic and Maxillofacial Surgery, Department of Surgery, Faculty of Medicine Ramathibodi Hospital, Mahidol University, 270 Rama VI Road, Ratchathewi, Bangkok 10400, Thailand.

Phone: +66-2-2011315, Fax: +66-2-2011316

E-mail: [dr.surawej@gmail.com](mailto:dr.surawej@gmail.com)

immediate pain relief, high absorbency, and fast wound closure in more than 300 chronic ulcers and lesion treatments<sup>(14)</sup>. However, such biocellulose contains no antibacterial activity to prevent wound infection<sup>(3)</sup>. Many studies have therefore been devoted to the development of antimicrobial biocellulose dressing materials, especially silver-containing dressing materials<sup>(16-19)</sup>.

Silver nanoparticles appear to be the most promising antibacterial agents due to its high antimicrobial efficiency and non-toxicity to human cells (with minute concentration). Since bactericidal efficiency is influenced by the particle's shape, size, and concentration<sup>(20,21)</sup>, triangular-shaped silver nanoparticles are found to demonstrate the most effective bactericidal action when compared with spherical and rod-shaped nanoparticles<sup>(22)</sup>. Biocellulose dressing with impregnated silver nanoparticles showed high antimicrobial efficiencies against Gram-negative and Gram-positive bacteria<sup>(16,17,23)</sup>. They are also effective against resistant organisms such as MRSA and *Pseudomonas*<sup>(24)</sup>. To date, silver-containing microbial cellulose dressing exists as various commercial products for the treatment of infected wounds, chronic ulcers and burn wounds.

Cavity wounds superficially look like simple wounds to treat, but this was where the concept of the proper wound drainage and moisture balance came into consideration. A cavity wound may produce excessive exudates which increases maceration or infection. Wound depth may impede wound assessment and healing. Specialized wound dressing is therefore required.

Recently, blue nano-silver biocellulose ribbon dressing (BNBR: BluRibbon®, Novatec Healthcare, Thailand), a silver-releasing ribbon dressing product specialized for cavity wound, has been launched in the market. This dressing is designed in the ribbon form for ease of use in cavity wound care. Clinical trials were undertaken in patients with cavity wounds to investigate the clinical efficacy of BNBR in wound healing. The effectiveness of such dressing was determined by the impact on wound healing and pain level during dressing change.

## Material and Method

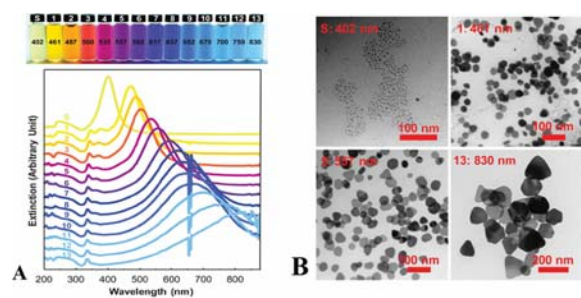
### Study design and ethical conduct of research

This was a prospective open label non-blinded observational study of BNBR, a nano-silver biocellulose ribbon dressing, as the primary wound care product used in treatment of patients with cavity wounds of

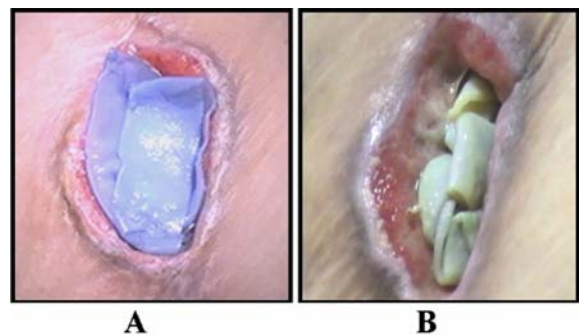
various etiologies. The study was conducted in accordance with the Helsinki Declaration of Human Rights and all patients gave their informed consent. This study was approved by the Ethic Committee on Human Experimentation of the Faculty of Medicine, Ramathibodi Hospital, Mahidol University.

## Materials

On the microscopic scale, BNBR is impregnated with a specifically designed triangular shape and size of silver nanoparticles with unique optical property that makes the nanoparticles blue, upon release and deformation of its original shape and size the blue color fades and becomes pale yellow<sup>(29-32)</sup> (Fig. 1). This acts as a self-indicator to notify caretaker when redressing is required. On the macroscopic scale, BNBR is designed in the shaped of a ribbon to be easily conformed to fit the contour of the actual wound (Fig. 2).



**Fig. 1** A) Chart relating wavelength and color of the nano-silver particles at different shapes & sizes, B) Actual picture of the nano-silver particles at shapes & sizes. The shape and size shown in the lower right is chosen for BNBR.



**Fig. 2** A) Picture of BNBR immediately after application to a cavity wound, B) Picture of BNBR 2 days after application.

### **Study objectives**

This study aimed to evaluate the effectiveness of BNBR on cavity wound healing by reduction in wound dimension, growth of healthy tissue, and pain level during dressing change.

### **Patients**

Patients were recruited from the Outpatient Wound Clinic of the Department of Surgery at Ramathibodi Hospital, Thailand.

### **Inclusion criteria**

All participants were required to be between 18 and 90 years of age. The cavity wounds must have occurred less than 28 days before the subject enrolled in the study.

### **Exclusion criteria**

Criteria included uncontrolled cardiac failure, evidence of severe liver or kidney disease, vascular inadequacy, and participants undergoing immunosuppressive therapy. These criteria were assessed by reviewing patients' medical history, direct interview, and taking pulses - dorsalis pedis pulse and posterior tibial pulse.

### **Treatment protocol**

Prior to enrolling into this study, the study requirements were explained to the potential subjects. Written informed consent was obtained for study inclusion and photography of their wounds. Patients and their wounds were assessed for inclusion suitability. For analysis of safety and efficacy endpoints all participants were followed prospectively weekly for a maximum of 4 weeks, or until full healing. The primary parameters of the study were the percentage of wound reduction and the reduction in wound depth by comparing day 0 with week 4 results. Secondary parameters were pain score during dressing change. Complete healing was defined as complete epithelialization with the absence of drainage or the wound no longer requiring any dressings. Characteristics of the wound bed were recorded at each patient visit along with wound measurements. Local wound therapy included surgical debridement when appropriate.

This was followed by application of BNBR by trained wound care specialist nurses. For cavity wound with very small opening area, BNBR may be cut into appropriate shape, and it may also be necessary to carefully extend the wound opening in order to insert

the BNBR into the cavity wound. Secondary dressing of normal gauze is used to securely position the BNBR directly above the wound area. Extra care in dressing the BNBR is required due to the softness & slipperiness of the biocellulose otherwise body movement or a change of position can accidentally displaced the dressing from the wound bed. Redressing is applied every 1 to 3 days depending on the clinical judgment of the nurses or physicians based on the wound conditions.

The surface of all wounds was used to assess the initial size and evaluate its progress. The evolution of wound size was monitored using standardized digital photographs and Image J software version 1.34 (NIH, USA, <http://reb.info.nih.gov/ij/>), which was used to calculate wound surface area and determine healing rate. Wound depth was measured by probing the wound with cotton-tipped applicator. Pain at dressing change was assessed by the patient using a 10-point visual analogue scale (VAS). There were no variations in treatment of any of the wounds included in this study.

### **Statistical analysis**

Paired t-tests were used to compare the differences of wound area between day 0 and week 4. Ninety-five percent confidence intervals of the difference were taken and statistical significance was set as  $<0.05$ .

### **Results**

In the present study, 30 wounds from 24 patients with age ranging from 18 to 74 years old (average 47.6 years old) were evaluated from August 2011 to September 2012. There were thirty cavity wounds: 13 were by trauma, 11 were by dog bites, 5 were by post-operative infection, 1 was by soft tissue infection. 8 patients (about 26.7%) had type-2 diabetes and diabetes-related foot.

The average wound area and depth before treatment are  $2.4 \text{ cm}^2$  (ranges  $0.1$  to  $26.0 \text{ cm}^2$ ) and  $1.4 \text{ cm}$  (ranges  $0.3$  to  $4.8 \text{ cm}$ ), respectively. After application of BNBR, the wound dimensions were significantly reduced in 29 wounds (97%). Overall, there was a  $86.8 \pm 27.1\%$  reduction in wound area and  $91.2 \pm 21.8\%$  reduction in wound depth observed (Table 1). Furthermore, BNBR displayed great potentials as a pain-free product. Neither pain in situ nor on removal nor side effect was observed in all patients.

The average duration of healing is  $20.7 \pm 7.7$  days (range 5 to 28 days). There were complete healings in 20 cases wound depths were reduced  $14.3\%$  to  $100.0\%$

**Table 1.** Statistical data after application of BNBR on 30 cavity wounds in all study patients

	Mean $\pm$ SD	Range	<i>p</i> -value
Age (years)	47.6 $\pm$ 15.6	18 to 74	
Time to complete healing (days)	20.7 $\pm$ 7.8	5 to 28	
	Wound area (cm <sup>2</sup> )		
Before	2.4 $\pm$ 4.9	0.1 to 26.0	
After	0.5 $\pm$ 1.5	0.0 to 8.0	
% reduction	86.8 $\pm$ 27.1	-30.4 to 100	<0.001
	Wound depth (cm)		
Before	1.4 $\pm$ 1.0	0.3 to 4.8	
After	0.1 $\pm$ 0.2	0.0 to 0.9	
% reduction	91.2 $\pm$ 21.8	14.3 to 100.0	<0.001

at week 4 (Table 2).

In the group of 28-day treatment, after the BNBR's application in 30 wounds, the differences in wound area before vs after treatment and wound depth before vs. after treatment are statistically significant.

After a maximum of 28 days of treatment with BNBR, there are more cavity wounds with complete depth reduction than cavity wounds with complete area reduction. (Fig. 3, 4). This result is in accordance with normal cavity wound healing process, where the deep part of the wound must be healed prior to the healing of the superficial part.

In sub-group analysis of diabetic patients, not only were all the wound areas minimized, but also the reductions in wound depth were observed in all but one case. BNBR dressing enabled cavity filling and many of the diabetic wounds were completely recovered after 28 days of application. Only 14% (1 in 7 wounds) of wounds with diabetes showed enlargement. These findings support that BNBR dressing could provide decent moisture balance and bacterial barrier for cavity wound healing in diabetic cases.

## Discussion

At a minimum, an ideal cavity wound dressing should be able to absorb large volume of exudates, be molded to contour to the irregular shape of the cavity wounds, and adhere to the wound in such a way as to be atraumatic upon removal.

From our study, it was found that the silver-containing BNBR can provide moisture balance and exudates control leading to good wound-healing environment for cavity wounds. BNBR can absorb a moderate amount of exudates. For most wounds, the treatment with BNBR alone is sufficient for complete

healing within 28 days including the wounds of the diabetic patients as evident from the 6 out of 7 wounds that were healed without any clinical complications. For wounds with an unusually large amount of exudates, secondary dressing with high moisture absorption capacity is recommended on top of BNBR. On the contrary, for wounds with an unusually dry surface dressing that provide moisturizing effect such as hydrogels may be indicated in conjunction with BNBR. The final decisions of the wound dressers should be based upon individual wound conditions since each stage may require different types of wound dressing. From observations, it was found that in the early part of wound treatment the blue color of the BNBR fades quite quickly resulting in frequent redressing. Nevertheless, after improvement of the wound condition the discoloration rate is much slower, malodor is noticeably reduced, and the dressing can remain in the cavity wound for a longer period. Potentially, this could be the result of reduced bacterial load that reduces the rate of silver release, which ultimately slows down the discoloration.

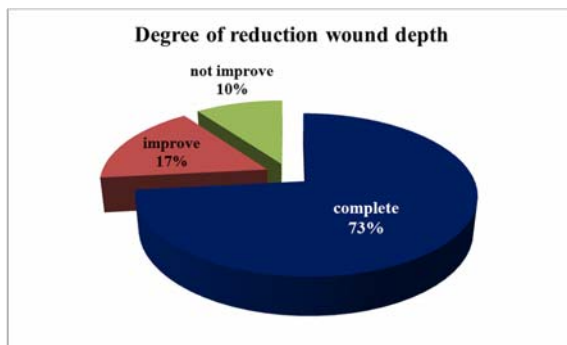Dressing with stuffed gauze soaked in normal saline solution is the traditional way of managing cavity wounds. However, this dressing will dry out, causing adherence of the dressing to the wound bed, which upon removal causes the wound to bleed and results in much discomfort and pain for the patient. The flexibility of the BNBR allows the dressing to be placed into irregularly shaped cavity wounds with ease. Additionally, the moisture retention property of the product enables BNBR to be removed easily, pain free, and atraumatically from cavity wounds.

From observation in actual clinical use, most diabetic wounds were healed after BNBR dressing and

**Table 2.** Patient and wound size characteristics during BNBR treatment

Number	Age	Sex	Cavity wound		Cause	Number of day before treatment (day)	Average of wound size (cm <sup>2</sup> )		Percent of reduction of wound size after treatment (%)		Average of wound depth (cm)		Percent of reduction of wound depth after treatment (%)	Number of day to complete healing (day)
			site	site			Before treatment	After treatment	Before treatment	After treatment	Before treatment	After treatment		
1	58	M	Lt. Plantar	Trauma		26	0.3	0.0	100.0	0.8	0.0	100.0	14	
2	48	M	Abdomen	Post-operative infection		9	0.6	0.0	100.0	1.0	0.0	100.0	21	
3	74	M	Lt. Elbow	Trauma		10	6.0	0.0	100.0	0.8	0.0	100.0	21	
4	29	M	Rt. Leg	Trauma		8	9.0	0.0	100.0	1.0	0.0	100.0	28	
5	51	M	Lt. Plantar	Trauma		7	2.0	0.2	90.0	2.0	0.5	75.0	26	
6	48	M	Lt. Leg	Trauma		2	0.8	0.0	100.0	1.9	0.0	100.0	28	
7	63	F	Rt. Big toe	Trauma		6	2.2	0.0	100.0	2.0	0.0	100.0	27	
8	74	M	Abdomen	Post-operative infection		13	0.2	0.0	100.0	1.1	0.0	100.0	14	
9	18	M	Lt. Leg	Trauma		8	5.2	2.4	54.0	1.9	0.0	100.0	24*	
10	20	F	Rt. Thigh	Soft tissue		1	2.5	0.0	100.0	2.6	0.0	100.0	28*	
11	63	F	Sternum	Post-operative infection		8	0.1	0.0	100.0	1.0	0.0	100.0	21*	
12	72	M	Rt. Foot	Dog bite		5	0.9	0.4	56.0	0.7	0.6	14.0	28*	
13	72	M	Rt. Foot	Dog bite		5	0.2	0.0	100.0	0.6	0.0	100.0	13	
14	50	F	Lt. Palm	Dog bite		11	0.5	0.0	100.0	1.0	0.0	100.0	7	
15	38	M	Lt. Leg	Dog bite		9	0.2	0.0	100.0	0.3	0.0	100.0	11	
16	38	M	Lt. Leg	Dog bite		10	0.2	0.0	100.0	0.7	0.0	100.0	15	
17	38	M	Lt. Leg	Dog bite		11	1.8	0.2	89.0	0.8	0.0	100.0	28*	
18	38	M	Lt. Leg	Dog bite		12	0.4	0.0	100.0	0.9	0.0	100.0	28	
19	49	M	Rt. Leg	Dog bite		11	0.1	0.0	100.0	2.1	0.0	100.0	12	
20	49	M	Rt. Leg	Dog bite		11	0.1	0.0	100.0	0.3	0.0	100.0	12	
21	40	F	Lt.	Post-operative infection		17	0.2	0.0	100.0	1.2	0.0	100.0	5	
22	18	F	Chest wall	infection		20	0.1	0.0	100.0	0.7	0.0	100.0	14	
23	43	F	Rt. Leg	Trauma		10	26.0	8.0	69.0	3.0	0.0	100.0	28*	
24	47	F	Rt. Groin	Trauma		7	0.3	0.0	100.0	1.5	0.0	100.0	14	
25	47	F	Rt. Leg	Dog bite		7	2.0	0.0	100.0	3.0	0.0	100.0	14	
26	58	M	Lt. Big toe	Trauma		3	2.3	0.5	78.0	2.0	0.9	55.0	28*	
27	55	F	Lt. Leg	Trauma		7	0.2	0.1	50.0	0.5	0.2	60.0	28*	
28	56	M	Rt. Leg	Trauma		9	0.9	1.2	-33.0	0.3	0.2	33.0	28*	
29	32	M	Lt. Leg	Trauma		23	5.0	0.6	88.0	4.8	0.0	100.0	28*	
30	41	M	Rt. Leg	Post-operative infection		3	3.0	0.4	87.0	2.5	0.0	100.0	28*	

\* Incomplete wound healing at the end of 28-day of treatment

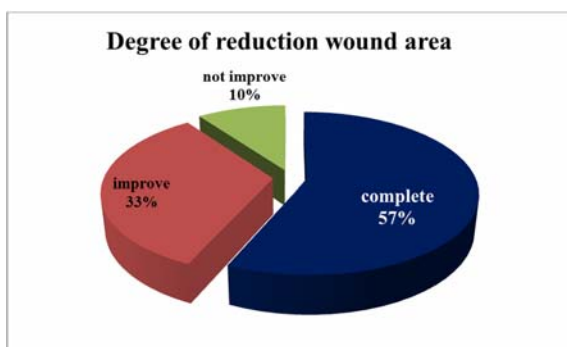

Complete = Cavity wounds whose depths have been completely reduced.

Improved = Cavity wounds whose depths have been reduced by >30%, but have not been completely reduced.

Not improved = Cavity wounds whose depths have been reduced by <30%.

**Fig. 3** Reduction of wound depth after 28 days of treatment with BNBR.



Complete = Cavity wounds whose areas have been completely reduced.

Improved = Cavity wounds whose areas have been reduced by >30%, but have not been completely reduced.

Not improved = Cavity wounds whose areas have been reduced by <30%.

**Fig. 4** Reduction of wound area after 28 days of treatment with BNBR.

many showed good improvement in wound size. There was reports of irritation and pain in the wound area when BNBR is used with betadine. Further investigations are warranted to see if there are any possibilities of adverse reactions between the iodine in betadine and the silver in BNBR.

The present study has limitations because clinical evaluations using case series are descriptions of practice and do not have comparison or control groups, it is not possible to draw any conclusions on

cause and effect relationships from the present evaluation. A randomized controlled trial with a larger sample size would be needed to show definite significant differences in clinical efficacy of BNBR.

### Conclusion

This study demonstrated that the silver-containing BNBR can provide moisture balance and exudates control leading to good wound-healing environment for cavity wounds. BNBR dressings showed significant reduction in wound dimension, especially wound depth. Moreover, the triangular nano-sized silver in BNBR promotes antimicrobial activity resulting in fast healing in this study. Additionally, most diabetic wounds were healed after BNBR dressing and many showed good improvement in wound size. Combining the pain-free and color-fading properties, BNBR may be an alternative option for cavity wound dressing products, especially for home care. However, this study was a descriptive case series, therefore further randomized control studies are warranted to ascertain the statistical significance of these observations.

### What is already known on this topic?

Cavity wounds provide a number of management challenges. Tissue types and exudate levels will determine which wound dressing is selected. The use of topical antimicrobial product may help to reduce the bacterial level in wound and restart the healing process. All wounds will require regular review to ensure the treatment is optimal for the condition of the wound.

### What this study adds?

This study described an innovative pre-cut ribbon shaped of blue nano-silver biocellulose wound dressing. This unique ribbon shape allows the product to fit the contours of the wound without changing the shape of the dressing. Biocellulose provides decent moisture control and exudate absorption and silver nanoparticles add antimicrobial action. The use of this new dressing should address the bacterial balance in the wound while maintain a moist wound healing environment.

### Acknowledgements

The authors would like to acknowledge the contribution of Sanong Ekgasit PhD, Department of Chemistry, Faculty of Science, Chulalongkorn University. Miss Wijitra Matang BS, BPH and Miss.

Suteera Srisamai MSc, Department of Surgery, Faculty of Medicine Ramathibodi Hospital, Mahidol University, for their assistance of collecting data.

#### Potential conflicts of interest

None.

#### References

1. Czaja W, Krystynowicz A, Bielecki S, Brown RM Jr. Microbial cellulose—the natural power to heal wounds. *Biomaterials* 2006; 27: 145-51.
2. Park SU, Lee BK, Kim MS, Park KK, Sung WJ, Kim HY, et al. The possibility of microbial cellulose for dressing and scaffold materials. *Int Wound J* 2014; 11: 35-43.
3. Czaja WK, Young DJ, Kawecki M, Brown RM Jr. The future prospects of microbial cellulose in biomedical applications. *Biomacromolecules* 2007; 8: 1-12.
4. Ovington LG. Advances in wound dressings. *Clin Dermatol* 2007; 25: 33-8.
5. Baranoski S. Wound dressings: a myriad of challenging decisions. *Home Healthc Nurse* 2005; 23: 307-17.
6. Okan D, Woo K, Ayello EA, Sibbald G. The role of moisture balance in wound healing. *Adv Skin Wound Care* 2007; 20: 39-53.
7. Ayello EA. New evidence for an enduring wound-healing concept: moisture control. *J Wound Ostomy Continence Nurs* 2006; 33: S1-S2.
8. Koupil J, Brychta P, Horky D, Smola J, Prasek J. The influence of moisture wound healing on the incidence of bacterial infection and histological changes in healthy human skin after treatment of interactive dressings. *Acta Chir Plast* 2003; 45: 89-94.
9. Benbow M, Iosson G. A clinical evaluation of Urgotul to treat acute and chronic wounds. *Br J Nurs* 2004; 13: 105-9.
10. Balasubramani M, Kumar TR, Babu M. Skin substitutes: a review. *Burns* 2001; 27: 534-44.
11. Jones I, Currie L, Martin R. A guide to biological skin substitutes. *Br J Plast Surg* 2002; 55: 185-93.
12. Demling RH, DeSanti L. Management of partial thickness facial burns (comparison of topical antibiotics and bio-engineered skin substitutes). *Burns* 1999; 25: 256-61.
13. Vloemans AF, Soesman AM, Kreis RW, Middelkoop E. A newly developed hydrofibre dressing, in the treatment of partial-thickness burns. *Burns* 2001; 27: 167-73.
14. Fontana JD, de Souza AM, Fontana CK, Torriani IL, Moreschi JC, Gallotti BJ, et al. Acetobacter cellulose pellicle as a temporary skin substitute. *Appl Biochem Biotechnol* 1990; 24-25: 253-64.
15. Alvarez OM, Patel M, Booker J, Markowitz L. Effectiveness of a biocellulose wound dressing for the treatment of chronic venous leg ulcers: Results of a single center randomized study involving 24 patients. *Wounds* 2004; 16: 224-33.
16. Jung R, Kim Y, Kim HS, Jin HJ. Antimicrobial properties of hydrated cellulose membranes with silver nanoparticles. *J Biomater Sci Polym Ed* 2009; 20: 311-24.
17. Barud HS, Regiani T, Marques RFC, Lustri WR, Messaddeq Y, Ribeiro SJL. Antimicrobial Bacterial Cellulose-Silver Nanoparticles Composite Membranes. *J Nanomater* 2011. doi:10.1155/2011/721631.
18. de Santa Maria LC, Santos ALC, Oliveira PC, Barud HS, Messaddeq Y, Ribeiro SJL. Synthesis and characterization of silver nanoparticles impregnated into bacterial cellulose. *Materials Letters* 2009; 63: 797-9.
19. Maneerung T, Tokura S, Rujiravanit R. Impregnation of silver nanoparticles into biocellulose for antimicrobial wound dressing. *Carbohydr Polym* 2008; 72: 43-51.
20. Martinez-Gutierrez F, Thi EP, Silverman JM, de Oliveira CC, Svensson SL, Vanden Hoek A, et al. Antibacterial activity, inflammatory response, coagulation and cytotoxicity effects of silver nanoparticles. *Nanomedicine* 2012; 8: 328-36.
21. Lara HH, Garza-Trevino EN, Ixtapan-Turrent L, Singh DK. Silver nanoparticles are broad-spectrum bactericidal and virucidal compounds. *J Nanobiotechnology* 2011; 9: 30.
22. Pal S, Tak YK, Song JM. Does the antibacterial activity of silver nanoparticles depend on the shape of the nanoparticle? A study of the Gram-negative bacterium *Escherichia coli*. *Appl Environ Microbiol* 2007; 73: 1712-20.
23. Parsons D, Bowler PG, Myles V, Jones S. Silver antimicrobial dressings in wound management: A comparison of antibacterial, physical, and chemical characteristics. *Wounds* 2005; 17: 222-32.
24. Lansdown AB. Silver. I: Its antibacterial properties and mechanism of action. *J Wound Care* 2002; 11: 125-30.
25. Berry DP, Bale S, Harding KG. Dressings for treating cavity wounds. *J Wound Care* 1996; 5: 10-7.

26. Jones V, Grey JE, Harding KG. Wound dressings. *BMJ* 2006; 332: 777-80.
27. Baranoski S. Choosing a wound dressing, part 1. *Nursing* 2008; 38: 60-1.
28. Baranoski S. Choosing a wound dressing, part 2. *Nursing* 2008; 38: 14-5.
29. Parnklang T, Lamluua B, Gatemalaa H, Thammacharoena C, Kuimaleeb S, Lohwongwatanac B, et al. Shape transformation of silver nanospheres to silver nanoplates induced by redox reaction of hydrogen peroxide. *Mater Chem Phys* 2015; 153: 127-34;.
30. Nitinaivinij K, Parnklang T, Thammacharoen C, Ekgasita S, Wongravee K. Colorimetric determination of hydrogen peroxide by morphological decomposition of silver nanoprisms coupled with chromaticity analysis. *Anal Methods* 2014; 6: 9816-24.
31. Parnklang T, Lertvachirapaiboon C, Pienpinijtham P, Wongravee K, Thammacharoen C, Ekgasit S. H<sub>2</sub>O<sub>2</sub>-triggered shape transformation of silver nanospheres to nanoprisms with controllable longitudinal LSPR wavelengths. *RSC Advances* 2013; 3: 12886-94.
32. Wongravee K, Parnklang T, Pienpinijtham P, Lertvachirapaiboon C, Ozaki Y, Thammacharoen C, et al. Chemometric analysis of spectroscopic data on shape evolution of silver nanoparticles induced by hydrogen peroxide. *Phys Chem Chem Phys* 2013; 15: 4183-9.

### การศึกษาประสิทธิภาพทางคลินิกของวัสดุทำแผลชนิดใหม่ *Blue Nano Silver Biocellulose Ribbons* ในแผลชนิดโพรง

สุรเวช น้าหอม, ประไพ อริยประยูร, วิชัย ศรีมุนินทร์นิมิต

**ภูมิหลัง:** ในกระบวนการหายของแผลที่เหมาะสม วัสดุปิดแผลที่ใช้ต้องมีความสามารถในการฆ่าเชื้อ และการควบคุมความชุ่มชื้นของแผลที่พอดี วัสดุปิดแผลที่ดีต้องช่วยปรับให้สภาพแวดล้อมของแผลโดยการดูดซับสารคัดหลั่งจากแผลอย่างพอเหมาะ เพื่อให้เกิดความชุ่มชื้นที่เหมาะสม และมีความสามารถในการฆ่าเชื้อที่ครอบคลุม รวมถึงไม่ติดแผลเวลาทำการเปลี่ยนวัสดุทำแผล ไบโอะเซลลูโลสซึ่งผลิตจาก *Acetobacter xylinum* พบว่าสามารถให้ความชุ่มชื้นที่ดี ในขณะที่เดียวกันก็ดูดซับสารคัดหลั่งจากร่างกายได้ดีพอสมควร ซึ่งเมื่อรวมกับการผสมแร่เงินนาโนที่มีความสามารถในการฆ่าเชื้อทำให้เกิดเป็นวัสดุปิดแผลที่มีคุณสมบัติเหมาะสม การศึกษานี้เป็นการประเมินประสิทธิภาพทางคลินิกของวัสดุปิดแผลชนิดใหม่ *blue nano-silver biocellulose ribbon dressing (BNBR: BluRibbon, Novatec Healthcare, Thailand)* ในแผลชนิดโพรง

**วัตถุประสงค์:** เพื่อประเมินประสิทธิภาพของวัสดุปิดแผล BNBR ในการรักษาแผลโพรงที่เวลา 4 สัปดาห์

**วัสดุและวิธีการ:** ศึกษาในผู้ป่วย 24 คน ที่มีแผลเป็นลักษณะโพรงในคลินิกทำแผลแผนกผู้ป่วยนอก และทำการติดตามผู้ป่วยไปจนแผลหาย หรือไม่เกิน 4 สัปดาห์เพื่อประเมินประสิทธิภาพในการช่วยการหายของแผล โดยการเปรียบเทียบขนาดของแผลที่เปลี่ยนแปลงก่อนและหลังรักษาตามเวลาที่ใช้รักษา บันทึกขนาดแผลโดยใช้กล้องดิจิทัลและประเมินพื้นที่แผลโดยใช้โปรแกรม *Image J*

**ผลการศึกษา:** ผู้ป่วยทั้งหมด 24 คน มีแผลทั้งหมด 30 แผล อายุเฉลี่ย 47.6 ปี แผลมีขนาดเริ่มต้นเฉลี่ย 2.4 ตารางเซนติเมตร และลึก 1.4 เซนติเมตร วัสดุปิดแผล BNBR ช่วยในการลดขนาดพื้นที่ของแผลใน 90% ของแผลที่ทำการศึกษา (27 แผล) และ 97% ของแผลแสดงถึงความตื้นขึ้นของแผลอย่างมีนัยสำคัญภายหลัง 20.7 วันของการรักษาและผู้ป่วยทั้งหมดไม่รู้สึกเจ็บแผลตอนเปลี่ยนแผล

**สรุป:** วัสดุปิดแผล BNBR สามารถช่วยในการหายของแผลโพรงโดยลดขนาดทั้งพื้นที่แผลและความลึกของแผล คุณสมบัติการควบคุมความชุ่มชื้น และการฆ่าเชื้อของวัสดุปิดแผล BNBR เชื่อว่ามีส่วนช่วยในการหายของแผล ทั้งนี้ผลการศึกษานี้ทำให้สมควรพิจารณาทำการศึกษานในกลุ่มผู้ป่วยที่มีจำนวนมากขึ้นต่อไป