

Case Report

A Case Report: Central Retinal Vein Occlusion with Primary Pulmonary Hypertension

Navapol Kanchanaranya MD*,
Duangmontree Rojdamrongratana MD*, Gaanchisa Vongchaiyakit MD*

* Department of Ophthalmology, Faculty of Medicine, Thammasat University, Rangsit Campus, Pathumthani, Thailand

Objective: To describe a case of retinal vein occlusion with history of primary pulmonary hypertension.

Material and Method: Case report

Results: We report a case of ischemic central retinal vein occlusion (CRVO) with secondary macular edema in a 23-year-old woman with history of primary pulmonary hypertension. This patient was treated with intravitreal anti-vascular endothelial growth factor (anti-VEGF) for macular edema. Her vision improved after treatment.

Conclusion: We present ischemic CRVO with secondary macular edema, where primary pulmonary hypertension is thought to be the main risk factor. Treatment of macular edema, monthly follow-up, looking for sequential neovascularization and systemic control of primary pulmonary hypertension are crucial in restoring vision and preventing CRVO in the fellow eye.

Keywords: Primary pulmonary hypertension, Ischemic CRVO, Anti-VEGF drug

J Med Assoc Thai 2017; 100 (Suppl. 5): S269-S272

Full text. e-Journal: <http://www.jmatonline.com>

Retinal vein occlusion (RVO) is the common retinal vascular disease causing blurred vision after diabetic retinopathy⁽¹⁾, and often causes catastrophic consequences to quality of life^(2,3). RVO is classified according to where the obstruction of the venous blood flow is located. Occlusion of the central retinal vein at the level of the optic nerve is referred to as central retinal vein occlusion (CRVO). Occlusion at the primary superior or inferior branch involving approximately half of the retina is referred to as hemi-retinal vein occlusion (HRVO). Obstruction at any more distal branch of the retinal vein is referred to as branch retinal vein occlusion (BRVO)⁽⁴⁾. In this article, we are mainly interesting in CRVO, which can be subdivided to 2 groups: ischemic, and non-ischemic, with each having different clinical features and prognosis. Most of the patients are old age, however; it can be seen in young adults, and occasionally associated with a systemic disease. In young adults, systemic infections, idiopathic inflammation, hematologic disorder (systemic vasculitis, myeloproliferative disorders), and circulatory disorders are usually the causes, although many cases seem to

be idiopathic. It is advisable to refer patients with RVO especially less than 50 years of age for meticulous clinical evaluation^(5,6).

Primary pulmonary hypertension (PPH) is a progressive disease characterized by elevated pulmonary vascular resistance, results in increased right ventricular after load, which leads to decline in right-heart function. PPH usually occurs in young and middle-age women with unknown etiology. However, the current theories on pathogenesis believe in the abnormalities in interaction between endothelial and smooth-muscle cells⁽⁷⁾. There were some reports regarding CRVO associated with PPH that had no favorable results. This report will describe the course of this disease with modern treatment.

Case Report

A 23-year-old Thai female with history of PPH presented to the eye clinic with visual loss on her right eye for one week. She has been taken sildenafil and bosentan. Vital signs were normal. Ophthalmic examination showed that the best corrected visual acuity (BCVA) was 5/200 on the right eye and 20/20 on the left eye. Intraocular pressure of both eyes were normal. Cornea, iris, pupil and lens examination were unremarkable. Positive relative afferent pupillary defect (RAPD) was found on her right eye. The fundus examination on the right eye showed dilated and

Correspondence to:

Kanchanaranya N, Department of Ophthalmology, Faculty of Medicine, Thammasat University, Rangsit Campus, Pathumthani 12120, Thailand.

Phone: +66-2-9269957, Fax: +66-2-9869212

E-mail: Navapolk@gmail.com

tortuous retinal vessel, generalized flame shape hemorrhage, blurred disc margin and macular edema (ME) as shown in Fig. 1. The fundus examination on the left eye was normal. The optical coherent tomography (OCT) scan on her right macula showed macular edema as Fig. 2.

The patient was diagnosed with CRVO and macular edema. She was treated with intravitreal ranibizumab for 2 times on a month apart and consult her cardiologist for systemic control of PPH. After a month from last injection, the BCVA was 20/30 and central retinal thickness (CRT) was reduced from 632 to 218 μ m. The area of retinal hemorrhage were decreased (Fig. 3). Moreover, for 6 months, no macular edema was found as well as no other neovascularization and the patient's vision was stable even a year after.

Discussion

Central retinal vein occlusion (CRVO) has characteristic fundus of dilated and tortuous retinal veins, a swollen optic disc, intraretinal hemorrhages (blot and flame shaped), cotton wool spots and retinal edema. The visual loss occurs secondary to macular edema or ischemia. In most forms of central retinal vein occlusion, the occlusion is at or proximal to the lamina cribosa of the optic nerve⁽⁸⁾, where the central retinal

vein exits the eye. It is postulated that a thickened central retinal artery may impinge on the central retinal vein causing turbulence endothelial damage and thrombus formation. CRVO is now classified by 2 ends of the spectrum of disease, as non-ischemic and ischemic, which of each has implication for prognosis and treatment⁽⁴⁾. A number of parameters can be used to assess the severity of ischemia such as the degree of visual loss, presence of a relative afferent pupillary defect (RAPD), marked venous tortuosity and dilatation, extent of retinal capillary non-perfusion on fluorescein angiography, and electroretinography showing reduced b-wave amplitude, reduced b:a ratio, and prolonged b-wave implicit time⁽⁹⁾.

Pulmonary hypertension is defined as a mean pulmonary arterial pressure of more than 25 mmHg at rest. Primary pulmonary hypertension is a rare condition, with an incidence of 1 to 2 cases per million

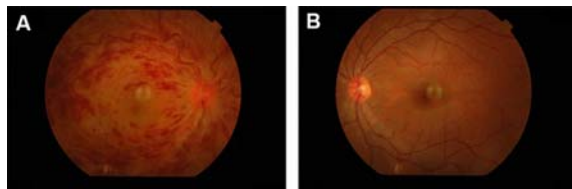


Fig. 1 Fundus examination of both eyes. A) Right eye, B) Left eye.

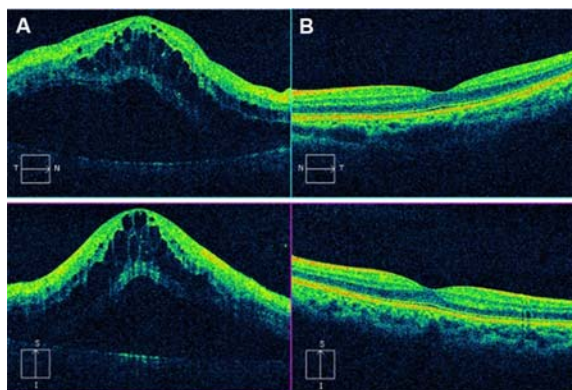


Fig. 2 OCT macula of both eyes. A) Right eye, B) Left eye.

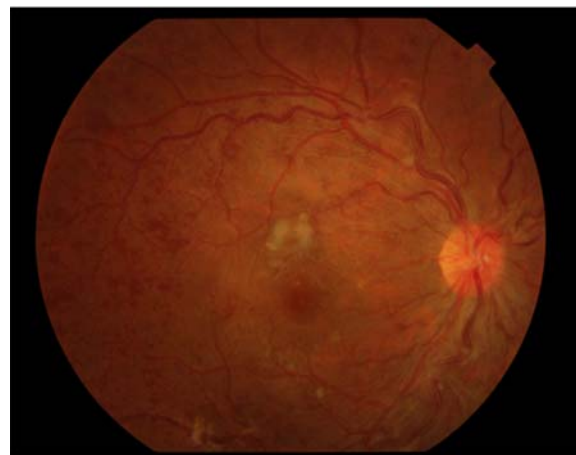

Fig. 3 Fundus photograph of left eye after 2 dose of intravitreal ranibizumab.

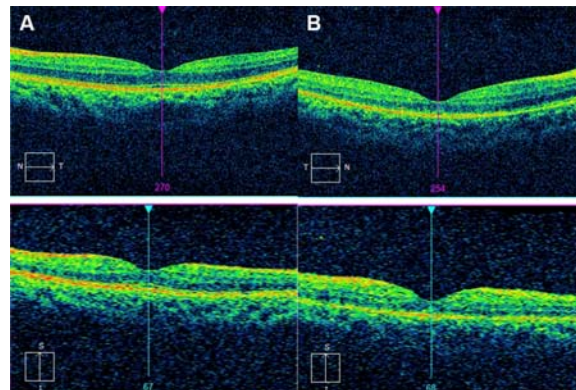


Fig. 4 OCT macula of both eyes after 2 dose of intravitreal ranibizumab

per year and a prevalence of 1,300 per million^(7,10). Although the pathogenesis is still ambiguous, the current theory believes that it is involved in the proliferation, migration of pulmonary vascular cells along the pulmonary arterial wall (i.e. endothelial cells, smooth muscle cells, myofibroblasts). There are many contributing factors not only the inflammation, pulmonary endothelial cell dysfunction, aberrant cell proliferation in the vascular wall, but also those several gene mutation. Because of decreasing of vascular diameter, the pulmonary vascular bed increases resistance and thus increases the workload of the right ventricle. These cycles are continued until the right heart cardiac output can no longer overcome the force of this resistance. As increasing of venous return volume, the venous pressure rises. This is the stagnation of venous flow associated with PPH^(11,12).

Therefore stagnation of venous outflow has been proposed as a probable cause of CRVO, this patient developed CRVO due to poor VA and positive RAPD. Pathophysiology due to the elevated venous pressure found in PPH is responsible for decreased choroidal perfusion and reduced venous blood outflow from the eye. This would explain the clinical findings of central retinal vein occlusion in this patient⁽¹³⁾. Senthil S. et al reported a case of patient who had PPH turned to have CRVO with macular edema after, they also were treated with two doses of the intravitreal bevacizumab, and both BCVA and CRT were much improved⁽¹⁴⁾.

Nonetheless, there are few case reports showed that sildenafil could cause CRVO as well. Usually the patients presented with unilateral, sudden onset, painless visual loss following the use of sildenafil though the symptoms mostly occurred in hours⁽¹⁵⁻¹⁷⁾.

Conclusion

Unilateral CRVO with secondary macula edema, where PPH was thought to be the main risk factor. Close follow-up looking for sequential complication such as neovascularization is necessary. Anti-VEGF for macula edema and systemic control of primary pulmonary hypertension are crucial to restore vision and prevent scenario in the fellow eye

What is already known on this topic?

Central retinal vein occlusion (CRVO) is the common retinal vascular disease causing blurred vision after diabetic retinopathy. Most of the patients are old age. Atherosclerotic risk factors are thought to affect vascular flow or cause retinal vascular wall

abnormalities. However, it can be seen in young adults, and occasionally associated with a systemic disease. It is advisable to refer patients with CRVO especially less than 50 years of age for meticulous clinical evaluation.

What this study adds?

We present a 23-year-old female with unilateral central retinal vein occlusion with secondary macula edema, where primary pulmonary hypertension is thought to be the main risk factor. Stagnation of venous outflow has been proposed as a probable cause of CRVO. Anti-VEGF for macula edema and systemic control of primary pulmonary hypertension are crucial to restore vision and prevent scenario in the fellow eye.

Acknowledgements

We would like to thank our colleague: Waraporn Tiyanon, MD (Cardiologist), Bunyaporn Chandrachamnong, MD, for help examine patient in the retina clinic, Thammasat University Hospital and Miss Sirineen Muangsiri for her help in manuscript revision.

Potential conflicts of interest

None.

References

1. Cugati S, Wang JJ, Knudtson MD, Rochtchina E, Klein R, Klein BE, et al. Retinal vein occlusion and vascular mortality: pooled data analysis of 2 population-based cohorts. *Ophthalmology* 2007; 114: 520-4.
2. Deramo VA, Cox TA, Syed AB, Lee PP, Fekrat S. Vision-related quality of life in people with central retinal vein occlusion using the 25-item National Eye Institute Visual Function Questionnaire. *Arch Ophthalmol* 2003; 121: 1297-302.
3. McIntosh RL, Rogers SL, Lim L, Cheung N, Wang JJ, Mitchell P, et al. Natural history of central retinal vein occlusion: an evidence-based systematic review. *Ophthalmology* 2010; 117: 1113-23.
4. Karia N. Retinal vein occlusion: pathophysiology and treatment options. *Clin Ophthalmol* 2010; 4: 809-16.
5. Yau JW, Lee P, Wong TY, Best J, Jenkins A. Retinal vein occlusion: an approach to diagnosis, systemic risk factors and management. *Intern Med J* 2008; 38: 904-10.
6. Fong AC, Schatz H. Central retinal vein occlusion

- in young adults. *Surv Ophthalmol* 1993; 37: 393-417.
7. Gaine SP, Rubin LJ. Primary pulmonary hypertension. *Lancet* 1998; 352: 719-25.
 8. Mitchell P, Smith W, Chang A. Prevalence and associations of retinal vein occlusion in Australia. The Blue Mountains Eye Study. *Arch Ophthalmol* 1996; 114: 1243-7.
 9. Hayreh SS. Prevalent misconceptions about acute retinal vascular occlusive disorders. *Prog Retin Eye Res* 2005; 24: 493-519.
 10. Rich S, Rubin L, Walker AM, Schneeweiss S, Abenheim L. Anorexigens and pulmonary hypertension in the United States: results from the surveillance of North American pulmonary hypertension. *Chest* 2000; 117: 870-4.
 11. Saran BR, Brucker AJ, Bandello F, Verougstraete C. Familial primary pulmonary hypertension and associated ocular findings. *Retina* 2001; 21: 34-9.
 12. Bhan A, Rennie IG, Higenbottam TW. Central retinal vein occlusion associated with primary pulmonary hypertension. *Retina* 2001; 21: 83-5.
 13. Beck R, Eckard A, Ewert R, Guthoff R. [Retinal diseases with primary pulmonary hypertension]. *Ophthalmologie* 2003; 100: 732-5.
 14. Senthil S, Kaur B, Jalali S, Garudadri C. Secondary open-angle glaucoma and central retinal vein occlusion in a patient with primary pulmonary hypertension. *Ophthalmic Surg Lasers Imaging* 2009; 40: 50-3.
 15. Obiudu H, Chuku A, Metu K. Central retinal vein occlusion associated with Sildenafil (Viagra). *Niger J Surg* 2010; 16: 13-6.
 16. Azzouni F, Abu sK. Are phosphodiesterase type 5 inhibitors associated with vision-threatening adverse events? A critical analysis and review of the literature. *J Sex Med* 2011; 8: 2894-903.
 17. Nawaiseh B, Shobaki A, Hassouneh A, Bataineh I, Al-Jaar M. Central retinal vein occlusion after sildenafil citrate (Viagra) use. *J Roy Med Serv* 2006; 13: 46-7.

รายงานผู้ป่วย: โรคเส้นเลือดดำในจอตาอุดตันร่วมกับภาวะความดันหลอดเลือดในปอดสูง

ฉวพล กาญจนารักษ์, ดวงมนตรี โรจนดำรงรัตนา, กัญญชัชชา วงศ์ไชยกิจ

ภูมิหลัง: โรคเส้นเลือดดำในจอตาอุดตันเป็นโรคของจอตาที่พบได้บ่อยเป็นอันดับ 2 รองจากโรคเบาหวานขึ้นจอตา ส่วนใหญ่พบในผู้สูงอายุที่มีภาวะความดันโลหิตสูงร่วมด้วย และเป็นส่วนน้อยที่พบในผู้ป่วยอายุน้อย รายงานผู้ป่วยนี้แสดงโรคเส้นเลือดดำในจอตาอุดตันในผู้ป่วยอายุน้อยและร่วมกับภาวะหลอดเลือดในปอดสูง

วัตถุประสงค์: รายงานผู้ป่วยเส้นเลือดดำจอตาอุดตันในผู้ป่วยโรคความดันหลอดเลือดในปอดสูงชนิดปฐมภูมิ

รูปแบบการศึกษา: รายงานผู้ป่วย

ผลการศึกษา: ผู้ป่วยหญิงอายุ 23 ปี มีประวัติเป็นโรคความดันของหลอดเลือดในปอดสูงชนิดปฐมภูมิ ตรวจพบเส้นเลือดดำจอตาอุดตันร่วมกับจลรัสภาพซัคตวม ผู้ป่วยได้รับการรักษาโดยการฉีดยา anti-vascular endothelial growth factor (anti-VEGF) เข้าน้ำวุ้นตา ผู้ป่วยมีค่าสายตาดีขึ้นหลังได้รับการรักษา

สรุป: ผู้ป่วยเส้นเลือดดำจอตาอุดตันร่วมกับจลรัสภาพซัคตวม ซึ่งเกิดจากโรคความดันหลอดเลือดในปอดสูง มีแนวทางการรักษาและป้องกันการเกิดเส้นเลือดดำจอตาอุดตันในตาอีกข้างได้แก่ การรักษาภาวะจลรัสภาพซัคตวม ตรวจดูข้อแทรกซ้อนเช่นเส้นเลือดงอกใหม่ และควบคุมโรคความดันของหลอดเลือดในปอดสูง