

Case Report

Cytomegalovirus Colitis in an End-Stage Renal Disease Patient Presenting with Lower Gastrointestinal Bleeding

Asawin Sudcharoen MD*, Piyanant Chonmaitree MD*,
Piyakorn Poonyam MD*, Therdkiat Trongwongsa MD**

*Department of Medicine, Faculty of Medicine, Srinakharinwirot University, Nakhon Nayok, Thailand

**Department of Pathology, Faculty of Medicine, Srinakharinwirot University, Nakhon Nayok, Thailand

The authors report a case of cytomegalovirus colitis which is one of uncommon causes of lower gastrointestinal bleeding in a patient with end-stage renal disease receiving hemodialysis. Our patient presented with recurrent episodes of massive hematochezia within 2 months. He had the underlying end-stage renal disease, ischemic heart disease, cerebrovascular disease, hypertension and gout. Colonoscopy revealed multiple clean base ulcers at rectum and sigmoid colon. An active bleeding lesion was rectal ulcer with non bleeding visible vessel which was successfully treated with hemoclipping. The diagnosis of cytomegalovirus colitis was confirmed by pathology from colonic tissues which showed compatible patterns of cytopathic change. Human immunodeficiency virus serology was negative. He was treated with ganciclovir intravenously for 1 week after the pathological finding was reported. To our knowledge, cytomegalovirus infection should be considered as causative pathogen of colitis and colonic ulcers in end-stage renal disease patients.

Keywords: Cytomegalovirus, Colitis, Colonic ulcer, Lower gastrointestinal bleeding

J Med Assoc Thai 2016; 99 (Suppl. 8): S237-S243

Full text. e-Journal: <http://www.jmatonline.com>

Cytomegalovirus (CMV) has been recognized as causative pathogen in patient with immunocompromised states such as acquired immunodeficiency syndrome (AIDS), solid organ and stem cell transplantation. CMV gastrointestinal disease following reactivation include esophagitis, gastritis, and enterocolitis. The prevalence of CMV intestinal disorders are considered rare in patients without immunocompromised conditions as described above⁽¹⁻³⁾. We diagnosed a case of CMV colitis in elderly man with end-stage renal disease presented with recurrent massive lower gastrointestinal bleeding. CMV infection should be considered as one of treatable causes of colitis not only in immunocompromised hosts but also in elderly patients with multiple comorbidities especially chronic kidney disease or end-stage renal disease.

Case Report

A 72-year-old Thai male presented with 2 episodes of lower gastrointestinal bleeding within 2

months. For the first time, he was admitted due to congestive heart failure and developed massive hematochezia during admission. Colonoscopy revealed a 0.8 cm of clean-base ulcer at the lower rectum just above the dentate line and internal hemorrhoid. The biopsy was not performed because he was diagnosed with hemorrhagic rectal ulcer syndrome. He was treated with sucralfate enema. After colonoscopy, bleeding was stopped and patient was discharged seven days later. He was readmitted due to a rectal bleeding at two months later. He denied history of diarrhea, fever, or abdominal pain. His medical problems were end-stage renal disease receiving regular hemodialysis twice a week, ischemic cardiomyopathy treated with dual antiplatelet therapy, cerebrovascular disease, hypertension, and gout. On admission, physical examination revealed stable hemodynamics, mildly pale, mild abdominal distension, and fresh blood per rectum. Initial laboratory investigation showed hemoglobin 8.6 g/dL, white blood cell 12,390/mm³, platelet 75,000/mm³, prothrombin time 13.1 seconds (normal range 9.5-13.5 seconds), activated partial thromboplastin time 44 seconds (normal range 21.5-29 seconds), blood urea nitrogen 69.5 mg/dl, creatinine 7.61 mg/dl, other investigations were unremarkable. His baseline investigations were hemoglobin 10 g/dL, normal white blood cell count, platelet count and

Correspondence to:

Sudcharoen A, Department of Medicine, Faculty of Medicine, Srinakharinwirot University, 62 Moo 7, Ongkharak, Nakhon Nayok 26120, Thailand.

Phone: +66-84-1601102

E-mail: a_pvero@yahoo.com

coagulogram. Colonoscopy revealed five ulcers at the lower rectum (four ulcers were clean base and one ulcer with non bleeding visible vessel (NBVV) and five clean base 0.3-1 cm ulcers at the sigmoid colon (Fig. 1-3). Hemoclipping was performed at rectal ulcer with NBVV for hemodynamic stabilization. Histopathology report from rectal ulcer showed active colitis with few atypical large cells. Additional cytomegalovirus

(CMV) staining showed scatter positive nuclei (Fig. 5). We made a diagnosis of cytomegalovirus colitis. Human immunodeficiency virus (HIV) serology was negative. He was treated with ganciclovir 1.25 mg/kg intravenously after hemodialysis for 1 week after the pathological finding was reported (at the third week of admission). Unfortunately, this patient died from hospital acquired pneumonia and respiratory failure after receiving ganciclovir about 1 week.

Discussion and review of the literature

Cytomegalovirus (CMV) can affect any parts of the gastrointestinal tract. Colitis is the most common manifestation of CMV gastrointestinal disease described in patient with HIV infection, a history of organ transplant, use of systemic steroid, or those receiving chemotherapy. CMV disease in immunocompromised hosts other than HIV infection or immunosuppressive uses appears to be more common than previously thought, which may be partly due to immune dysfunction related to comorbidities such as elderly, kidney disease, or diabetes mellitus⁽¹⁻³⁾. Renal failure is the most common concomitant disease in the immunocompetent host⁽⁴⁾. There are two possible reasons explained why patient with renal failure prone to develop CMV related disease. The first, chronic kidney disease (CKD) or end-stage renal disease (ESRD) patients have risk to expose or develop CMV infection such as frequent blood

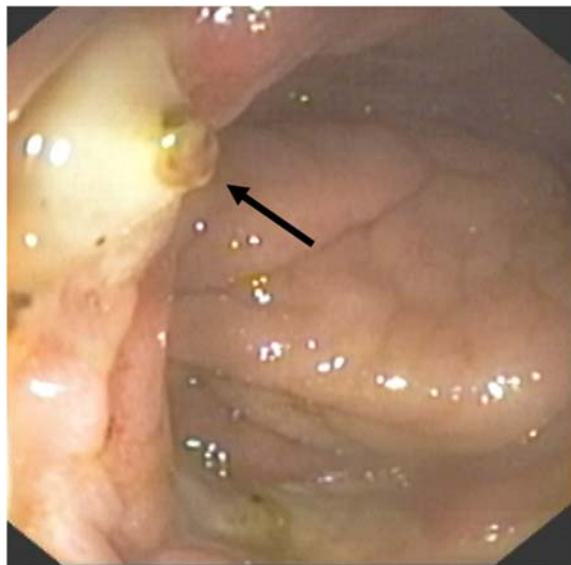


Fig. 1 Endoscopic finding revealed rectal ulcer with non bleeding visible vessel.

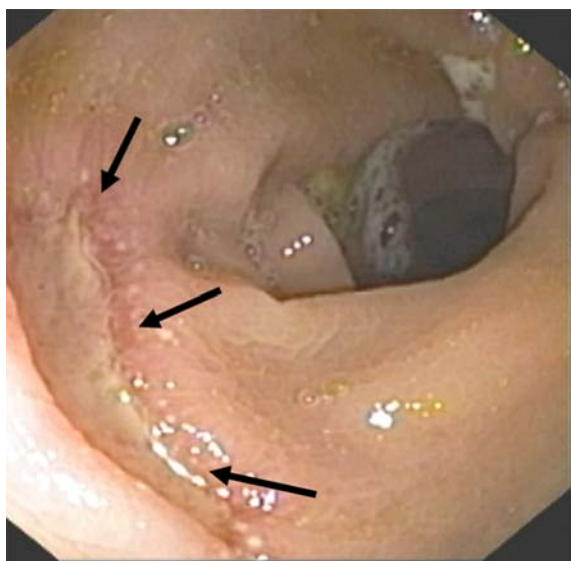


Fig. 2 Endoscopic finding showed large clean-base ulcer at the rectum.

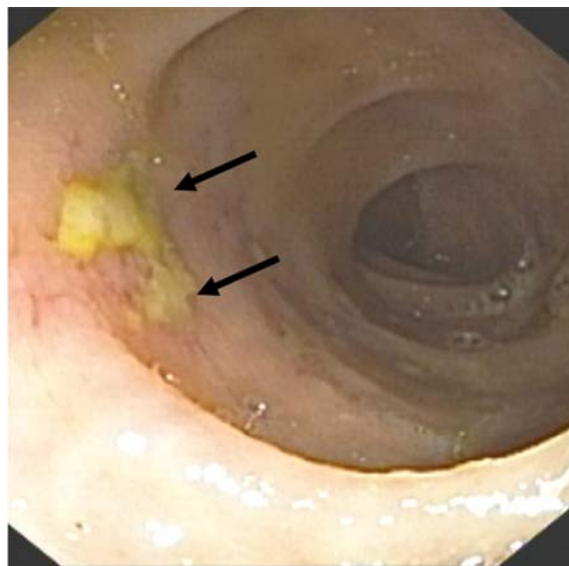


Fig. 3 Endoscopic finding of clean-base ulcer at the sigmoid colon.

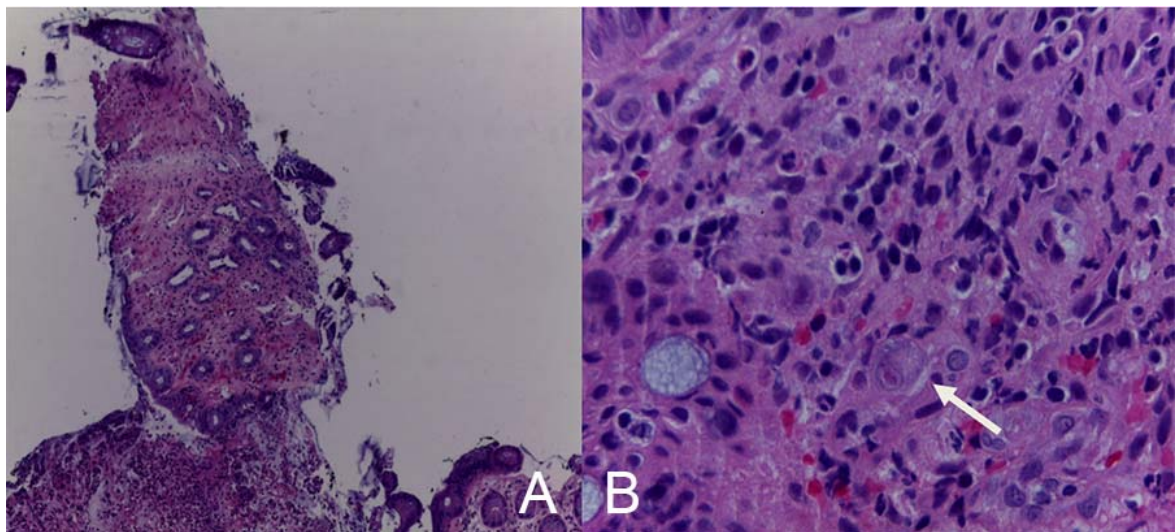


Fig. 4 Histopathology showed ischemic pattern of colonic tissue (A) and typical cytomegalic change and basophilic intranuclear inclusion bodies with halo (typical cytomegalic change or owl-eye appearance) (B).

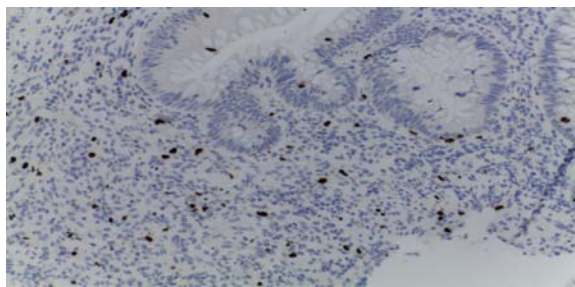


Fig. 5 Immunochemical staining for CMV showed scattered positive nuclei.

transfusions and contaminated dialysis equipment⁽⁵⁾. The second, these patients may have immune dysfunction due to uremia and dialysis related dysfunction of B-cell and T-cell lymphocyte, impaired cytokine regulation and perturbation of mucosal immunity⁽⁶⁾. We found 11 case reports of CMV colitis with lower gastrointestinal bleeding (LGIB) in CKD or ESRD from literature as described in Table 1^(5,7-11). All patients were confirmed their diagnosis of CMV colitis from histopathology. Six patients (51.5%) were male. The mean age was 75 years (range 57-77 years). The comorbidities of all patients were not identified but the result from 1 study which included 9 patients revealed diabetes mellitus and hypertension as major comorbidities⁽⁵⁾. Almost patients received treatment with ganciclovir and had a favorable outcome. Ko et al, who performed a case-control study of CMV colitis in immunocompetent adult patients, described that steroid use and red blood cell transfusion within 1 month of

the diagnosis of colitis are independent risk factors for the development of colitis⁽¹²⁾. The site of CMV gastrointestinal disease in patients with CKD/ESRD can occur in all area of the alimentary tract. In CMV colitis or colonic ulcer disease, the common presenting symptoms include fever, diarrhea, gastrointestinal bleeding, and abdominal pain. Colonic perforation is an uncommon but potentially fatal complication which occurs in about 1% of the cases⁽¹³⁻¹⁵⁾. Fever or constitutional symptom may be not found in CKD/ESRD patients⁽⁵⁾. Our patient presented with colonic ulcer bleeding which is a common manifestation of CMV gastrointestinal disease and also had a background that predisposed to develop CMV colitis. We suspected the cause of LGIB in our patient from CMV colitis because colonoscopic finding showed NBVV at colonic ulcer. Colonoscopic features of CMV colitis are various in CKD or ESRD patients. Shallow-erythematous erosion or localized ulcers are the common features in this condition but difficult to differentiate from colonic ischemia⁽⁸⁾. Less common lesions such as plaques, nodules, polyps, and mass mimicking colorectal carcinoma have also been reported^(1,15,17,18). Biopsies are essential because similar findings can occur in other types of colitis. Pathological examination typically reveals diffuse ulcerations and necrosis with scattered CMV inclusions⁽¹⁹⁾. Anti-CMV IgG and IgM serum level have been previously widely used to diagnose CMV infection but they are not the gold standard test for diagnosis and cannot distinguish acute infection from reactivation. The viral antibody

Table 1. Characteristics of 11 chronic kidney disease or end-stage renal disease patients with lower gastrointestinal bleeding from Cytomegalovirus colitis

Number	Ages (years)	Sex	Comorbidity	Presentation	Colonoscopic/surgical finding	Treatment	Outcome	Reference
1	75	Female	ND	LGIB	Tumor with bleeding	Antiviral	Survived	5
2	75	Male	ND	LGIB	Multiple shallow ulcers	Antiviral	Survived	5
3	66	Female	ND	LGIB	Board based ulcer with edematous surrounding fold	Antiviral	Survived	5
4	77	Male	ND	LGIB	Right hemicolectomy: uneven surface of colonic mucosa	Antiviral	Died	5
5	74	Male	ND	LGIB	Diffused ulceration of mucosa	Antiviral	Survived	7
6	59	Female	ND	LGIB	Severe inflamed mucosa and derosions	ND	Survived	7
7	57	Female	ND	LGIB	Large polypoid lesion	Antiviral	Survived	8
8	72	Male	COPD, T2DM CV disease	LGIB	Exudate, inflamed mucosa and pseudopolyps at right colon	Antiviral	Survived	9
9	74	Female	ND	LGIB, Abdominal pain	Pancolitis	Antiviral	Died	10
10	71	Female	ND	LGIB, Diarrhea	Multiple colonic ulcers	Antiviral	Survived	10
11	56	Male	ND	LGIB, Diarrhea Abdominal pain	Diffused ulcerations at sigmoid colon Multiple deep ulcerations at cecum and ascending colon	Antiviral	Survived	11

ND = Not describe; LGIB = Lower gastrointestinal bleeding; COPD = Chronic obstructive pulmonary disease; T2DM = Type 2 diabetes mellitus; CV = Cardiovascular

test is sometimes insufficient to diagnose CMV colitis because their ability to produce antibody is often suppressed from immunocompromised status. The detection of the antigen DNA and RNA is helpful for a correct diagnosis of CMV colitis^(19,20).

Advanced age (more than 55 years), male sex, pregnancy, chronic renal failure, untreated non-hematological malignancy, and diabetes may associate with unfavorable survival outcome, so patients with these risk factors should be considered antiviral therapy⁽⁴⁾. Not only CKD or ESRD but patients with critical illness in the intensive care unit setting who developed acute kidney injury also has the high risk of active CMV infection^(20,21). This patient was treated with antiviral therapy because he had several poor prognostic conditions. Ganciclovir is currently used as a standard antiviral drug for the treatment of CMV infections. Unfortunately, ganciclovir can lead to serious side effects, including myelosuppression, neurological disorders, hepatotoxicity, and nephrotoxicity. Dose adjustment for renal function are recommended in every patients, especially in CKD/ESRD patients. Many literatures recommended antiviral therapy for immunocompetent patients due to poor prognosis in the absence of antiviral treatment⁽²²⁻²⁴⁾.

Conclusion

We present a case of CMV colitis in an elderly end-stage renal disease patient who presented with recurrent and massive lower gastrointestinal bleeding. He received endoscopic treatment with hemoclipping to stop bleeding and antiviral treatment after pathological finding was reported. This case highlights the importance of recognizing CMV infection as a cause of colonic disease in CKD/ESRD patients.

What is already known on this topic?

CMV disease in CKD/ESRD patient appears to be more common than previously thought, which may be partly due to immune dysfunction related to advanced age and other comorbidities. Colonoscopy can reveal a range of features related to CMV colitis. Shallow-erythematous erosion or localized ulcers are the common features in this condition but difficult to differentiate from colonic ischemia. Biopsies are essential because similar findings can occur in other types of colitis. Pathological examination typically reveals diffuse ulcerations and necrosis with scattered CMV inclusions. Ganciclovir is currently used as a standard antiviral drug for the treatment of CMV infections.

What this study adds?

This patient was a case report of cytomegalovirus colitis in CKD/ESRD patient presented with recurrent episodes of colonic ulcer bleeding. CMV infection should be considered as one of the treatable cause of colitis in this host, especially in elderly patient with multiple full stop comorbidities.

Potential conflict of interest

None.

References

1. Karigane D, Takaya S, Seki Y, Mastumoto Y, Onose A, Kosakai A, et al. Cytomegalovirus enteritis in immunocompetent subjects: a case report and review of the literature. *J Infect Chemother* 2014; 20: 325-9.
2. Lancini D, Faddy HM, Flower R, Hogan C. Cytomegalovirus disease in immunocompetent adults. *Med J Aust* 2014; 201: 578-80.
3. Momin N, Telisinghe PU, Chong VH. Cytomegalovirus colitis in immunocompetent patients. *Singapore Med J* 2011; 52: e170-2.
4. Galiatsatos P, Shrier I, Lamoureux E, Szilagyi A. Meta-analysis of outcome of cytomegalovirus colitis in immunocompetent hosts. *Dig Dis Sci* 2005; 50: 609-16.
5. Chen YM, Hung YP, Huang CF, Lee NY, Chen CY, Sung JM, et al. Cytomegalovirus disease in nonimmunocompromised, human immuno-deficiency virus-negative adults with chronic kidney disease. *J Microbiol Immunol Infect* 2014; 47: 345-9.
6. Hauser AB, Stingham AE, Kato S, Bucharles S, Aita C, Yuzawa Y, et al. Characteristics and causes of immune dysfunction related to uremia and dialysis. *Perit Dial Int* 2008; 28 (Suppl 3): S183-7.
7. Esforzado N, Poch E, Almirall J, Bombi JA, Lopez-Pedret J, Revert L. Cytomegalovirus colitis in chronic renal failure. *Clin Nephrol* 1993; 39: 275-8.
8. Falagas ME, Griffiths J, Prekezes J, Worthington M. Cytomegalovirus colitis mimicking colon carcinoma in an HIV-negative patient with chronic renal failure. *Am J Gastroenterol* 1996; 91: 168-9.
9. Rankin A, Cuthill K, Subesinghe M, Goldsmith D. Life-threatening rectal bleeding due to cytomegalovirus colitis in a haemodialysis patient. *NDT Plus* 2009; 2: 239-41.
10. Ng KL, Ho J, Ng HS, Luman W. Gastrointestinal Cytomegalovirus infection in non-human immunodeficiency virus infected patients. *Med J*

- Malaysia 2003; 58: 337-44.
11. Kim SH, Kim YS, Kim HW, Yoon HE, Kim HK, Kim YO, et al. A case of cytomegalovirus colitis in an immunocompetent hemodialysis patient. *Hemodial Int* 2011; 15: 297-300.
 12. Ko JH, Peck KR, Lee WJ, Lee JY, Cho SY, Ha YE, et al. Clinical presentation and risk factors for cytomegalovirus colitis in immunocompetent adult patients. *Clin Infect Dis* 2015; 60: e20-6.
 13. Harano Y, Kotajima L, Arioka H. Case of cytomegalovirus colitis in an immunocompetent patient: a rare cause of abdominal pain and diarrhea in the elderly. *Int J Gen Med* 2015; 8: 97-100.
 14. Hwang N, Kim EH, Han SY, Lee S, Lee SJ, Lee SH, et al. Severe cytomegalovirus colitis with hemolytic anemia mimicking travelers' diarrhea. *Int J Infect Dis* 2015; 37: 104-6.
 15. Shah R, Vaidya G, Kalakonda A, Manocha D, Rawlins S. Cytomegalovirus colitis mimicking rectal carcinoma in a young immunocompetent patient. *ACG Case Rep J* 2015; 2: 165-7.
 16. Hasegawa T, Aomatsu K, Nakamura M, Aomatsu N, Aomatsu K. Cytomegalovirus colitis followed by ischemic colitis in a non-immunocompromised adult: a case report. *World J Gastroenterol* 2015; 21: 3750-4.
 17. Jacob S, Zayyani NR. Cytomegalovirus colitis masquerading as rectal malignancy in an immunocompetent patient. *Indian J Pathol Microbiol* 2015; 58: 80-2.
 18. Seo TH, Kim JH, Ko SY, Hong SN, Lee SY, Sung IK, et al. Cytomegalovirus colitis in immunocompetent patients: a clinical and endoscopic study. *Hepatogastroenterology* 2012; 59: 2137-41.
 19. Goodman AL, Murray CD, Watkins J, Griffiths PD, Webster DP. CMV in the gut: a critical review of CMV detection in the immunocompetent host with colitis. *Eur J Clin Microbiol Infect Dis* 2015; 34: 13-8.
 20. Chan KS, Yang CC, Chen CM, Yang HH, Lee CC, Chuang YC, et al. Cytomegalovirus colitis in intensive care unit patients: difficulties in clinical diagnosis. *J Crit Care* 2014; 29: 474-6.
 21. Farah Musa AR, Fulop T, Kokko K, Kanyicska B, Lewin JR, Csongradi E. Cytomegalovirus colitis in a critically ill, dialysis-dependent, acute kidney injury patient without immunosuppressive therapy. *Clin Nephrol* 2015; 84: 44-9.
 22. Jacobson MA. Ganciclovir therapy for severe cytomegalovirus infection in immunocompetent patients. *Clin Infect Dis* 1997; 25: 1487-8.
 23. Patel SM, Cohen P, Pickering MC, Gazzard BG, Andreyev J. Successful treatment of acute haemorrhagic cytomegalovirus colitis with ganciclovir in an individual without overt immunocompromise. *Eur J Gastroenterol Hepatol* 2003; 15: 1055-60.
 24. Klauber E, Briski LE, Khatib R. Cytomegalovirus colitis in the immunocompetent host: an overview. *Scand J Infect Dis* 1998; 30: 559-64.

ลำไส้ใหญ่อักเสบจาก Cytomegalovirus ผู้ป่วยโรคไตเรื้อรังระยะสุดท้ายที่แสดงอาการเลือดออกจากรังไข่ลำไส้ใหญ่ส่วนล่าง

อัศวิน สุคเจริญ, เปียนท์ หนไมตรี, ปิยกรณ พูลแย้ม, เทอดเกียรติ ตรวงวงศา

ผู้เขียนบรรยายผู้ป่วยลำไส้ใหญ่อักเสบจาก Cytomegalovirus ซึ่งเป็นหนึ่งในสาเหตุที่พบบ่อยของภาวะเลือดออก จากทางเดินอาหาร ส่วนล่างโรคไตเรื้อรังระยะสุดท้ายที่ได้รับการบำบัดทดแทนไตด้วยการฟอกเลือด ผู้ป่วยมีภาวะเลือดออกจากรังไข่ลำไส้ใหญ่ส่วนล่าง 2 ครั้ง ในระยะเวลา 2 เดือน ผู้ป่วยมีโรคประจำตัวเป็นโรคไตเรื้อรังระยะสุดท้าย โรคหัวใจขาดเลือดโรคหลอดเลือดสมอง โรคความดันโลหิตสูงและโรคเกาต์ การส่องกล้องลำไส้ใหญ่พบว่ามีแผลหลายแผลที่ลำไส้ใหญ่ส่วนเรกตัมและซิกมอยด์ แผลที่มีลักษณะของเส้นเลือดที่กินแผลที่ตำแหน่งลำไส้ใหญ่ ส่วนเรกตัมได้รับการรักษาด้วย Hemoclipping การตรวจทางพยาธิวิทยายืนยันการวินิจฉัยการวินิจฉัยโรคลำไส้ใหญ่อักเสบจาก Cytomegalovirus โดยแสดงรูปแบบการเปลี่ยนแปลงของเซลล์ที่เข้ากับภาวะดังกล่าว ผลการตรวจเชื้อเอชไอวีเป็นลบ ผู้ป่วยได้รับการรักษาด้วยยา ganciclovir ทางหลอดเลือดดำเป็นเวลา 1 สัปดาห์หลังจากที่ทราบผลรายงานทางพยาธิวิทยา การติดเชื้อ Cytomegalovirus เป็นสาเหตุที่ควรคำนึงถึงว่าเป็นสาเหตุ แผลในลำไส้ใหญ่ในผู้ป่วยโรคไตเรื้อรังระยะสุดท้ายที่มาด้วยอาการเลือดออกจากรังไข่ลำไส้ใหญ่ส่วนล่าง
