

Case Report

Spinal Cord Bypass Surgery Using Peripheral Nerve Transfers to Restore Elbow Flexion in a Pediatric Patient with Central Cervical Cord Syndrome

Bunpot Sitthinamsuwan MD, MSc*,
Akkapong Nitising MD*, Sarun Nunta-Aree MD, PhD*

* Division of Neurosurgery, Department of Surgery, Faculty of Medicine Siriraj Hospital, Mahidol University, Bangkok, Thailand

Background: Spinal cord bypass surgery (SCBS) is a procedure for restoration of organ function following spinal cord injury (SCI). Nerve transfer (neurotization) is a common operation in patients with brachial plexus injury. It can be also used for SCBS in patients with SCI.

Objective: To report operative method and surgical outcome of nerve transfer in a patient with cervical SCI

Material and Method: The authors report a 6-year-old patient with central cervical cord injury without spontaneous neurological recovery. Physical examination showed asymmetrical motor deficit of both upper extremities.

Results: Double fascicular transfer for elbow flexion was performed on the right side and spinal accessory to musculocutaneous nerve transfer with sural nerve graft interposition was done in order to restore left elbow flexion. The patient could perform right elbow flexion (MRC Grade 3) at five months following the operations.

Conclusion: To the authors' knowledge, this case is the first report of SCBS using nerve transfer in patients with SCI in Thailand.

Keywords: Spinal cord bypass surgery, Nerve transfer, Neurotization, Spinal cord injury, Functional restoration

J Med Assoc Thai 2017; 100 (Suppl. 3): S223-S230

Full text. e-Journal: <http://www.jmatonline.com>

Several patients suffer from neurological impairment and disability caused by spinal cord dysfunction. Etiology of spinal cord dysfunction is various, including spinal cord injury (SCI), vascular malformation, neoplasm, infection, degenerative disease, spinal cord infarction, transverse myelitis and multiple sclerosis⁽¹⁻³⁾. Of them, SCI is one of the common causes. Even though appropriate treatment is accomplished, a significant number of patients with SCI have limited functional recovery with time. They still agonize from irreversible neurological disability and their quality of life is inevitably impaired⁽⁴⁾.

Spinal cord bypass surgery (SCBS) is an interesting concept for functional restoration in patients with SCI. The major principle of SCBS is transfer of functioning nerve fascicles above the level of SCI to restore function of nerves below level of SCI⁽⁵⁾. The present authors commonly performed nerve

transfer (neurotization) for functional restoration in patients with brachial plexus and peripheral nerve injuries. Recently, we initiated this operation in SCI patients. This article aims to report a patient with central cord syndrome caused by SCI who underwent SCBS by using nerve transfer. Surgical techniques and review of the literature in terms of SCBS are also described.

Case Report

A 6-year-old boy developed neck and back pain with progressive deterioration of motor function of bilateral upper extremities within few hours following unintentional hit by his friend. Physical examination revealed bibrachial weakness, more severe on the left side. Motor function of both lower extremities was normal. MRI of the spine showed hypersignal intensity of the spinal cord along C2-C6 vertebral levels. There was neither spinal cord compression nor abnormality of thoracic and lumbosacral spinal cord. SCI with central cord syndrome was diagnosed. The patient was treated conservatively without additional functional recovery.

Electrodiagnostic study at 8 months after the onset of injury demonstrated normal motor, sensory and F-waves responses of the right median and ulnar

Correspondence to:

Sitthinamsuwan B, Division of Neurosurgery, Department of Surgery, Faculty of Medicine Siriraj Hospital, Mahidol University, Bangkok 10700, Thailand.

Phone: +66-2-4198003, Fax: +66-2-4113006

E-mail: bunpotsi@yahoo.com

nerves. There was no motor response of the left median and ulnar nerves, whereas sensory responses of the left ulnar nerve showed normal amplitude with slight slow conduction velocity. The results indicated axonal motor neuropathy of bilateral cervical nerve roots, more severe on the left and maximum at C5, C6 and C7. The patient was referred to the first author (BS) at 9 months after the onset of injury. There was no more functional recovery since the time of injury. Motor power of bilateral deltoid, supra- and infraspinatus, biceps brachii and triceps brachii muscles were grade 0/5. Motor functions of wrist flexors, wrist extensors, finger flexors, finger extensors and intrinsic hand muscles of the right side were normal, while those of the left side were absent. There was no sensory deficit. Nerve transfers for SCBS were advised. The parents gave informed consent for the operations.

Two weeks later, the patient underwent double fascicular transfer to restore right elbow flexion and SCBS by spinal accessory to musculocutaneous nerve transfer with sural nerve interposition graft to restore left elbow flexion. Details of the operations are described as follows:

1) Double fascicular transfer is a combination of transferring ulnar nerve fascicle innervating flexor carpi ulnaris (FCU) to biceps nerve, and transferring median nerve fascicle supplying flexor carpi radialis (FCR) to brachialis nerve. The patient was operated in supine position under general anesthesia. Muscle relaxant was not used because intraoperative electrical

nerve stimulation was required. A longitudinal medial arm incision was made to expose the donor (ulnar and median) and recipient (musculocutaneous) nerves (Fig. 1A). Donor fascicles were selected using intraoperative electrical nerve stimulation. Stimulation of ulnar fascicle supplying the FCU elicited vigorous wrist flexion and ulnar deviation of the wrist without contraction of the intrinsic hand muscles. In the same way, stimulation of median fascicle supplying the FCR showed flexion of the wrist without finger flexors. Both fascicles were adopted to be donor nerves. On the exposure of the musculocutaneous nerve, the nerve branched into three branches, including the nerve to biceps brachii, nerve to brachialis and lateral cutaneous nerve of the forearm (LCNF). Two motor branches (the nerves to biceps brachii and brachialis) were prepared to be recipient nerves. The FCU fascicle was transferred to the nerve to biceps brachii and the FCR fascicle was transferred to the nerve to brachialis (Fig. 1B). Because sensation of our patient was intact, the LCNF was preserved to avoid sensory deficit.

2) Spinal accessory to musculocutaneous nerve transfer with sural nerve interposition graft was done for SCBS. The posterior triangle of neck was exposed for preparing the donor (spinal accessory) nerve supplying the trapezius (nerve to trapezius) (Fig. 2A). It always has two branches; one is selected to be the donor nerve. Electrical stimulation of this nerve evoked strong shoulder elevation. The recipient (musculocutaneous) nerve in the arm was prepared as

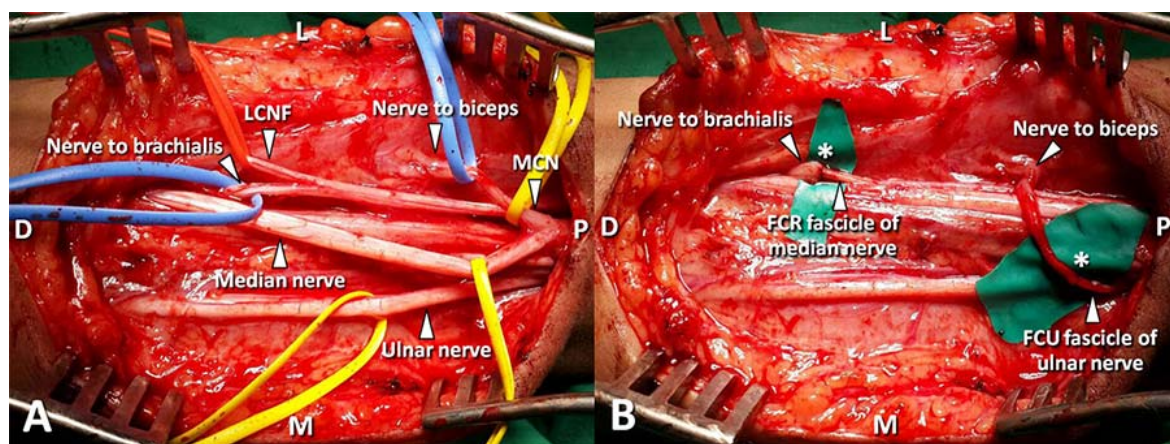


Fig. 1 Double fascicular transfer for right elbow flexion: A) operative exposure of the regional nerves in the right arm prepared for nerve transfer; B) transfer of the FCU fascicle of the ulnar nerve to the nerve supplying biceps brachii and transfer of the FCR fascicle of the median nerve to the nerve supplying the brachialis; the asterisk (*) indicates the location of anastomosis; D = distal; FCR = flexor carpi radialis; FCU = flexor carpi ulnaris; L = lateral; LCNF = lateral cutaneous nerve of the forearm; M = medial; MCN = musculocutaneous nerve; P = proximal.

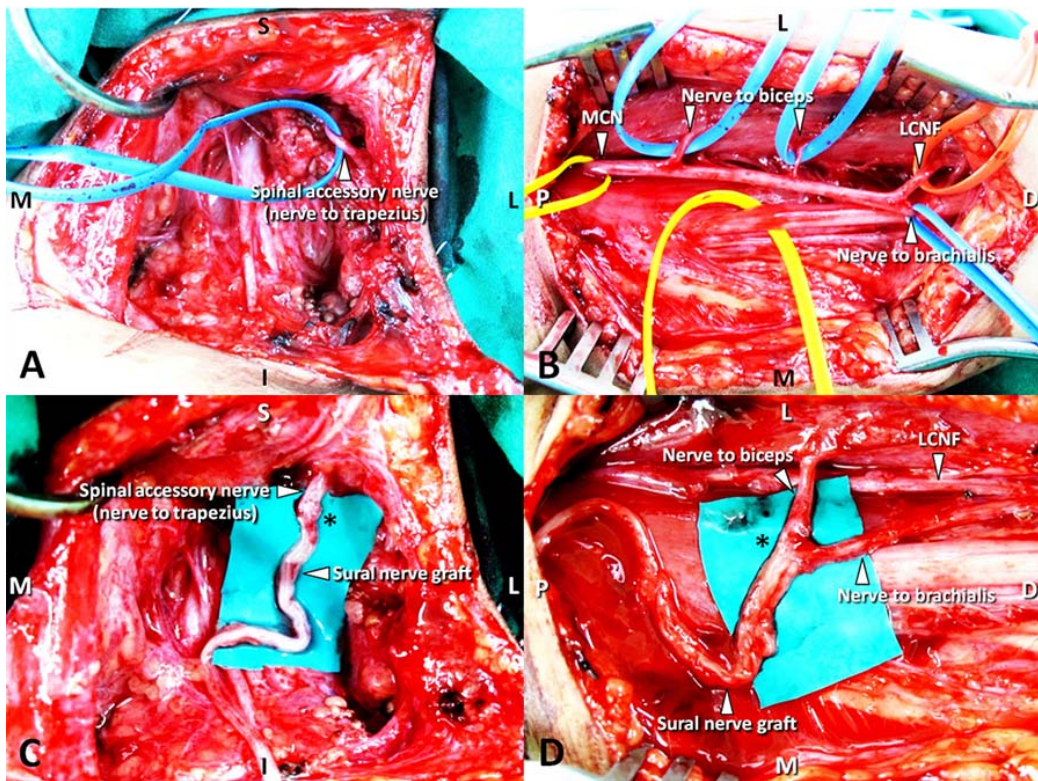


Fig. 2 Spinal accessory to musculocutaneous nerve transfer with sural nerve interposition graft on the left side: A) operative exposure of the motor branch of the spinal accessory nerve (nerve to trapezius); B) operative exposure of the left musculocutaneous nerve and its branches; C and D) the spinal accessory nerve was transferred to the nerves supplying biceps brachii and brachialis with a sural nerve graft; the asterisk (*) indicates the location of anastomosis; D = distal; I = inferior; L = lateral; LCNF = lateral cutaneous nerve of the forearm; M = medial; MCN = musculocutaneous nerve; P = proximal; S = superior.

the previous description (Fig. 2B). The sural nerve graft was harvested in an appropriate length. The graft was placed under the skin and clavicle. One end of the nerve graft was anastomosed to the nerve to trapezius (Fig. 2C) and the other was anastomosed to the nerves to biceps brachii and brachialis (Fig. 2D). The LCNF was preserved for the same reason. Postoperative rehabilitation was initiated after the operations.

One month later, the patient underwent bilateral spinal accessory to suprascapular nerve transfers by posterior approach; however, electrical stimulation of the spinal accessory nerve showed no motor response on both sides. On the right brachial plexus exposure in attempt to perform nerve transfer for restoration of shoulder function, electrical stimulation of the spinal accessory, phrenic nerves and motor branches of the cervical plexus also revealed no motor response. Therefore, SCBS for restoration of shoulder stabilization was not successful.

About five months following nerve transfers to restore elbow flexion, the patient could voluntarily perform right elbow flexion by himself. Physical examination showed obvious contraction of the right elbow flexor muscles. Motor power of the elbow flexors was Medical Research Council (MRC) Grade 3 (Fig. 3). There was no postoperative sensory impairment. At six months postoperatively there was still no contraction of the left elbow flexors.

Discussion

SCI negatively impacts patients on quality of life, physical, psychological and social perspectives. Spontaneous neurological recovery with time following SCI occurs in some cases; however, a large number of patients still suffer from permanent disabling neurological deficit. Restoration of neurological function can improve more or less their quality of life.

Nerve transfer is widely performed in

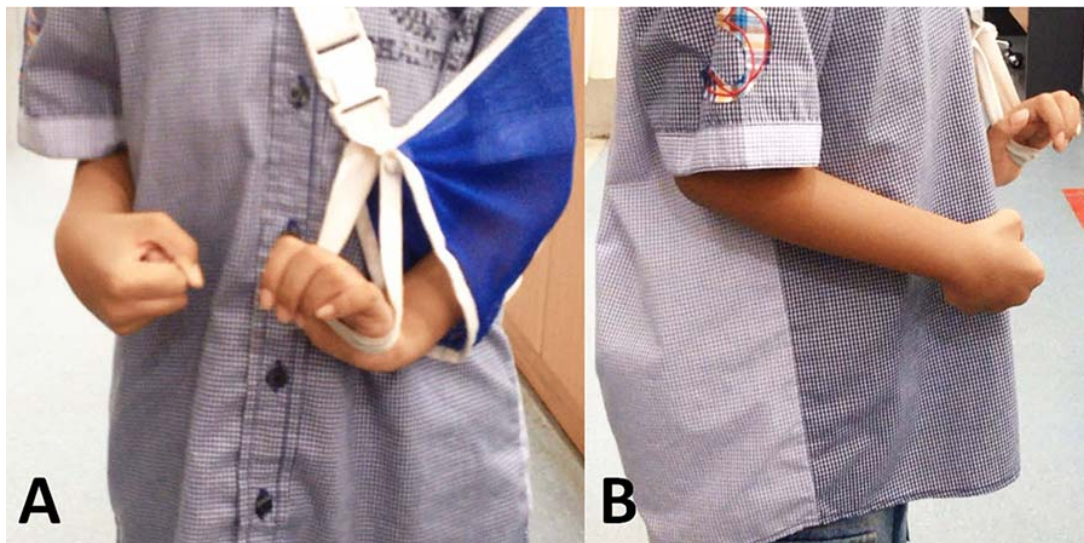


Fig. 3 Right elbow flexion (MRC Grade 3) at five months following the operations in anteroposterior (A) and lateral (B) views.

functional restoration of the limbs following brachial plexus injury. This can be also used for SCBS to restore limb and organ functions⁽⁶⁾. SCBS by nerve transfer was firstly reported in 1907; Kilvington and Osborne performed lumbar to ventral sacral nerve root anastomosis in 3 dogs. One of them regained bladder function, bladder contraction and micturition occurred when the transferred nerve roots were being stimulated⁽⁷⁾. Subsequently, animal, cadaveric and human studies have been continuously reported. In the literature review, case reports and series of SCBS using nerve transfer in human are summarized in Table 1⁽⁸⁻²¹⁾.

Our patient had cervical cord injury with neurological deficit compatible with central cord syndrome. He had asymmetrical motor deficit of both upper extremities, whereas motor function of the lower limbs was intact. The goal of nerve transfer in this patient was restoration of elbow flexion and shoulder abduction of both sides. The patient had residual motor function of the right wrist and fingers. The authors therefore used double fascicular transfer to restore right elbow flexion⁽²²⁾. The nerve fascicles supplying the wrist flexors (FCU and FCR fascicles) were neurotized to the nerves to the elbow flexors (biceps brachii and brachialis, respectively). The fascicles innervating hand muscles were preserved to avoid additional deterioration of hand motor function. There was no motor function of the left upper limb; we chose the trapezius motor branch as a donor nerve to restore left

elbow flexion. Because there was a large gap between the trapezius motor branch and musculocutaneous nerve, a lengthy sural nerve interposition graft was required for this neurotization. Although phrenic nerve transfer is an excellent option for restoration of elbow flexion as well as shoulder abduction⁽²³⁾, in our opinion, it should be avoided in pediatric patients. Regaining function of the right elbow flexor at five months following double fascicular transfer indicates that nerve transfer is a valuable method for restoration of motor function in SCI patients.

Conclusion

To the best of our knowledge, this article is the first case report of SCBS using nerve transfer for SCI in Thailand. SCBS is a new hope in SCI patients with neurological disability. Various nerve transfer techniques can be used to restore motor, sensory and organ functions.

What is already known from this topic?

Significant neurological deficits occur as a result of SCI. Nerve transfer is a common surgical therapy of brachial plexus injury. It can be used as SCBS for restoration of organ function after SCI.

What this study adds?

The authors confirmed efficacy of peripheral nerve transfers for restoration of the upper limb function. Elbow flexion is restored following double

Table 1. Literature review of SCBS using nerve transfer for patients with SCI

Authors (year)	No. of patients	Procedure	Result	Follow-up
Freeman (1961) ⁽⁸⁾	1	Intercostal to spinal nerve transfer and intercostal nerve-conus medullaris implant	Subjective improvement of bladder and lower extremity function	n/a
Carlsson & Sundin (1980) ⁽⁹⁾	2	Intercostal to sacral nerve transfer	Restoration of micturation reflex in the cystometrogram, both cases had improvement of micturation function	12 months
Dai et al. (1985) ⁽¹⁰⁾	21	10 intercostal nerve-cauda equina anatomoses and 11 intercostal to lumbar nerve transfers	11 cases had EMG improvement of previously paralyzed muscles, 3 had motor strength recovery of previously paralyzed muscles to grades 1-3	6-48 months
Mackinnon et al (1985) ^(11,12)	1	Medial antebrachial cutaneous to lateral femoral cutaneous nerve transfer with sural nerve interposition graft	The patient could perceive light touch, pressure and vibration, skin biopsy showed regeneration of nerve fibers near a hair follicle	4 years
Krieger et al (1994) ⁽¹³⁾	1	Intercostal to phrenic nerve transfer with electrical stimulation for diaphragmatic pacing	The patient could use diaphragmatic pacing 24 hours per day	130 days
Krieger et al (2000) ⁽¹⁴⁾	10	Intercostal to phrenic nerve transfer with electrical stimulation for diaphragmatic pacing	8 of 10 patients could tolerate diaphragmatic pacing as an option to positive pressure ventilation	6-13 months
Tadie et al (2002) ⁽¹⁵⁾	1	Spinal cord at T7-8 levels to ipsilateral L2-4 lumbar ventral roots with sural nerve interposition grafts	Voluntary contractions of bilateral adductors and left quadriceps, Muscle activity by motor unit action potentials was found in response to attempted muscle contraction	8 months
Zhang et al (2003) ⁽¹⁶⁾	23	Intercostal to lumbar nerve transfer with or without sural nerve interposition graft	18 patients regained the stepping-forward function and were able to walk with crutches or other devices, 21 patients had improvement of thigh sensation	2-11 years
Livshits et al (2004) ⁽¹⁷⁾	11	Intercostal to sacral nerve transfer	Significant improvement of bladder and sphincter function, restoration of micturation reflex	12 months
Oppenheim et al (2009) ⁽¹⁸⁾	1	Subdural implantation of intercostal nerves to spinal cord below level of cord injury	Recovery of hip adduction (MRC Grade 2) and flexion (MRC Grade 2), spontaneous movement of legs in cycle with respirations	10 months

AIN = anterior interosseous nerve; ECR = extensor carpi radialis; ECU = extensor carpi ulnaris; FCR = flexor carpiradialis; FDS = flexor digitorum superficialis; MRC = Medical Research Council; N/A = not available; PIN = posterior interosseous nerve

Table 1. Cont.

Authors (year)	No. of patients	Procedure	Result	Follow-up
Mackinnon et al (2012) ⁽¹⁹⁾	1	Bilateral brachialis to AIN transfers	Restoration of flexor pollicis longus and flexor digitorum profundus strength (MRC Grade 3)	15 months
Fox et al (2015) ⁽²⁰⁾	7	Brachialis to AIN, brachialis to FCR, brachialis to AIN/FCR, brachialis to FCR/FDS, supinator to PIN, supinator to ECU, deltoid to triceps nerve transfers	No donor morbidity	2-4 weeks
Fox et al (2015) ⁽²¹⁾	9	Brachialis to AIN, brachialis to FCR, brachialis to AIN/FCR, brachialis to FCR/FDS, brachialis to ECR, supinator to PIN, supinator to ECU, deltoid to triceps nerve transfers	6 patients had subjective improvement of hand and upper limb function	1-36 months
The current case	1	Right double fascicular transfers (FCU to biceps, FCR to brachialis) for elbow flexion, left spinal accessory to musculocutaneous nerve transfer with sural nerve interposition graft, failed spinal accessory to suprascapular nerve transfers (bilateral posterior and right anterior approaches) due to lack of donor nerve	The patient could perform right elbow flexion (MRC Grade 3) at 5 month postoperatively	6 months

AIN = anterior interosseous nerve; ECR = extensor carpi radialis; ECU = extensor carpi ulnaris; FCR = flexor carpiradialis; FDS = flexor digitorum superficialis; MRC = Medical Research Council; N/A = not available; PIN = posterior interosseous nerve

fascicular transfer for elbow flexion.

Potential conflicts of interest

None.

References

1. Young WF. Cervical spondylotic myelopathy: a common cause of spinal cord dysfunction in older persons. *Am Fam Physician* 2000; 62: 1064-70, 1073.
2. Ho EL. Infectious etiologies of myelopathy. *Semin Neurol* 2012; 32: 154-60.
3. Rigney L, Cappelen-Smith C, Sebire D, Beran RG, Cordato D. Nontraumatic spinal cord ischaemic syndrome. *J Clin Neurosci* 2015; 22: 1544-9.
4. Hammell KW. Exploring quality of life following high spinal cord injury: a review and critique. *Spinal Cord* 2004; 42: 491-502.
5. Haque RM, Malone HR, Bauknight MW, Kellner MA, Ogden AT, Martin JH, et al. Spinal cord bypass surgery with intercostal and spinal accessory nerves: an anatomical feasibility study in human cadavers. *J Neurosurg Spine* 2012; 16: 178-86.
6. Senjaya F, Midha R. Nerve transfer strategies for spinal cord injury. *World Neurosurg* 2013; 80: e319-26.
7. Kilvington B, Osborne WA. The regeneration of post-ganglionic vaso-constrictor nerves: Part II. *J Physiol* 1907; 35: 460-4.
8. Freeman LW. Neuronal regeneration in the central nervous system of man. Successful growth of intercostal-spinal nerve anastomosis and growth

- of intercostal nerve-spinal cord implant. *J Neurosurg* 1961; 18: 417-22.
9. Carlsson CA, Sundin T. Reconstruction of afferent and efferent nervous pathways to the urinary bladder in two paraplegic patients. *Spine (Phila Pa 1976)* 1980; 5: 37-41.
 10. Dai KR, Yu CT, Wu RS, Zhang XF, Yuan JX, Sun YH. Intercostal-lumbar-spinal nerve anastomoses for cord transection. A preliminary investigation. *J Reconstr Microsurg* 1985; 1: 223-6.
 11. Mackinnon SE, Dellon AL, Patterson GA, Gruss JS. Medial antebrachial cutaneous-lateral femoral cutaneous neurotization to provide sensation to pressure-bearing areas in the paraplegic patient. *Ann Plast Surg* 1985; 14: 541-4.
 12. Louie G, Mackinnon SE, Dellon AL, Patterson GA, Hunter DA. Medial antebrachial cutaneous—lateral femoral cutaneous neurotization in restoration of sensation to pressure-bearing areas in a paraplegic: a four-year follow-up. *Ann Plast Surg* 1987; 19: 572-6.
 13. Krieger AJ, Gropper MR, Adler RJ. Electrophrenic respiration after intercostal to phrenic nerve anastomosis in a patient with anterior spinal artery syndrome: technical case report. *Neurosurgery* 1994; 35: 760-3.
 14. Krieger LM, Krieger AJ. The intercostal to phrenic nerve transfer: an effective means of reanimating the diaphragm in patients with high cervical spine injury. *Plast Reconstr Surg* 2000; 105: 1255-61.
 15. Tadie M, Liu S, Robert R, Guiheneuc P, Pereon Y, Perrouin-Verbe B, et al. Partial return of motor function in paralyzed legs after surgical bypass of the lesion site by nerve autografts three years after spinal cord injury. *J Neurotrauma* 2002; 19: 909-16.
 16. Zhang S, Johnston L, Zhang Z, Ma Y, Hu Y, Wang J, et al. Restoration of stepping-forward and ambulatory function in patients with paraplegia: rerouting of vascularized intercostal nerves to lumbar nerve roots using selected interfascicular anastomosis. *Surg Technol Int* 2003; 11: 244-8.
 17. Livshits A, Catz A, Folman Y, Witz M, Livshits V, Baskov A, et al. Reinnervation of the neurogenic bladder in the late period of the spinal cord trauma. *Spinal Cord* 2004; 42: 211-7.
 18. Oppenheim JS, Spitzer DE, Winfree CJ. Spinal cord bypass surgery using peripheral nerve transfers: review of translational studies and a case report on its use following complete spinal cord injury in a human. Experimental article. *Neurosurg Focus* 2009; 26: E6.
 19. Mackinnon SE, Yee A, Ray WZ. Nerve transfers for the restoration of hand function after spinal cord injury. *J Neurosurg* 2012; 117: 176-85.
 20. Fox IK, Davidge KM, Novak CB, Hoben G, Kahn LC, Juknis N, et al. Use of peripheral nerve transfers in tetraplegia: evaluation of feasibility and morbidity. *Hand (NY)* 2015; 10: 60-7.
 21. Fox IK, Davidge KM, Novak CB, Hoben G, Kahn LC, Juknis N, et al. Nerve transfers to restore upper extremity function in cervical spinal cord injury: update and preliminary outcomes. *Plast Reconstr Surg* 2015; 136: 780-92.
 22. Mackinnon SE, Novak CB, Myckatyn TM, Tung TH. Results of reinnervation of the biceps and brachialis muscles with a double fascicular transfer for elbow flexion. *J Hand Surg Am* 2005; 30: 978-85.
 23. Bertelli JA, Ghizoni MF. Results of spinal accessory to suprascapular nerve transfer in 110 patients with complete palsy of the brachial plexus. *J Neurosurg Spine* 2016; 24: 990-5.

การผ่าตัดข้ามไขสันหลังระดับที่บาดเจ็บโดยใช้การย้ายเส้นประสาทเพื่อฟื้นฟูการงอข้อศอกในผู้ป่วยเด็กหนึ่งรายซึ่งมี
การบาดเจ็บส่วนกลางของไขสันหลังระดับคอ

บรรพต สิทธินามสุวรรณ, อัครพงษ์ นิตติสิงห์, ศรีณย์ นันทอาวี

ภูมิหลัง: การผ่าตัดข้ามไขสันหลังระดับที่บาดเจ็บเป็นการผ่าตัดเพื่อฟื้นฟูการทำงานของอวัยวะหลังไขสันหลังบาดเจ็บ การย้ายเส้นประสาทเป็นการผ่าตัดที่ทำบ่อยในผู้ป่วยที่มีขั้วประสาทแขนบาดเจ็บ นอกจากนี้ยังสามารถใช้การย้ายเส้นประสาทในการผ่าตัดข้ามไขสันหลังระดับที่บาดเจ็บในผู้ป่วยไขสันหลังบาดเจ็บได้

วัตถุประสงค์: เพื่อรายงานวิธีการผ่าตัดและผลการรักษาโดยการผ่าตัดย้ายเส้นประสาทในผู้ป่วยหนึ่งรายซึ่งมีการบาดเจ็บของไขสันหลังระดับคอ

วัสดุและวิธีการ: คณะผู้ประพันธ์รายงานผู้ป่วยอายุ 6 ปี ซึ่งมีการบาดเจ็บของส่วนกลางของไขสันหลังระดับคอและผู้ป่วยไม่มีการฟื้นตัวของระบบประสาทตรวจร่างกายพบว่ามีคามผิดปกติของระบบประสาทสั่งการของแขนทั้งสองข้างไม่เท่ากัน

ผลการศึกษา: ผู้ป่วยได้รับการผ่าตัดย้ายเส้นประสาทสองเส้นที่แขนขวาเพื่อฟื้นฟูการงอข้อศอกขวาและได้รับการผ่าตัดย้ายเส้นประสาทสมองคู่ที่ 11 ไปยังเส้นประสาท musculocutaneous โดยใช้เส้นประสาท sural เชื่อมต่อเพื่อฟื้นฟูการงอข้อศอกซ้าย ผู้ป่วยสามารถงอข้อศอกขวาโดยมีแรงของกล้ามเนื้อระดับ 3 ที่เวลา 5 เดือนหลังผ่าตัด

สรุป: จากการค้นคว้าของคณะผู้ประพันธ์พบว่าผู้ป่วยรายนี้เป็นรายงานผู้ป่วยรายแรกในประเทศไทยที่ได้รับการผ่าตัดข้ามไขสันหลังระดับที่บาดเจ็บโดยใช้การย้ายเส้นประสาทในผู้ป่วยไขสันหลังบาดเจ็บ
