

# Case Report

## A Case of Successful Transanal Excision in Lower Rectal Gastrointestinal Stromal Tumor (GIST)

Woramin Riansuwan MD, FRCST\*,  
Siriluck Prapasrivorakul MD, FRCST\*

\* Colorectal Surgery Unit, Division of General Surgery, Department of Surgery,  
Faculty of Medicine Siriraj Hospital, Mahidol University, Bangkok, Thailand

**Background:** Surgery is the principle treatment of resectable non-metastatic rectal GIST. There is a question whether standard oncologic resection or local excision is appropriate in surgery for rectal GIST. The present report is a case of successful transanal excision in a lower rectal GIST patient.

**Case Report:** A 54-year-old woman presented with passing bright red blood per her rectum for one month. Her physical examination, colonoscopy with biopsy and CT scan demonstrated a three-centimeter lower rectal GIST with no liver metastasis. The patient underwent an uneventful transanal excision. The operative time was 95 minutes and blood loss was 20 milliliters. The pathology report showed a three centimeter spindle cell type GIST; mitotic count >10/50 high power field with absence of angiolymphatic invasion. The patient received postoperative adjuvant Imatinib Mesylate. No recurrent tumor was detected by either physical examination or CT scan after one year of follow-up and she had neither incontinence nor constipation.

**Conclusion:** Short-term results both in oncologic clearance and functional outcomes of transanal excision in a small lower rectal GIST (under 3 cm) were acceptable. However, long-term follow-up is still needed.

**Keywords:** Rectal GIST, Gastrointestinal stromal tumor, GIST, Transanal excision, Local excision

**J Med Assoc Thai 2017; 100 (Suppl. 3): S209-S212**

**Full text. e-Journal:** <http://www.jmatonline.com>

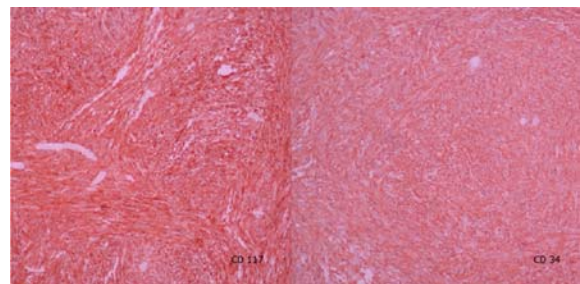
Surgery is the principle treatment for resectable, non-metastatic rectal GIST. The standard oncologic resection might be inappropriate especially in lower rectal GIST because skip metastases and lymphatic spread are rarely reported meanwhile some patients could not avoid having a permanent colostomy. There is a question whether a local excision such as transanal excision in the lower rectal GIST is comparable to an oncologic resection or not. The authors, therefore, report a case of successful transanal excision in lower rectal GIST.

### Case Report

A 54-year-old woman presented with passing bright red blood per her rectum for one month. She had no underlying diseases. Physical examination and colonoscopy demonstrated a 3-cm polypoid mass at the left lateral wall of the lower rectum; 5 cm above anal

verge. The biopsy reported spindle cell neoplasm and immuno-histochemical study revealed the tumor cells marked with CD117 and CD34 (Fig. 1). An abdominal CT scan showed an enhancing 3.5x3.5x3.6 cm<sup>3</sup> lobulated contour soft tissue mass at the left lateral aspect of the lower rectum which abutted to the left of levator ani muscle (Fig. 2). No liver metastasis was demonstrated.

After informing the patient of risks, benefits, alternatives and complications, the patient consented for surgery but refused to have a colostomy. She then underwent transanal excision (Fig. 3). Under spinal anesthesia, the patient was placed in prone jackknife position after an indwelling Foley catheter was inserted



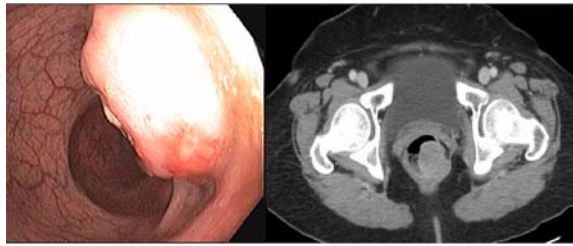
**Fig. 1** CD 117 and CD 34 immunohistochemistry stain.

### Correspondence to:

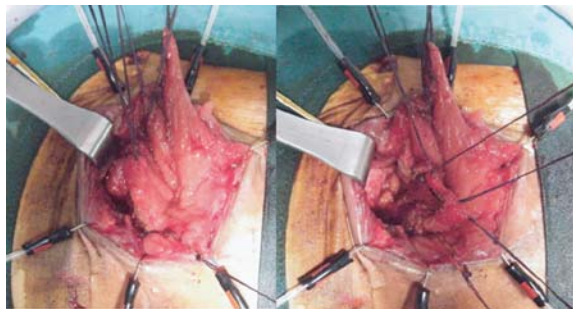
Riansuwan W, Colorectal Surgery Unit, Division of General Surgery, Department of Surgery, Faculty of Medicine Siriraj Hospital, 2 Prannok Road, Bangkok Noi, Bangkok 10700, Thailand.

Phone: +66-2-4198005, Fax: +66-2-4121370

E-mail: woramin@gmail.com



**Fig. 2** Colonoscopic appearance and CT scan showed submucosal mass in lower rectum.



**Fig. 3** Transanal excision.

and prophylactic antibiotics were given. Rectal irrigation with Povidone Iodine solution and Lone-Star retractors were applied to expose the anorectal region. The rectal wall including the tumor and surrounding perirectal fat were excised with electrocautery. To avoid rectal lumen stricture, the defect of the rectal wall was closed with interrupted 2-0 Polyglactin sutures in transverse fashion. The operative time was 95 minutes and blood loss was 20 milliliters. The patient recovered uneventfully after surgery.

The pathology report showed a 3-cm spindle cell type GIST; mitotic count >10/50 high power field; absence of angiolymphatic invasion; free all resected margins. Afterward, the patient received postoperative daily adjuvant Imatinib Mesylate 400 mg daily. No recurrent tumor was detected by either physical examination or CT scan after one year of follow-up and she had neither incontinence nor constipation.

### Discussion

In non-metastatic resectable colorectal GIST, surgery is the standard treatment and it can be achieved in 95 percent of the cases<sup>(1,2)</sup>. The principle of surgery in colorectal GIST is wide resection of tumor with negative margins. Usually, segmental colon or rectal resection is enough because lymphatic and skip metastasis is very rare. Therefore, lymphadenectomy

or total mesorectal excision is unnecessary in rectal GIST.

The author reports here a case of successful transanal excision in the lower rectal GIST with acceptable short-term outcomes and the patient avoided a permanent colostomy in the abdomino-perineal resection. Transanal local excision has been primarily reported as an acceptable treatment in small rectal GIST less than 3 cm if R0 resected margins can be achieved and the anal sphincter is not involved. Other local excision techniques such as trans-sacral approach or transvaginal approach have been reported in selected patients if a transanal excision was difficult to perform<sup>(3-5)</sup>.

Local recurrence is one of the concerns in surgery for rectal GIST. It has been reported in 77 percent and 31 percent of cases after local excision and radical resection, respectively<sup>(6)</sup>. Incomplete tumor removal which leads to recurrence has been reported in up to 38 percent of patients despite extensive procedures that were carried out<sup>(7)</sup>. Moreover, the resection rate of salvage surgery after local recurrence dropped to 40 to 55 percent<sup>(8,9)</sup>.

With the introduction of tyrosine kinase inhibitors, unresectable lesions could be down staged with subsequent R0 resection in over 80 percent of patients by pre-operative neoadjuvant therapy<sup>(10,11)</sup>. Preliminary data suggest that neoadjuvant Imatinib therapy does not increase postoperative complications, but the risk of bleeding or tumor perforation requiring emergency surgery does not seem negligible<sup>(12,13)</sup>. Furthermore, local excision is a less extensive surgery with better anticipated postoperative functional outcomes<sup>(14,15)</sup>.

### Conclusion

Short-term results both in oncologic clearance and functional outcomes of a transanal excision in a small lower rectal GIST (under 3 cm) is acceptable. However, long-term follow-up is still needed. Currently, indications, optimal dose, appropriate duration as well as timing for surgery in neoadjuvant therapy are not established.

### What is already known on this topic?

Surgery is principle treatment in a non-metastasis rectal GIST.

### What this study adds?

Resection with a negative margin such as transanal excision is adequate management for non-

metastasis lower rectal GIST patients.

### Acknowledgements

The authors would like to acknowledge Assist. Prof. Dr. Ananya Pongpaiboon, Department of Pathology, Faculty of Medicine Siriraj Hospital for her assistance in preparing Fig. 1: CD 117 and CD 34 immunohistochemistry stain.

### Potential conflicts of interest

None.

### References

1. Tran T, Davila JA, El Serag HB. The epidemiology of malignant gastrointestinal stromal tumors: an analysis of 1,458 cases from 1992 to 2000. *Am J Gastroenterol* 2005; 100: 162-8.
2. Nilsson B, Bumming P, Meis-Kindblom JM, Oden A, Dortok A, Gustavsson B, et al. Gastrointestinal stromal tumors: the incidence, prevalence, clinical course, and prognostication in the preimatinib mesylate era—a population-based study in western Sweden. *Cancer* 2005; 103: 821-9.
3. Gervaz P, Huber O, Bucher P, Sappino P, Morel P. Trans-sacral (Kraske) approach for gastrointestinal stromal tumour of the lower rectum: old procedure for a new disease. *Colorectal Dis* 2008; 10: 951-2.
4. Matsushima K, Kayo M. Transsacral approach to resect a gastrointestinal stromal tumor in the rectum: report of two cases. *Surg Today* 2007; 37: 698-701.
5. Hellan M, Maker VK. Transvaginal excision of a large rectal stromal tumor: an alternative. *Am J Surg* 2006; 191: 121-3.
6. Changchien CR, Wu MC, Tasi WS, Tang R, Chiang JM, Chen JS, et al. Evaluation of prognosis for malignant rectal gastrointestinal stromal tumor by clinical parameters and immunohistochemical staining. *Dis Colon Rectum* 2004; 47: 1922-9.
7. Baik SH, Kim NK, Lee CH, Lee KY, Sohn SK, Cho CH, et al. Gastrointestinal stromal tumor of the rectum: an analysis of seven cases. *Surg Today* 2007; 37: 455-9.
8. Pierie JP, Choudry U, Muzikansky A, Yeap BY, Souba WW, Ott MJ. The effect of surgery and grade on outcome of gastrointestinal stromal tumors. *Arch Surg* 2001; 136: 383-9.
9. Roberts PJ, Eisenberg B. Clinical presentation of gastrointestinal stromal tumors and treatment of operable disease. *Eur J Cancer* 2002; 38 (Suppl 5): S37-8.
10. Haller F, Detken S, Schulten HJ, Happel N, Gunawan B, Kuhlitz J, et al. Surgical management after neoadjuvant imatinib therapy in gastrointestinal stromal tumours (GISTs) with respect to imatinib resistance caused by secondary KIT mutations. *Ann Surg Oncol* 2007; 14: 526-32.
11. Andtbacka RH, Ng CS, Scaife CL, Cormier JN, Hunt KK, Pisters PW, et al. Surgical resection of gastrointestinal stromal tumors after treatment with imatinib. *Ann Surg Oncol* 2007; 14: 14-24.
12. Eisenberg BL, Harris J, Blanke CD, Demetri GD, Heinrich MC, Watson JC, et al. Phase II trial of neoadjuvant/adjuvant imatinib mesylate (IM) for advanced primary and metastatic/recurrent operable gastrointestinal stromal tumor (GIST): early results of RTOG 0132/ACRIN 6665. *J Surg Oncol* 2009; 99: 42-7.
13. Raut CP, Posner M, Desai J, Morgan JA, George S, Zahrieh D, et al. Surgical management of advanced gastrointestinal stromal tumors after treatment with targeted systemic therapy using kinase inhibitors. *J Clin Oncol* 2006; 24: 2325-31.
14. Lo SS, Papachristou GI, Finkelstein SD, Conroy WP, Schraut WH, Ramanathan RK. Neoadjuvant imatinib in gastrointestinal stromal tumor of the rectum: report of a case. *Dis Colon Rectum* 2005; 48: 1316-9.
15. Wasserberg N, Nunoo-Mensah JW, Beart RW Jr, Ker TS. Is there a role for neoadjuvant treatment with Gleevec for large rectal gastrointestinal stromal tumors? *Int J Colorectal Dis* 2007; 22: 981-2.

---

## ความสำเร็จของการผ่าตัดผ่านทางทวารหนักในผู้ป่วย *Gastrointestinal Stromal Tumor (GIST)* ที่ตำแหน่งลำไส้ตรงส่วนปลาย ในผู้ป่วยหนึ่งราย

วรมินทร์ เจริญสุวรรณ, ศิริลักษณ์ ประชาศรีวรกุล

**ภูมิหลัง:** การผ่าตัดเป็นการรักษาหลักในผู้ป่วย *GIST* ของลำไส้ตรงที่ยังไม่มีการกระจายไปยังอวัยวะอื่น แต่ยังมีคำถามว่าระหว่างการผ่าตัดเพียงเอาก่อนเนื้องอกออกหรือตัดลำไส้ตรงและเกาะต่อมน้ำเหลืองออกด้วยตามหลักมะเร็งวิทยา นั้น วิธีใดจะเหมาะสมกับผู้ป่วยกลุ่มนี้ ผู้เขียนได้รายงานความสำเร็จของการผ่าตัดผ่านทางทวารหนักในผู้ป่วย *Gastrointestinal Stromal Tumor (GIST)* ที่ตำแหน่งลำไส้ตรงส่วนปลายในผู้ป่วยหนึ่งราย

**รายงานผู้ป่วย:** ผู้ป่วยหญิงอายุ 54 ปีมีอาการถ่ายอุจจาระเป็นเลือดสดมานาน 1 เดือน การตรวจร่างกาย ตรวจส่องกล้องลำไส้ใหญ่และตัดชิ้นเนื้อตรวจทางพยาธิวิทยาตลอดจนตรวจเอกซเรย์คอมพิวเตอร์ช่องท้องพบก้อนเนื้ออกชนิด *GIST* ขนาด 3 เซนติเมตร ที่ตำแหน่งลำไส้ตรงส่วนปลายและยังไม่มี การกระจายไปยังอวัยวะอื่น ผู้ป่วยได้รับการผ่าตัดผ่านทางทวารหนักสำเร็จลงไปด้วยดีโดยใช้เวลาผ่าตัด 95 นาทีและเสียเลือดในระหว่างผ่าตัด 20 มิลลิลิตร ผลตรวจทางพยาธิวิทยายืนยันว่าเป็นเนื้องอก *GIST* ชนิด spindle cell ผู้ป่วยได้รับการรักษาเสริม หลังการผ่าตัดด้วยยา *Imatinib Mesylate* เมื่อติดตามผู้ป่วยด้วยการตรวจร่างกายและเอกซเรย์คอมพิวเตอร์ต่อมาอีก 1 ปี ไม่พบการกลับเป็นซ้ำของโรคตลอดจนผู้ป่วยไม่มีปัญหาการกลืนอุจจาระไม่ได้หรือท้องผูกหลังผ่าตัด

**สรุป:** ผลการรักษาในระยะสั้นของการผ่าตัดผ่านทางทวารหนักในผู้ป่วย *GIST* ที่ก่อนมีขนาดเล็กกว่า 3 เซนติเมตร ที่ตำแหน่งลำไส้ตรงส่วนปลาย เป็นที่ยอมรับได้ อย่างไรก็ตามการติดตามผลการรักษาในระยะยาวยังมีความจำเป็น

---