

Case Report

Successful Treatment of Tracheo-innominate Artery Fistula with Endovascular Stent Graft: A Case Report with Literature Review

Yuttasint Vongsangcom MD*,
Wanchai Wongkornrat MD*, Worawong Slisatkorn MD*

* Division of Cardio-Thoracic Surgery, Department of Surgery, Faculty of Medicine Siriraj Hospital, Mahidol University, Bangkok, Thailand

Tracheo-innominate artery fistula (TIF) is an uncommon complication but with high mortality following tracheostomy. Definitive treatment of TIF requires median sternotomy and ligation of the innominate artery. However, most of the patients have considerable comorbidity and unstable hemodynamic status which may not suitable for open repair. The authors report a successful management of TIF in a high surgical risk patient with endovascular stent grafting.

Keywords: Tracheo-innominate artery fistula, Endovascular repair, Stent graft

J Med Assoc Thai 2017; 100 (Suppl. 3): S199-S203

Full text. e-Journal: <http://www.jmatonline.com>

Tracheo-innominate artery fistula (TIF) is an uncommon complication but with high risk of mortality⁽¹⁾ following both open and percutaneous tracheostomy⁽²⁻⁵⁾. Definitive treatment of TIF requires median sternotomy and ligation of the innominate artery. However, in this group of patients, most of them have considerable comorbidity and unstable hemodynamic status which may not suitable for open repair. There are many case reports in successful treatment of TIF with endovascular graft⁽⁶⁻¹⁰⁾. The authors reported a successful management of TIF in deliberated patient with endovascular graft.

Case Report

A 74 year-old Thai female with history of old cerebrovascular disease, Parkinson's disease, Pemphigus foliaceus and on tracheostomy tube for 6 years. She was sent to our hospital with massive bleeding (estimate 2 liters) from tracheostomy 1 day ago with spontaneous cessation of bleeding. At the emergency room she was resuscitated and after her vital signs were stable, flexible laryngoscopy was performed. Erythema of tracheal wall without point of active bleeding was found. Tracheostomy cuff was

inflated and the patient was admitted in ICU to investigate and observed bleeding. During admission she had history of brisk bleeding from tracheostomy tube. Emergency CTA chest demonstrated focal delayed contrast accumulation at the right anterolateral aspect of the tracheostomy adjacent to the inflated cuff suspicious of TIF (Fig. 1).

The patient was transferred to the OR for laryngoscopy to find out the point of bleeding.

Intra-operative flexible laryngoscopy found friable tissue at the right anterior aspect of trachea at the tracheostomy cuff level corresponded to an area of

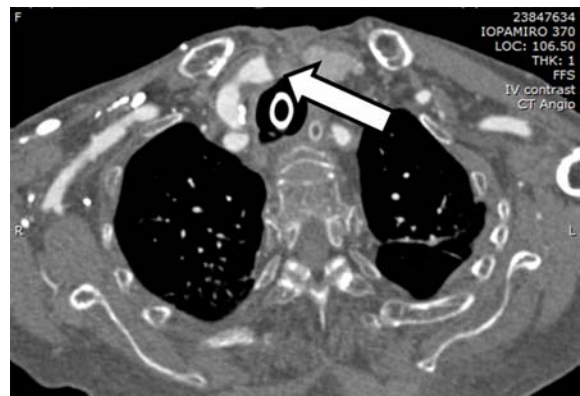

Fig. 1 Emergency CTA chest demonstrated focal delay contrast accumulation at the right anterolateral aspect of the tracheostomy adjacent to the inflated cuff (arrow).

Correspondence to:

Slisatkorn W, Division of Cardio-Thoracic Surgery, Department of Surgery, Faculty of Medicine Siriraj Hospital, Mahidol University, Bangkok 10700, Thailand.

Phone: +66-2-4197998, Fax: +66-2-4129160

E-mail: wslisatkorn@yahoo.com, worawong.sli@mahidol.ac.th

contrast accumulation from CTA (Fig. 2). Although the actual presence of a fistula could not be demonstrated, the diagnosis of TIF was based on 1) a history of massive hemorrhage 2) control of bleeding by cuff hyperinflation and 3) corresponding finding from laryngoscope and CTA.

Because of her severe comorbidity and functional status, endovascular repair with stent graft was chosen. The right axillary artery was accessed and a stent graft (ZSLE-13-39-ZT, Zenith® Spiral-Z™ AAA Iliac-Component, Cook Medical Inc) was used. Aortogram prior stent graft deployment demonstrated no contrast extravasation or pseudoaneurysm formation (Fig. 3). After stenting, aortogram showed no endoleakage and proximal part of stent graft was partially protruded into the aortic arch (Fig. 4). She was doing well after the operation without new neurological deficit and discharge uneventful. CTA neck and thorax was done at one month later and showed no endoleakage or stent migration (Fig. 5). There was a 5 cm short segment of intimal flap along distal right subclavian artery to proximal axillary was found without symptom of ischemic limb. At 3 months after operation, she had no recurrent hemoptysis.

Discussion

Tracheo-innominate artery fistula (TIF) is an uncommon complication (0.1-1%) following both open and percutaneous tracheostomy⁽¹¹⁻¹³⁾. Typically, the injury occurs at the 7th to 9th tracheal ring^(4,5). TIF occurs most frequently (72% of cases) within the first 3 weeks postoperatively but has been reported to occur many months after tracheostomy^(2-5,11). Pressure necrosis from high cuff pressure, mucosal trauma from malpositioned cannula tip, low tracheal incision, excessive neck

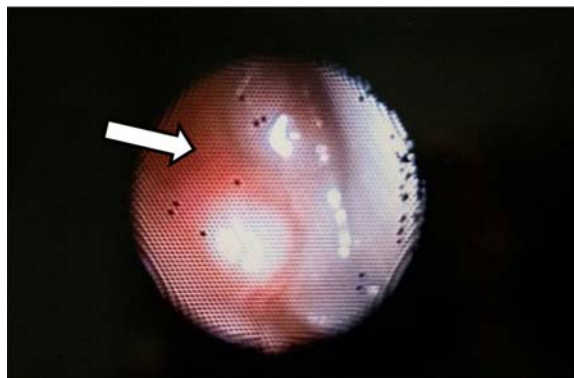


Fig. 2 Finding from laryngoscopy: friable tissue at right anterior aspect of trachea at tracheostomy cuff level (arrow).

movement, radiotherapy or prolonged intubation, infection, hypotension, malnutrition, corticosteroid use, all are risk factors in TIF formation^(5,11,12). Two mechanisms are supposed to be etiology of TIF. First is mechanical force generated by either the

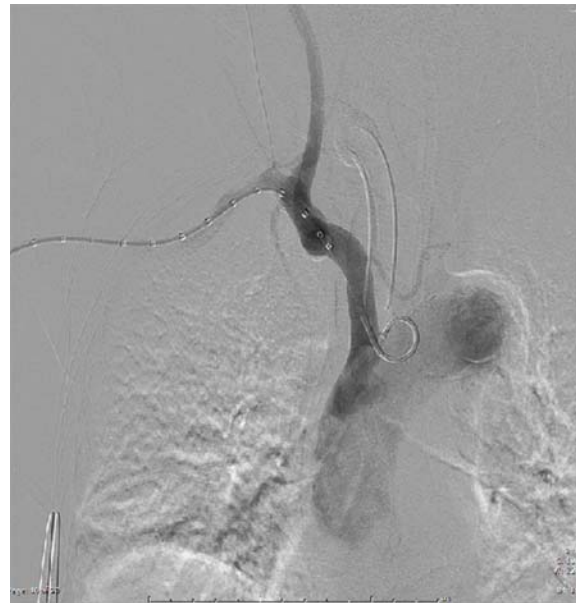

Fig. 3 Aortogram before stent graft deployment showed no contrast extravasation or pseudoaneurysm formation.

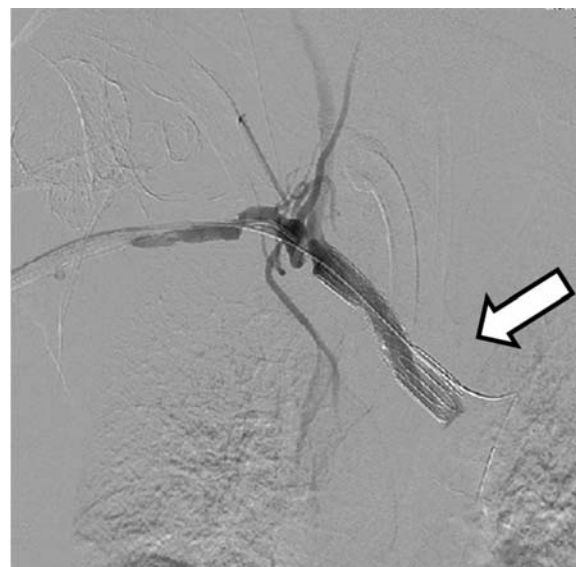


Fig. 4 Aortogram after stenting showed no endoleakage and proximal part of stent graft was partially protruded into the aortic arch (arrow).

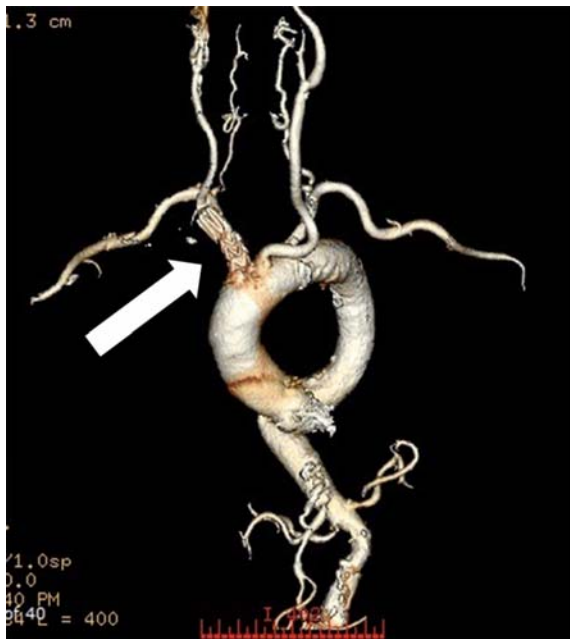

Fig. 5 CTA thoracic aorta at 1 month postoperatively showed no endoleakage and no migration of stent graft.

tracheostomy tube cuff or tube tip. Second mechanism involves pressure generated beneath the angulated neck of a tracheostomy tube produced ischemia anteriorly on the tracheal mucosa and into the innominate artery⁽⁵⁾. Clinical clues suggestive the diagnosis of TIF are bleeding at 48 hours or more after tracheostomy which usual risk and may spontaneously subside, low lying tracheostomy tube, pulsation of tracheostomy tube, present of predisposing factors such as infection, hypotension, malnutrition, corticosteroid use⁽¹²⁾. A sentinel bleed is reported in about 35% of patients and the other 65% of patients first have massive hemorrhage⁽³⁾. Goal of initial management in TIF are 1) control the airway, and 2) tamponade the bleeding while the patient is resuscitated and an OR is prepared⁽²⁾. Over inflating cuff of tracheostomy was recommended to be initial management with 85% rate of success⁽¹¹⁾. If hemorrhage is ongoing, endotracheal tube insertion to protect airway and simultaneous removed tracheostomy tube to maintain ventilation and oxygenation followed by blunt finger dissection of the pretracheal space and manual compression of innominate artery against sternum can control the bleeding before transferred patient to operating room⁽¹⁴⁾. Definitive treatment of TIF requires median sternotomy and ligation of the

innominate artery, buttressed with a muscle flap using the sternocleidomastoid or strap muscles and primary repair trachea after adequate debridement^(2,11,12). Neurological deficit was 4.5% after surgery⁽¹¹⁾. Reconstruction of innominate artery should be avoid because of higher rate of rebleeding and mortality^(3,15). Overall mortality of TIF ranges from 25 to 50% and even successful surgery, longterm survival is poor with 56% of survivors reported dead within 2 months, fewer than 25% still alive at 1 year^(3,4,12). Recently, endovascular techniques have been used to treat a variety of vascular disease. Endovascular repair for TIF is an appealing option because of it can be proceeded after diagnostic angiography, rapidly control hemorrhage, maintain cerebral blood flow and less invasive than open surgery especially in patients who have considerable comorbidity and unstable hemodynamic status. Since Deguchi J, et al reported successful endovascular repair of TIF in 2001⁽⁶⁾, there are 17 reported cases about treatment of endovascular repair as definitive and bridging treatment for open repair in the literature^(6-10,16-24). Age was ranged from 10 to 77 years old. Ten patients (58%) died after operation and two patients (20%) died from stent related complication^(10,23). Four patients had to be converted to open repair and one (25%) of them died later from rebleeding⁽²³⁾. The most longest follow-up period was 4 years⁽²¹⁾. No comparative data about type and period of perioperative antibiotic was concluded. Vascular approach can be done via brachial artery, axillary artery, common carotid and femoral artery. The vascular access was depended on surgeon preference and vascular anatomy. There were two studies using iliac limb stent graft to cover TIF^(22,23). Even mid-term outcome of stenting is comparable to open repair, there are still uncertain area about role of endovascular treatment of TIF as definitive treatment, types of endovascular stent graft, longterm outcome and complication, effect of preoperative antibiotic and patient selection criteria. These issues need to be further investigated.

Conclusion

Tracheo-innominate artery fistula (TIF) is an uncommon but fatal complication after tracheostomy. Early diagnosis and prompt management are key of improvement of patient outcome. Endovascular repair is an alternative modality of treatment of TIF in high surgical risk patient with reasonable mid-term outcome. Potential long-term complication includes neurologic injury, stenosis, infection and recurrence of bleeding should be further evaluated.

What is already known on this topic?

Tracheo-innominate artery fistula (TIF) is an uncommon complication post tracheostomy with high risk of mortality. Open repair is a standard conventional treatment. Endovascular stent grafting was an alternative, less invasive management with an acceptable short and mid-term outcome.

What this study adds?

This study adds more evidence on a rare case of successful treatment of tracheo-innominate artery fistula in a high surgical risk patient in Thailand by using an uncommon type of stent graft to cover the fistula.

Potential conflicts of interest

None.

References

1. De Leyn P, Bedert L, Delcroix M, Depuydt P, Lauwers G, Sokolov Y, et al. Tracheotomy: clinical review and guidelines. *Eur J Cardiothorac Surg* 2007; 32: 412-21.
2. Ailawadi G. Technique for managing tracheo-innominate artery fistula. *Operat Tech Thorac Cardiovasc Surg* 2009; 14: 66-72.
3. Gelman JJ, Aro M, Weiss SM. Tracheo-innominate artery fistula. *J Am Coll Surg* 1994; 179: 626-34.
4. Allan JS, Wright CD. Tracheoinnominate fistula: diagnosis and management. *Chest Surg Clin N Am* 2003; 13: 331-41.
5. Grant CA, Dempsey G, Harrison J, Jones T. Tracheo-innominate artery fistula after percutaneous tracheostomy: three case reports and a clinical review. *Br J Anaesth* 2006; 96: 127-31.
6. Deguchi J, Furuya T, Tanaka N, Nobori M, Seki Y, Nomura Y, et al. Successful management of tracheo-innominate artery fistula with endovascular stent graft repair. *J Vasc Surg* 2001; 33: 1280-2.
7. Vianello A, Ragazzi R, Mirri L, Arcaro G, Cutrone C, Fitta C. Tracheoinnominate fistula in a Duchenne muscular dystrophy patient: successful management with an endovascular stent. *Neuromuscul Disord* 2005; 15: 569-71.
8. Palchik E, Bakken AM, Saad N, Saad WE, Davies MG. Endovascular treatment of tracheoinnominate artery fistula: a case report. *Vasc Endovascular Surg* 2007; 41: 258-61.
9. Cohen JE, Klimov A, Rajz G, Paldor I, Spektor S. Exsanguinating tracheoinnominate artery fistula repaired with endovascular stent-graft. *Surg Neurol* 2008; 69: 306-9.
10. Wang PK, Yen PS, Shyr MH, Chen TY, Chen A, Liu HT. Endovascular repair of tracheo-innominate artery fistula. *Acta Anaesthesiol Taiwan* 2009; 47: 36-9.
11. Jones JW, Reynolds M, Hewitt RL, Drapanas T. Tracheo-innominate artery erosion: Successful surgical management of a devastating complication. *Ann Surg* 1976; 184: 194-204.
12. Schaefer OP, Irwin RS. Tracheoarterial fistula: an unusual complication of tracheostomy. *J Intensive Care Med* 1995; 10: 64-75.
13. Goldenberg D, Ari EG, Golz A, Danino J, Netzer A, Joachims HZ. Tracheotomy complications: a retrospective study of 1130 cases. *Otolaryngol Head Neck Surg* 2000; 123: 495-500.
14. Utley JR, Singer MM, Roe BB, Fraser DG, Dedo HH. Definitive management of innominate artery hemorrhage complicating tracheostomy. *JAMA* 1972; 220: 577-9.
15. Yang FY, Criado E, Schwartz JA, Keagy BA, Wilcox BR. Trachea-innominate artery fistula: retrospective comparison of treatment methods. *South Med J* 1988; 81: 701-6.
16. Sorial E, Valentino J, Given CA, Endean ED, Minion DJ. The emergency use of endografts in the carotid circulation to control hemorrhage in potentially contaminated fields. *J Vasc Surg* 2007; 46: 792-8.
17. Wall LP, Gasparis A, Criado E. Endovascular therapy for tracheoinnominate artery fistula: a temporizing measure. *Ann Vasc Surg* 2005; 19: 99-102.
18. Sessa C, Costache V, Porcu P, Thony F, Blin D, Brichon PY, et al. Tracheoinnominate artery fistula: combined endovascular and surgical management by emergency stent-graft placement followed by cryopreserved arterial allograft repair. *Ann Vasc Surg* 2006; 20: 731-5.
19. Joshi AS, Tanna N, Elmaraghy CA, Obokhare I, Ponsky TA, Pena MT, et al. Nonsurgical treatment of tracheoinnominate fistula in the pediatric population. *Arch Otolaryngol Head Neck Surg* 2007; 133: 294-6.
20. Guimaraes M, Schonholz C, Phifer T, D'Agostino H. Endovascular repair of a tracheoinnominate fistula with a stent graft. *Vascular* 2008; 16: 287-90.
21. Shepard PM, Phillips JM, Tefera G, Hartig GK. Tracheoinnominate fistula: successful management with endovascular stenting. *Ear Nose Throat J* 2011; 90: 310-2.

22. Nakai M, Sato H, Sato M, Ikoma A, Sanda H, Nakata K, et al. Tracheo-innominate artery fistula successfully treated by endovascular stent-graft repair. *Jpn J Radiol* 2013; 31: 65-70.
23. Troutman DA, Dougherty MJ, Spivack AI, Calligaro KD. Stent graft placement for a tracheoinnominate artery fistula. *Ann Vasc Surg* 2014;28: 1037-4.
24. Ahn HY, Son BS, Kim DH. Recurrent Tracheoinnominate Artery Fistula due to Stent Graft Fracture. *European J Pediatr Surg Rep* 2015; 3: 12-4.

รายงานความสำเร็จการรักษาผู้ป่วยที่มี Tracheo-innominate artery fistula ด้วยวิธี endovascular stent grafting

ยุทธสินธุ์ วงศ์แสงคำ, วันชัย วงศ์กรรัตน์, วรวงษ์ ศลิษฏอรรถกร

Tracheo-innominate artery fistula (TIF) เป็นภาวะแทรกซ้อนภายหลังการทำ tracheostomy ที่พบไม่บ่อยแต่มีอัตราการเสียชีวิตสูง แนวทางหลักของการรักษา Tracheo-innominate artery fistula (TIF) คือการผูกหลอดเลือดแดง innominate ผ่านแผล median sternotomy ผู้ป่วยส่วนใหญ่มักมีโรคร่วมหลายอย่างและมีสัญญาณชีพไม่คงที่ ซึ่งมีความเสี่ยงสูงต่อการรักษาโดยวิธีการผ่าตัดในการศึกษานี้รายงานถึงความสำเร็จของการรักษา Tracheo-innominate artery fistula (TIF) ด้วยวิธี endovascular stent grafting