

Case Report

Severe Deferiprone-Induced Arthropathy in Young Adolescent Successfully Treated with Intraarticular Triamcinolone Acetonide Injection: A Case Report

Jassada Buaboornam MD*,
Sirirat Charuvanij MD**

* Division of Hematology and Oncology, Department of Pediatrics, Faculty of Medicine Siriraj Hospital, Mahidol University, Bangkok, Thailand

** Division of Rheumatology, Department of Pediatrics, Faculty of Medicine Siriraj Hospital, Mahidol University, Bangkok, Thailand

Deferiprone (DFP), an oral chelation therapy, has improved treatment adherence and quality of life of transfusion dependent thalassemia (TDT). DFP-induced arthropathy is usually mild and self-limited; the severe DFP-induced arthropathy is uncommon presentation. Herein, a Thai girl diagnosed as TDT was initially treated with DFP. She subsequently developed severe DFP-induced bilateral knee arthritis despite discontinuing DFP and using non-steroidal anti-inflammatory drugs (NSAIDs). She was treated with arthrocentesis and intraarticular triamcinolone acetonide injection and responded well to the treatment.

Keywords: Deferiprone, Thalassemia, Arthropathy, Triamcinolone acetonide

J Med Assoc Thai 2017; 100 (7): 815-7

Full text. e-Journal: <http://www.jmatonline.com>

Regular transfusion is essential for transfusion dependent thalassemia (TDT) patients particularly in children since it can maintain the normal growth and development. However, the accumulation of iron from transfused erythron can cause iron overload ultimately damaging several organs such as liver and heart. To prevent such complications, iron chelation therapy must be prescribed for TDT patients. Deferiprone (DFP), one of the oral chelators, has widely been used since it is effective in chelating cardiac irons⁽¹⁾. Arthropathy is one of the major adverse events, apart from neutropenia and hepatitis, which occurs ranging from 3% to 38%⁽²⁻⁴⁾. We, herein, report a 12-year old Thai girl with TDT who suffered from severe DFP-induced arthritis and successfully treated with arthrocentesis and intraarticular triamcinolone acetonide injection.

Case Report

A 12-year-old Thai girl diagnosed with transfusion dependent beta thalassemia had been on

regular 4-week transfusion in a provincial hospital since three years of age. At the age of 11, she developed iron overload; her serum ferritin was 2,461 ng/ml and she had been treated with deferiprone (DFP), the oral iron chelator, at 60 mg/kg/day. One year after iron chelator treatment, she experienced progressive bilateral arthritis of the knees; she neither had history of trauma nor preceding infection before the onset of arthritis. DFP was on hold by the physician at provincial hospital and she was treated with ibuprofen orally for two weeks. Her symptoms, however, persisted and she was referred to our hospital for further management. After discontinuing DFP for three months, she had ongoing bilateral knee pain and difficulty walking. Physical examination was unremarkable except for mild pallor and hepatosplenomegaly. On musculoskeletal examination, she had bilateral swelling and tender with limitation of knee movements. Other joints were unremarkable. She had no enthesitis. Plain radiograph showed bilateral knee joint effusion without any bony changes (Fig. 1). Laboratory findings revealed hemoglobin 8.2 g/dl, white blood cell 7,390/mm³ (neutrophil 39%, lymphocyte 55%, monocyte 5%), platelets 177,000/mm³, TB 2.0 mg/dl, DB 0.61 mg/dl, SGOT 134 U/l, SGPT 154 U/l, AP 232 U/l, erythrocyte sedimentation rate (ESR) 15 mm/hour, C reactive protein (CRP) 1 mg/l, Viral hepatitis profile were unremarkable.

Correspondence to:

Charuvanij S, Division of Rheumatology, Department of Pediatrics, Faculty of Medicine Siriraj Hospital, Mahidol University, Bangkok 10700, Thailand.

Phone: +66-2-4195655

E-mail: sirirat.chv@mahidol.ac.th

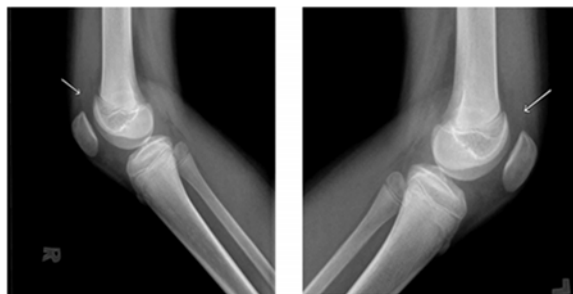


Fig. 1 Bilateral knee joint effusion.

Rheumatoid factor, antinuclear antibody (ANA) and human leukocyte antigen-B27 (HLA-B27) were all negative. A purified protein derivative (PPD) was negative. Slit-lamp examination revealed no evidence of uveitis. Arthrocentesis was then performed to exclude intraarticular chronic infection and sent for synovial analysis. The straw-colored synovial fluid was aspirated 24 ml and 22 ml from right and left knee, respectively. The synovial fluid analysis from each side revealed the number of nucleated cell 285 and 325 cell/mm³ with lymphocytic predominance at 95% and 92%, respectively. Synovial fluid gram and acid-fast bacilli stains were negative. The culture of synovial fluid for bacteria and mycobacterial studies were negative. She was unable to treat with non-steroid anti-inflammatory drugs (NSAIDs) in lights of the elevation of transaminase enzymes. DFP was substituted by subcutaneous injection of deferoxamine (DFO), the parenteral iron chelator. During the follow-up visit two weeks later, her arthritis and transaminitis had persisted. Upon discussion with and approval from her parents, she underwent bilateral knee arthrocentesis with intraarticular injection of triamcinolone acetonide 40 mg each side. She responded well to given procedure without any complications. At six-week follow-up, she had no joint symptoms and she could walk well.

Discussion

Survival and quality of life of TDT patients improve drastically after the arrival of chelation therapy since it can prevent visceral organ damages secondary to iron overload resulting from regular transfusion. DFP is the iron chelation commonly used since it is conveniently administered compared to DFO, the first-generation iron chelator which must be given intravenously or subcutaneously.

DFP-induced arthropathy is one of the most common undesirable effects; the incidence varies among the studies, ranging from 3 to 38%⁽²⁻⁴⁾ and

typically involves large joints^(5,6). The symptoms are usually mild and can be managed by DFP withdrawal and NSAIDs administration^(4,7), the incidence of severe arthropathy is rarely reported⁽⁸⁾. In presented patient, her symptoms persisted despite discontinuing DFP; additionally, she had transminitis, which contraindicated the use of NSAIDs. Thus, the alternative treatment i.e., arthrocentesis with intra-articular steroid injection, was introduced.

The pathophysiology of DFP-related arthropathy is not well elucidated. One of the possible mechanisms is that DFP leads to the shift of iron to synovium and subsequently forms the incomplete bidentate-iron complex, which generates free radical ultimately rendering tissue damage⁽⁷⁾. In histopathologic result, it revealed synovial lining cell proliferation with increased iron deposition, without obvious evidence of inflammation⁽⁷⁾. The other proposed mechanism includes the anti-proliferative properties of DFP on the growth cartilages⁽⁹⁾. The abnormal radiographic findings of DFP-related arthropathy include joint effusion, subchondral bone irregularity, and thickening with enhancing of the synovium^(5,10). The deformities of physal cartilages of ulnar bone and subchondral flattening of femoral and tibial condyle are also observed in Indian TDT patients⁽⁹⁾. However, our patient had only joint effusion on plain radiograph without typical bony abnormality. This may reflect early evidence of arthropathy.

Juvenile idiopathic arthritis (JIA) is another diagnosis possibility in this patient. JIA is chronic arthritis of unknown etiology affecting children less than 16 years of age⁽¹¹⁾. However, given the lack of morning stiffness and gelling phenomenon which indicate inflammatory arthritis as well as the non-inflammatory type of synovial fluid, this patient was unlikely to be JIA.

In conclusion, although DFP-related arthropathy is usually not serious, few patients might develop severe manifestation. Intraarticular steroid injection can be used as an alternative option in those with contraindication to NSAIDs treatment.

What is already known on this topic?

DFP-induced arthropathy is usually mild and self-limited. It can be treated with NSAIDs and the withdrawal of DFP.

What this study adds?

Albeit rare, severe manifestation of DFP-related arthropathy can occur in TDT patients treated

with DFP. Alternative management i.e., arthrocentesis with intraarticular steroid injection may yield encouraging results.

Potential conflicts of interest

None.

References

1. Piga A, Gaglioti C, Fogliacco E, Tricta F. Comparative effects of deferiprone and deferoxamine on survival and cardiac disease in patients with thalassemia major: a retrospective analysis. *Haematologica* 2003; 88: 489-96.
2. Viprakasit V, Nuchprayoon I, Chuansumrit A, Torcharus K, Pongtanakul B, Laothamatas J, et al. Deferiprone (GPO-L-ONE((R))) monotherapy reduces iron overload in transfusion-dependent thalassemias: 1-year results from a multicenter prospective, single arm, open label, dose escalating phase III pediatric study (GPO-L-ONE; A001) from Thailand. *Am J Hematol* 2013; 88: 251-60.
3. Choudhry VP, Pati HP, Saxena A, Malaviya AN. Deferiprone, efficacy and safety. *Indian J Pediatr* 2004; 71: 213-6.
4. Naithani R, Chandra J, Sharma S. Safety of oral iron chelator deferiprone in young thalassaemics. *Eur J Haematol* 2005; 74: 217-20.
5. Kellenberger CJ, Schmugge M, Saurenmann T, Di Gennaro L, Eber SW, Willi UV, et al. Radiographic and MRI features of deferiprone-related arthropathy of the knees in patients with beta-thalassemia. *AJR Am J Roentgenol* 2004; 183: 989-94.
6. Vlachaki E, Tselios K, Perifanis V, Tsatra I, Tsayas I. Deferiprone-related arthropathy of the knee in a thalassaemic patient: report of a case and review of the literature. *Clin Rheumatol* 2008; 27: 1459-61.
7. Berkovitch M, Laxer RM, Inman R, Koren G, Pritzker KP, Fritzler MJ, et al. Arthropathy in thalassaemia patients receiving deferiprone. *Lancet* 1994; 343: 1471-2.
8. al Refaie FN, Hershko C, Hoffbrand AV, Kosaryan M, Olivieri NF, Tondury P, et al. Results of long-term deferiprone (L1) therapy: a report by the International Study Group on Oral Iron Chelators. *Br J Haematol* 1995; 91: 224-9.
9. Sharma R, Anand R, Chandra J, Seth A, Pemde H, Singh V. Distal ulnar changes in children with thalassemia and deferiprone related arthropathy. *Pediatr Blood Cancer* 2013; 60: 1957-62.
10. Chand G, Chowdhury V, Manchanda A, Singh S. Deferiprone-induced arthropathy in thalassemia: MRI findings in a case. *Indian J Radiol Imaging* 2009; 19: 155-7.
11. Petty RE, Southwood TR, Manners P, Baum J, Glass DN, Goldenberg J, et al. International League of Associations for Rheumatology classification of juvenile idiopathic arthritis: second revision, Edmonton, 2001. *J Rheumatol* 2004; 31: 390-2.

ภาวะข้อผิดปกติรุนแรงที่เกิดจากการใช้ยาดีเฟอริพرونในผู้ป่วยวัยรุ่นซึ่งตอบสนองต่อการฉีดยาไตรแอมซิโนโลนอะเซโดไนด์
เข้าข้อ: รายงานผู้ป่วย

เจษฎา บัวบุญนำ, ศิริรัตน์ จารุณิช

ดีเฟอริพرونซึ่งเป็นยาขับเหล็กชนิดรับประทานสำหรับผู้ป่วยธาลัสซีเมียที่ต้องรับเลือดเป็นประจำสามารถรับยาได้สม่ำเสมอ และมีคุณภาพชีวิตที่ดีขึ้นภาวะข้อผิดปกติที่เกิดจากยาดีเฟอริพرونส่วนใหญ่อาการไม่รุนแรงและหายได้เอง ภาวะข้อผิดปกติรุนแรงเป็นอาการแสดงที่พบได้น้อย รายงานนี้ได้อภิปรายผู้ป่วยเด็กหญิงธาลัสซีเมีย 1 ราย ที่ได้รับเลือดสม่ำเสมอและได้รับยาดีเฟอริพرونเพื่อขับเหล็กต่อมาผู้ป่วยเกิดอาการปวดเข่าทั้ง 2 ข้าง ซึ่งสัมพันธ์กับยาดีเฟอริพرون ผู้ป่วยยังคงมีอาการปวดเข่าแม้ว่าผู้ป่วยหยุดยาดีเฟอริพرونและได้รับยาไอบูโพรเฟน ผู้ป่วยจึงได้รับการรักษาด้วยการเจาะน้ำในข้อร่วมกับการฉีดยาไตรแอมซิโนโลนอะเซโดไนด์เข้าข้อเข่าทั้ง 2 ข้างและผู้ป่วยตอบสนองดีต่อการรักษา