

# Outcome of Urgent Penetrating Keratoplasty for Corneal Ulcer at Thammasat University Hospital

Wimolwan Tangpagasit MD\*,  
Thanichaya Reanpinyawat MD\*\*

\* Department of Ophthalmology, Faculty of Medicine, Thammasat University Hospital,  
Thammasat University, Pathumthani, Thailand

\*\* Department of Ophthalmology, Rayong Hospital, Rayong, Thailand

---

**Objective:** To determine the eye integrity preservation after urgent penetrating keratoplasty (PKP) for corneal ulcer at Thammasat University Hospital.

**Material and Method:** A retrospective review of patients who underwent urgent PKP between September 2005 and January 2015 was conducted. Demographic data, predisposing factors, organisms, indication for surgery, time of urgent corneal graft registry, and preservation rate of eye integrity were analyzed.

**Results:** Fifty-five patients (55 eyes) registered for urgent corneal graft registry from eye bank and 22 eyes underwent urgent PKP. There were 14 males (63.6%) and 8 females (36.4%). A mean age was  $55.9 \pm 15.4$  years. The most common predisposing factor was ocular trauma in 11 eyes (50.0%) and the most common indication for surgery was severe corneal ulcer in 11 eyes (50.0%). The mean time of urgent corneal graft registry was  $22.1 \pm 17.2$  days (3-70 days). The present study could preserve eye integrity in post urgent PKP in 18 eyes (81.8%). Other 4 eyes (18.2%) could not preserve the eye integrity.

In 33 eyes who did not undergo urgent PKP, 20 eyes (60.6%) could preserve eye integrity, 10 eyes (30.3%) underwent primary evisceration and 3 eyes (9.1%) underwent primary enucleation due to extensive ocular infection.

**Conclusion:** Urgent PKP of corneal ulcer could provide satisfactory in eye integrity preservation.

**Keywords:** Urgent penetrating keratoplasty, Corneal ulcer

*J Med Assoc Thai* 2016; 99 (1): 71-6

Full text. e-Journal: <http://www.jmatonline.com>

---

Corneal ulcer is a common cause of vision threatening. There are many causative organisms according to different countries<sup>(1)</sup>. The majority of patients have predisposing factor that affect the causative organism and clinical course. If corneal ulcer progressed and did not noticeably improve with medication, then, the surgical intervention is required. Penetrating keratoplasty (PKP) is an effective surgical intervention for improving visual function in corneal ulcer<sup>(2)</sup>. Pariyakonok et al<sup>(3)</sup> studied indications for PKP in Thailand between 1996 and 2008 and found that corneal ulcer was the second common indication. The Thai Red Cross Eye Bank provides the corneal donor tissues and the recipients will be received the donor tissue based on their different urgencies<sup>(3)</sup>. The previous study in Thammasat University Hospital reported most of the referred patients from other hospitals had

severe corneal ulcer<sup>(4)</sup>. Common indications of urgent PKP were tectonic reason for impending perforated or perforated corneal ulcer cases, and therapeutic reason for uncontrolled severe corneal ulcer.

Due to the limitation of donor tissue availability, some cases that registered for urgent PKP had rapidly progression and required evisceration or enucleation to manage uncontrolled corneal infection. No previous study of urgent PKP in corneal ulcer had been performed. Therefore, the purpose of the present study was to retrospectively review demographic data, age, predisposing factors, causative organisms, indication for surgery, time of urgent corneal graft registry, and preservation of eye integrity in postoperative period.

## Material and Method

The present study was conducted in accordance to the tenets of the Declaration of Helsinki and approved by the Research Ethic Committee of Thammasat University Hospital, Thammasat University (MTU-EC-OP-0-123/57). The donor corneal tissues were supported by the Thai Red Cross Eye Bank. The authors reviewed the medical records of all patients who

---

### Correspondence to:

Tangpagasit W, Department of Ophthalmology, Faculty of Medicine, Thammasat University Hospital, Thammasat University, Pathumthani 12120, Thailand.

Phone: +66-2-9269957, Fax: +66-2-9869212

E-mail: [twimolwan@gmail.com](mailto:twimolwan@gmail.com)

registered for urgent corneal graft between September 2005 and January 2015. The inclusion criteria were patients who were eligible for urgent corneal graft registry and follow-up at least three months after PKP. The patients with less than three months follow-up were excluded from the study. The indications for urgent PKP were 1) impending perforated corneal ulcer referred to as any ulcerations with severe stromal thinning (more than 90%) or descemetocoele which defined as anterior bulging of an intact descemet membrane through a defect of the overlying corneal stromal and epithelial layer, 2) perforated corneal ulcer referred to a full-thickness defect in the cornea with the communication between the anterior chamber and the ocular surface, and 3) severe corneal ulcer referred to a rapidly progressing infiltrate which was more than 6 mm in diameter or involved deeper stroma more than 2/3 thickness or hypopyon that was unresponsive to medical treatment within 72 hours<sup>(5,6)</sup>.

The demographic data included gender, age, history of predisposing factors, indication for surgery, time of urgent corneal graft registry, and corneal scraping result for staining and culture were recorded. Preservation of globe integrity and postoperative corneal graft complication were recorded at 3-month follow-up. The corneal graft clarity and graft complications were assessed by slit-lamp biomicroscope at each visit. Corneal graft infection referred to infiltration of graft bed, corneal graft, and anterior chamber reaction. Corneal graft rejection could be grouped into three types 1) epithelial rejection referred to epithelial rejection line appearing, 2) stromal rejection referred to stromal infiltrates

and vessels appearing, and 3) endothelial rejection referred to cellular infiltrates aggregate on the endothelium that appeared as scattered deposits or a distinct Khodadoust line<sup>(7,8)</sup>. Corneal graft failure referred by the definition used in the Collaborative Corneal Transplantation Studies (CCTS), was a regrant or, in the absence of regrant, a cloudy cornea in which there was loss of central graft clarity sufficient to compromise vision for a minimum of three consecutive months<sup>(9,10)</sup>. Statistical analysis was calculated using Microsoft Excel 2010 and SPSS21. Analyzed data were shown in number and percentage, mean, standard deviation (SD) or median and range and Pearson's Chi-square test.

## Results

Fifty-five patients (55 eyes) registered for urgent corneal graft registry from eye bank. Only twenty-two patients (22 eyes) received corneal graft and underwent PKP, which were 14 males (63.6%) and 8 females (36.4%). A mean age was 55.9±15.4 years (range 30 to 91 years).

### *Predisposing factor and microbiological study*

Twenty-two eyes underwent urgent PKP. The predisposing factors were ocular trauma in eleven eyes (50.0%), previous ocular surgery in one eye (4.5%), ocular surface disease in one eye (4.5%), and undetermined factors in nine eyes (40.9%).

The causative organisms (PKP group) were fungus in seven eyes (31.8%), bacteria in two eyes (9.1%), and culture negative in thirteen eyes (59.1%), as shown in Table 1.

**Table 1.** Micro-organisms isolated from patients

Organisms	Total (n = 55) number of eyes (%)	PKP group (n = 22) number of eyes (%)	No PKP group (n = 33) number of eyes (%)
Fungus	15 (27.3)	7 (31.8)	8 (24.2)
<i>Aspergillus flavus</i>	5 (9.1)	1 (4.5)	4 (12.1)
<i>Fusarium</i> spp.	4 (7.3)	2 (9.1)	2 (6.1)
<i>Penicillium</i> spp.	2 (3.6)	2 (9.1)	0 (0.0)
<i>Pythium</i> spp.	1 (1.8)	1 (4.5)	0 (0.0)
Dermatititious fungi	2 (3.6)	1 (4.5)	1 (3.0)
<i>Curvularia</i> spp.	1 (1.8)	0 (0.0)	1 (3.0)
Bacteria	9 (16.4)	2 (9.1)	7 (21.2)
Coagulase negative <i>Staphylococcus</i>	1 (1.8)	1 (4.5)	0 (0.0)
<i>Pseudomonas aeruginosa</i>	4 (7.3)	0 (0.0)	4 (12.1)
<i>Proteus mirabilis</i>	1 (1.8)	0 (0.0)	1 (3.0)
<i>Mycobacterium</i> spp.	2 (3.6)	0 (0.0)	2 (6.1)
<i>Acinetobacter baumannii</i>	1 (1.8)	1 (4.5)	0 (0.0)
Culture negative	31 (56.4)	13 (59.1)	18 (54.5)

PKP = penetrating keratoplasty

Thirty-three eyes did not receive urgent PKP. The predisposing factor were the ocular trauma in 20 eyes (60.6%), chemical burn in 2 eyes (6.1%), contact lens usage in 2 eyes (6.1%), previous ocular surgery in 2 eyes (6.1%), ocular surface disease in 1 eye (3.0%), and undetermined factors in 6 eyes (18.1%).

The causative organisms (non-PKP group) were fungus in 8 eyes (24.2%), bacteria in 7 eyes (21.2%), and culture negative in 18 eyes (54.5%), as shown in Table 1.

### Treatment and clinical outcomes

In PKP group, the indications for surgery were: severe corneal ulcer in 11 eyes (50.0%), perforated corneal ulcer in 10 eyes (45.5%), and impending perforated corneal ulcer in 1 eye (4.5%), as shown in Table 2. The mean time of urgent corneal graft registry was  $22.1 \pm 17.2$  days (3-70 days). The mean follow-up period was 18 months (3-65 months).

Considering visual acuity (VA) at presentation, initial VA was poorer than hand motion (HM) of all cases. After 22 patients underwent urgent PKP, the best final VA were in the 20/70 to 20/200 range in three eyes (13.7%) and most of them had light perception (PL) as shown in Fig. 1.

The present study demonstrated that urgent PKP could preserve eye integrity in 18 eyes (81.8%). Post-operative graft complications were vascularized. Graft edema and cloudy cornea substantially increased the graft failure in 15 eyes (68.2%). The other three eyes (13.7%) had successful PKP without corneal graft complications as shown in Table 3 ( $p = 0.095$ ).

Three eyes (13.7%) underwent secondary evisceration and one eye (4.5%) underwent secondary enucleation from developing ocular pythiosis, as shown in Fig. 2. All cases had large corneal infiltration of at least 6.0 mm, descematocele of at least 2.5 mm, hypopyon of at least 2.0 mm at the first visit, and slightly small recipient size of 6.5 mm.

In non-PKP group, 33 eyes from 55 eyes did not receive urgent PKP due to some patients responded to medications and some patients developed progressive ocular infection.

Twenty eyes (60.6%) could preserve eye integrity. In these 20 eyes, 3 eyes (9.1%) underwent corneoscleral patch graft, 3 eyes (9.1%) underwent glue application as shown in Table 3, and other 14 eyes (42.4%) received successful medical treatment without surgical intervention. Final VA, most of them were poorer than finger count as shown in Fig. 1 ( $p = 0.095$ ).

**Table 2.** Indication of corneal graft registry in patients who underwent urgent PKP

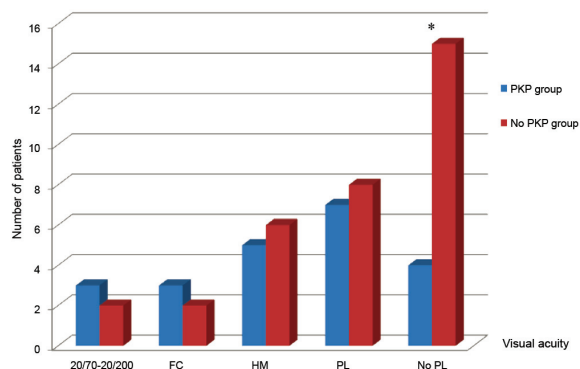
Indication for urgent corneal graft registry	PKP group (n = 22) number of eyes (%)
Severe corneal ulcer	11 (50.0)
Perforated corneal ulcer	10 (45.5)
Impending perforated corneal ulcer	1 (4.5)

Ten eyes (30.3%) underwent primary evisceration and three eyes (9.1%) underwent primary enucleation due to extensive ocular infection as shown in Table 3 and Fig. 3 ( $p = 0.090$ ).

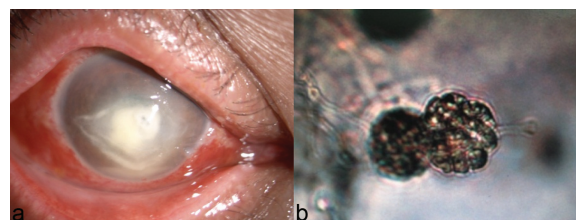
### Discussion

The authors reported the preservation of eye integrity of urgent PKP in corneal ulcer. The present study demonstrated that the ocular trauma was the most common predisposing factor of corneal ulcer.

*Aspergillus* spp., *Fusarium* spp., and *Penicillium* spp. were common fungal causative organisms. Tananuvat et al reported ocular trauma was the most common predisposing factor leading to microbial keratitis in the northern Thailand, which



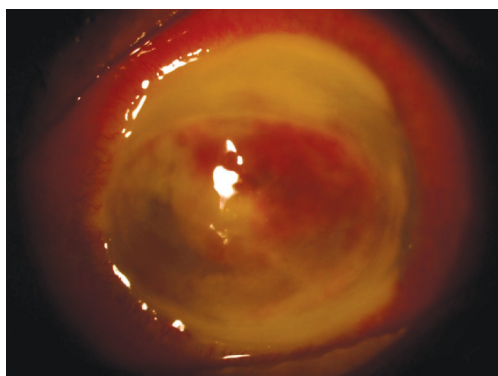
**Fig. 1** Final visual acuity (\* Chi-square test  $p < 0.05$ ).



**Fig. 2** a) Severe corneal ulcer; full-thickness corneal infiltrate 6.1\*4.3 mm, epithelial defect 8.4\*5.6 mm, hypopyon 2 mm, and descemtocele 2.6 mm (*Pythium insidiosum*). b) Formation of the *Pythium insidiosum*'s sporangia and zoospores.

**Table 3.** Postoperative data of patients

	PKP group (n = 22) number of eyes (%)	Non PKP group (n = 33) number of eyes (%)
Preserve eye integrity	18 (81.8)	20 (60.6)
Graft failure	15 (68.2)	0 (0.0)
Successful PK	3 (13.7)	0 (0.0)
Corneoscleral patch graft	0 (0.0)	3 (9.1)
Glue application	0 (0.0)	3 (9.1)
Secondary glaucoma	13 (59.1)	18 (54.5)
Unpreserved eye integrity	4 (18.1)	13 (39.4)
Evisceration	3 (13.7)	10 (30.3)
Enucleation	1 (4.5)	3 (9.1)

**Fig. 3** Ocular *Aspergillus* infection. Total corneal infiltration that extended beyond to limbus and sclera, massive hyphema and hypopyon.

*Fusarium* spp. was the most common fungal organism<sup>(11)</sup>. These results similar to the present study even in different geographic regions. In addition, majority of corneal ulcers were referred from local hospital and already received previous treatment, this might be the reasons why the culture negative cases were more than half of patients in the present study.

The present study demonstrated that severe corneal ulcer was the most common indication for urgent PKP. Sedghipour et al reported a retrospective study evaluating outcome of PKP in the series of 33 corneal ulcer patients and found the most common indication for PKP was perforated corneal ulcer<sup>(12)</sup>. However, indications for PKP may be different in each country. In Thailand, the only one eye bank for giving donor tissues, distributes the donor corneal tissue base on the sequence of registration and urgent indication. Regarding to the small number of corneal donor in Thailand, the mean timing of corneal graft registry before urgent PKP in the present study was about three weeks, but the range of timing was wide.

Due to the expected timing of urgent corneal registry before PKP the patients in the present study were received corneal registry early especially in cases with severe corneal ulcer. This might explain why the most common indication for urgent PKP in the present study was different from the previous study.

After the patients received urgent PKP, we could preserve eye integrity in 18 eyes whom received donor size more than 7.0 mm. Bourne<sup>(13)</sup> established the importance of corneal endothelium in PKP. Large donor size diameter may have more surface area of endothelial cells than a graft of small diameter. This may explain that 18 eyes could preserve eye integrity may due to larger donor size, which having higher number of endothelial cells.

In PKP group, four patients underwent secondary evisceration or enucleation. All cases had severe fungal ulcers. These four eyes could not preserve eye integrity due to large corneal infiltration, severe anterior chamber reaction, and a 6.5 mm recipient size. Subsequent removal of the contents of the eye or the entire eye was performed. Therefore, we should perform urgent PKP in large recipient size. Severe fungal corneal ulcers were the major cause of urgent PKP because of the poor prognosis.

The mean post-PKP follow-up period was 18 months. Post-operative graft failure was the most common among these cases. Alldrege and Krachmer reported the patients with corneal ulcer had severe ocular surface inflammation and vascularized cornea, which represented poor prognosis for PKP<sup>(14)</sup>. Most patients did not receive corticosteroids to suppress inflammation in early postoperative period because of awareness of the graft infection. Chronic inflammation and factors such as anterior synechiae and poorly controlled intraocular pressure may have contributed to graft failure<sup>(15)</sup>. Moreover, the donor corneal tissues were of less quality based on their urgent indication. The high quality graft was preserved for patients who had better prognosis. Boujemaa et al reported outcomes of urgent PKP in seven eyes of seven patients who had perforated corneal ulcers<sup>(16)</sup>. The study defined anatomical success by eradication of infection and preservation of the eye from enucleation and phthisis bulbi. They also defined corneal graft survival by the presence of a clear graft and found anatomical success in six eyes with graft survival in two eyes during the mean follow-up period of 22 months. This might explain their success on urgent PKP without corneal graft complication in only few cases, which is similar to the previous study. Considering the final VA in both



groups, the study demonstrated that in PKP group had final VA in range of 20/70 to finger count more than in non-PKP group ( $p = 0.33$ ), and clinical significant for no PL in non-PKP group when compared to PKP group ( $p = 0.04$ ).

In non-PKP group, 13 patients (39.4%) could not preserve eye integrity because they developed extended persistent epithelial defect and progressive ocular infection before performing urgent PKP.

The limitation of the present study was the retrospective design and small sample size.

### Conclusion

The present study demonstrated that urgent PKP of severe corneal ulcer could provide satisfactory eye integrity preservation.

### What is already known on this topic?

Urgent PKP can preserve eye integrity and eradicate the infectious process in perforated infectious corneal ulcer.

### What this study adds?

The present study provided a guide for preservation of eye integrity in patients with corneal ulcer. The patients would be informed about the common infectious organism, the waiting time of urgent corneal graft registry, and the management in case they did not receive urgent PKP.

### Acknowledgements

The present study was supported by the Faculty of Medicine Fund for Medical Research, Thammasat University, Pathumthani, Thailand.

### Potential conflicts of interest

None.

### References

1. Reddy SC, Tajunisah I. Indications for penetrating keratoplasty in west Malaysia. *Int J Ophthalmol* 2008; 1: 125-8.
2. Ausayakhun S, Juntaramanee J. Clinical indications for penetrating keratoplasty in Maharaj Nakorn Chaing Mai Hospital, 1990-1995. *Thai J Ophthalmol* 1997; 11: 17-23.
3. Pariyakanok L, Erjongmanee S, Saonanon P. Indications for corneal transplantation in Thailand between 1996 and 2008. *Asian Biomed* 2011; 6: 843-8.
4. Kampitak K, Patrasuwan S, Kongsomboon K. Cost evaluation of corneal ulcer treatment. *J Med Assoc Thai* 2013; 96: 456-9.
5. Marc AH, Christopher JR. Management of corneal perforations. In: Krashmer JH, Mannis MJ, Holland EJ, editors. *Cornea*. 2nd ed. Philadelphia: Mosby; 2005: 1669-84.
6. Garg P, Rao GN. Corneal ulcer: diagnosis and management. *Community Eye Health* 1999; 12: 21-3.
7. Dua HS, Azuara-Blanco A. Corneal allograft rejection: risk factors, diagnosis, prevention, and treatment. *Indian J Ophthalmol* 1999; 47: 3-9.
8. Hassan SS, Wilhelmus KR, Dahl P, Davis GC, Roberts RT, Ross KW, et al. Infectious disease risk factors of corneal graft donors. *Arch Ophthalmol* 2008; 126: 235-9.
9. Li C, Zhao GQ, Che CY, Lin J, Li N, Jia WY, et al. Effect of corneal graft diameter on therapeutic penetrating keratoplasty for fungal keratitis. *Int J Ophthalmol* 2012; 5: 698-703.
10. Sugar A, Tanner JP, Dontchev M, Tennant B, Schultze RL, Dunn SP, et al. Recipient risk factors for graft failure in the cornea donor study. *Ophthalmology* 2009; 116: 1023-8.
11. Tananuvat N, Punyakhum O, Ausayakhun S, Chaidaroon W. Etiology and clinical outcomes of microbial keratitis at a tertiary eye-care center in northern Thailand. *J Med Assoc Thai* 2012; 95 (Suppl 4): S8-17.
12. Sedghipour MR, Sorkhabi R, Shenasi A, Dehghan H. Outcome of penetrating keratoplasty in corneal ulcer: a single-center experience. *Clin Ophthalmol* 2011; 5: 1265-8.
13. Bourne WM. One-year observation of transplanted human corneal endothelium. *Ophthalmology* 1980; 87: 673-9.
14. Alldredge OC, Krachmer JH. Clinical types of corneal transplant rejection. Their manifestations, frequency, preoperative correlates, and treatment. *Arch Ophthalmol* 1981; 99: 599-604.
15. Wilson SE, Kaufman HE. Graft failure after penetrating keratoplasty. *Surv Ophthalmol* 1990; 34: 325-56.
16. Boujemaa C, Souissi K, Daghfous F, Marrakchi S, Jeddi A, Ayed S. [Urgent penetrating keratoplasty in perforated infectious corneal ulcers]. *J Fr Ophthalmol* 2005; 28: 267-72.

---

ผลการผ่าตัดเปลี่ยนกระจกตาแบบเร่งด่วนในแผลกระจกตาดำติดเชื้อ ณ โรงพยาบาลธรรมศาสตร์เฉลิมพระเกียรติ

วิมลวรรณ ตั้งปกาศิต, ฐนิชยา เหมยญญิณญวัฒน์

**วัตถุประสงค์:** เพื่อศึกษาการคงสภาวะโครงสร้างปกติของดวงตาภายหลังการผ่าตัดเปลี่ยนกระจกตาแบบเร่งด่วนในแผลกระจกตาดำติดเชื้อ ณ โรงพยาบาลธรรมศาสตร์เฉลิมพระเกียรติ

**วัสดุและวิธีการ:** ทำการศึกษาย้อนหลังจากเวชระเบียนของผู้ป่วยแผลกระจกตาดำติดเชื้อที่ขึ้นทะเบียนจอตาระบบเร่งด่วนและได้รับการผ่าตัดเปลี่ยนกระจกตา ตั้งแต่ เดือนกันยายน พ.ศ. 2548 ถึง มกราคม พ.ศ. 2558 ข้อมูลพื้นฐาน ปัจจัยเสี่ยง สาเหตุเชื้อก่อโรค ข้อบ่งชี้ในการผ่าตัด ระยะเวลาในการรอผ่าตัดนับจากวันที่ลงทะเบียนจอตาระบบเร่งด่วน และอัตราการคงสภาวะโครงสร้างปกติของดวงตาไว้ได้ ภายหลังการผ่าตัดได้ถูกนำมาวิเคราะห์

**ผลการศึกษา:** ผู้ป่วยทั้งหมดที่ลงทะเบียนจอตาระบบเร่งด่วน 55 ตา มีผู้ป่วย 22 ราย (22 ตา) ที่ได้รับการผ่าตัดเปลี่ยนกระจกตาแบบเร่งด่วน คิดเป็นชาย 14 ราย (ร้อยละ 63.6) หญิง 8 ราย (ร้อยละ 36.4) มีอายุเฉลี่ย  $55.9 \pm 15.4$  ปี ปัจจัยเสี่ยงที่พบบ่อยที่สุดคือ อุบัติเหตุทางตา 11 ตา (ร้อยละ 50.0) เชื้อก่อโรคที่พบบ่อยที่สุดคือ เชื้อรา 7 ตา (ร้อยละ 31.8) ข้อบ่งชี้ในการผ่าตัดที่พบบ่อยที่สุดคือ แผลกระจกตาดำติดเชื้อรุนแรงที่ไม่ตอบสนองต่อการรักษาด้วยยา 11 ตา (ร้อยละ 50.0) โดยมีระยะเวลาผ่าตัดเฉลี่ยนาน  $22.1 \pm 17.2$  วัน (3-70 วัน) สามารถรักษาโครงสร้างปกติของดวงตาไว้ได้ 18 ตา (ร้อยละ 81.8) และ 4 ตา (ร้อยละ 18.2) ที่ไม่สามารถเก็บรักษาสภาวะโครงสร้างปกติของดวงตาไว้ได้

มีผู้ป่วย 33 ราย (33 ตา) ที่ไม่ได้รับการผ่าตัดเปลี่ยนกระจกตาแบบเร่งด่วนโดยมี 20 ตา (ร้อยละ 81.8) ที่สามารถรักษาดวงตาโดยคงสภาวะโครงสร้างปกติของดวงตาไว้ได้ ในขณะที่ผู้ป่วย 13 ตา (ร้อยละ 33.4) ที่ไม่สามารถเก็บรักษาดวงตาไว้ได้เนื่องจากการแพร่กระจายแผลติดเชื้ออย่างรุนแรงเข้าในดวงตา

**สรุป:** การผ่าตัดเปลี่ยนกระจกตาแบบเร่งด่วนในแผลกระจกตาดำติดเชื้อได้ผลเป็นที่น่าพอใจและส่วนใหญ่สามารถรักษาสภาวะโครงสร้างปกติของดวงตาไว้ได้

---