

## Case Report

# The Treatment of Flexion Myelopathy of the Thoracic Spine in Pierre Robin Sequence: A Case Report

Sombat Kunakornsawat MD\*,  
Vera Sathira-Angkura MD\*, Thavat Prasarithra MD\*,  
Weera Sudprasert MD\*\*, Rachata Tungsiripat MD\*\*\*

\* Center of Excellence in Orthopedics, Lerdsin General Hospital, Bangkok, Thailand

\*\* Korat Orthopedic Excellent Center, Maharat Nakhon Ratchasima Hospital, Nakhon Ratchasima, Thailand

\*\*\* Department of Orthopedics, Ramkhamhaeng Hospital, Bangkok, Thailand

**Background:** A few studies had reported the spinal deformity associated with neurological symptoms in PRS patients.

**Objective:** To report the management of myelopathy from flexible thoracic kyphoscoliosis in Pierre Robin sequence (PRS) patient.

**Material and Method:** A 15-year-old PRS patient with thoracic kyphoscoliosis developed myelopathy symptom for 4 months. Posterior instrumentation (Cotrel-Dubousset) from T1-T9 was done to correct her deformity without decompression.

**Results:** Her motor power improved to grade 5/5 two months after operation. Her urological symptom returned to normal at 4-month postoperatively.

**Conclusion:** Myelopathy from flexible kyphotic deformity in PRS patients can be successfully treated by posterior correction and fusion without decompression.

**Keywords:** Pierre Robin sequence (PRS), Spinal deformity, Myelopathy

*J Med Assoc Thai* 2015; 98 (10): 1041-4

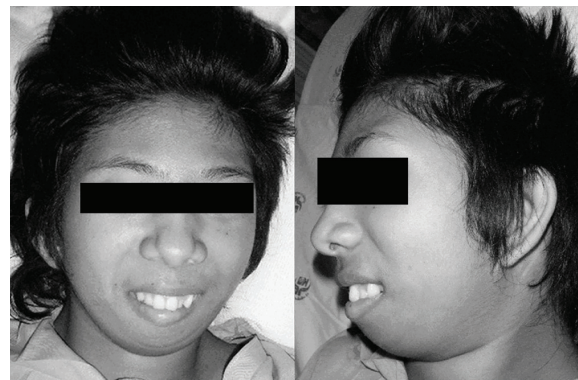Full text. e-Journal: <http://www.jmatonline.com>

### Case Report

Pierre Robin sequence (PRS) is a syndrome that associated with micrognathia, glossoptosis, and posterior U-shaped cleft palate<sup>(1)</sup>. Few spinal problems were reported in PRS patients<sup>(2-4)</sup>. Two reports were written, the first one was on an 8-year-old PRS patient with occipitoatlantoaxial instability and thoracolumbar scoliosis without neurological symptom<sup>(3)</sup>, while the second one was on a 2-year-old PRS girl who developed progressive congenital kyphosis at cervicothoracic level with severe spinal cord compression at C7/T1 level<sup>(4)</sup>. To the authors' knowledge, a few studies had reported the spinal deformity associated with neurological symptoms in PRS patients. The objective of the present study was to report the management of myelopathy in PRS patient who had flexible thoracic kyphoscoliosis.

A 15-year-old PRS female developed thoracic kyphotic deformity four years ago (Fig. 1). She developed progressive numbness of both lower limbs

for four months. She had difficulty walking and urinary incontinence. Her thoracic spine was kyphoscoliosis. Her joint laxity test<sup>(5)</sup> was negative. Neurological examination demonstrated motor strength graded 4/5 throughout her lower extremities. Slight sensory loss was found bilaterally on the whole trunk and lower extremities. The deep tendon reflexes were all hyperactive in both lower limbs with positive Babinski sign and ankle clonus. Her neurological symptoms improved after bed rest for one week.

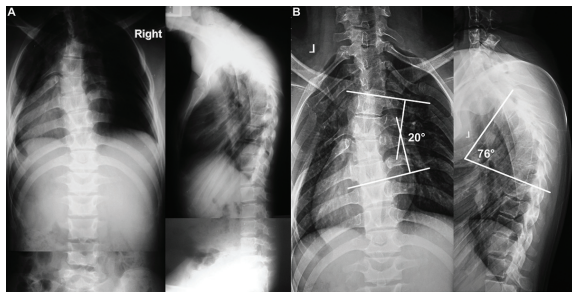


**Fig. 1** The appearance of micrognathia in Pierre Robin sequence.

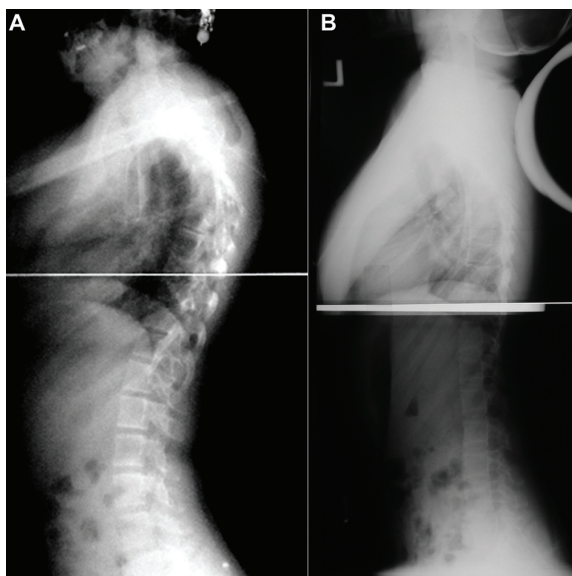
### Correspondence to:

Kunakornsawat S, Center of Excellence in Orthopedics, Lerdsin General Hospital, 190 Silom Road, Bangkok 10500, Thailand.  
Phone: +66-2-3539835, Fax: +66-2-3539836  
E-mail: [library.lerdsin@gmail.com](mailto:library.lerdsin@gmail.com), [batkunakornsawat@gmail.com](mailto:batkunakornsawat@gmail.com), [weespine@gmail.com](mailto:weespine@gmail.com)

The anteroposterior and lateral radiograph revealed a marked (76°) kyphosis of T4-T8, moderate (20°) left-sided scoliosis of T4-T9, and bone maturation Risser 4 (Fig. 2). The flexion and extension X-ray were taken to assess the flexibility of curve. Her kyphosis decreased 30° in extension X-ray (Fig. 3). Her cervical spine X-ray revealed the block vertebrae at C2-3 and C4-5, no occipitoatlantoaxial instability (Fig. 4). The 3-dimension CT scan demonstrated bony dysplasia and small pedicle diameter at the level of the deformity (Fig. 5). MRI demonstrated spinal cord tethering at the apex of kyphotic curve with intra-medullary hyperintensity signal on T2W at T5-T6 levels (Fig. 6).

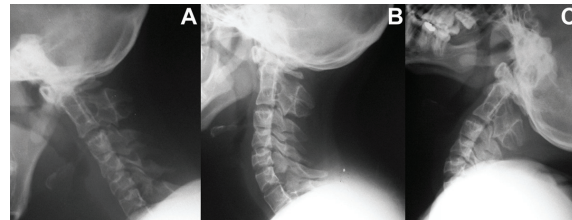


**Fig. 2** The anteroposterior whole spine radiograph demonstrates kyphoscoliosis of thoracic spine and bone maturation Risser 4 (A). The anteroposterior of thoracic spine revealed 20° left-sided scoliosis of T4-T9. The lateral radiograph revealed 76° kyphosis of T4-T8 (B).

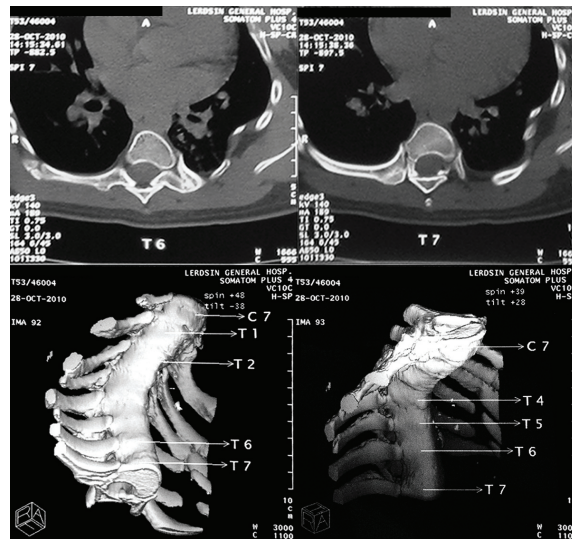


**Fig. 3** Preoperative lateral radiograph was taken before and after bending with fulcrum demonstrating 30° reduction of kyphosis.

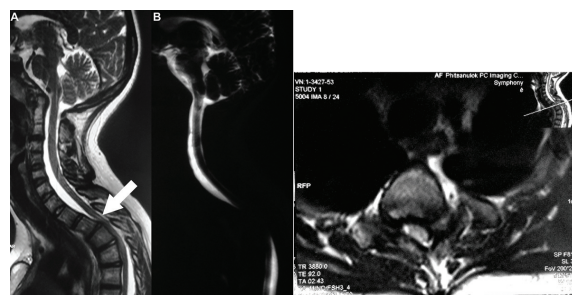
Posterior approach was done from T1-T9. Kyphotic deformity was corrected using hook rod system (Cotrel-Dubousset) without decompression.



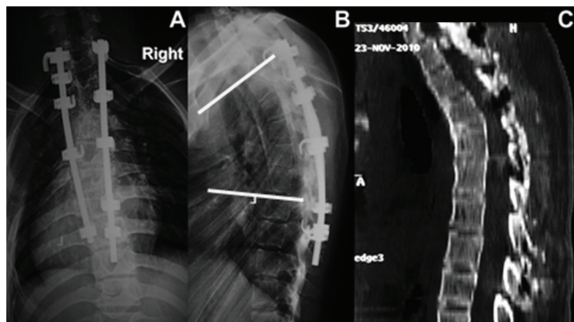
**Fig. 4** The lateral functional radiograph in flexion (A), neutral (B) and extension (C) reveals the symmetric block of the second and third and no atlantoaxial instability.



**Fig. 5** The 3-dimension computed tomography scan showed bony dysplasia and small pedicle diameter at the level of the deformities.



**Fig. 6** MRI sagittal-view T2W (A) and STIR (B) and Axial T2W demonstrated spinal cord tethering at the apex of kyphotic curve. Intra-medullary hyperintensity signal (arrow) was located at T5-T6 levels.



**Fig. 7** Correction was confirmed by postoperative anteroposterior (A), lateral (B) X-ray, and computed tomography scan (C) assessment. The lateral radiograph revealed 30° kyphosis of T4-T8.

Local bone graft mixed with bone substitutes were used to promote fusion. The operation lasted 180 minutes. The intraoperative blood loss was 600 ml. The patient tolerated the procedure well and experienced no complications. Kyphotic correction was 30 degrees and confirmed by intraoperative fluoroscopy, postoperative X-ray and CT scan (Fig. 7).

After surgery, the patient reported improvement in her gait and numbness. Her motor power was gradually improved to grade 5/5 at 2-month post-operation. Her urological symptom returned to normal at 4-month postoperatively. She was doing well and radiography showed solid fusion at 1-year follow-up.

## Discussion

Few studies reports spinal deformity associated with PRS. Molnar et al reported an 8-year-old PRS child with a congenital kyphoscoliosis, an atlanto-occipital subluxation, and Klippel-Feil syndrome without neurological symptoms<sup>(3)</sup>. Kaissi et al reported a 2-year-old PRS girl who developed severe spinal cord compression at C7-T1 from progressive congenital kyphosis at cervicothoracic level<sup>(4)</sup>. Our PRS patient was different from the previous two cases that she did not have congenital kyphoscoliosis.

Spinal cord compression from thoracic kyphoscoliosis deformity was reported<sup>(6-8)</sup>.

The treatment is decompression and deformity correction. Anterior decompression through right-side thoracotomy in 17-year-old boy with type 2 congenital kyphosis was performed<sup>(7)</sup>. Nine of 11 congenital kyphoscoliosis patients with spontaneous neurological deterioration had anterior decompression and fusion<sup>(6)</sup>.

However, the posterior correction, decompression, and fusion were performed with good clinical result in 84-year-old man with dynamic myelopathy<sup>(9)</sup>. The authors recommended posterior fusion in dynamic myelopathy. They also mentioned that decompression is not necessary in all cases<sup>(9)</sup>. Yamazaki et al propose that the major factors for thoracic myelopathy are kyphosis and instability<sup>(10)</sup>. The association between severity of kyphotic deformity and neurological symptoms was demonstrated. A 14-year-old Scheuerman's disease patients developed cord compression from flexible kyphotic deformity that resolved after the kyphotic deformity was corrected by plaster jacket<sup>(8)</sup>.

In the present patient, posterior correction and fusion was chosen because there was no spinal cord compression ventrally and the curve was flexible. Her symptom also improved after one week of resting in supine position. Hook-rod construction was selected instead of pedicular screws system due to the bony dysplasia and small pedicular diameter. Therefore, we did the posterior correction and fusion from T1-T9 using CD system without decompression. The operation successfully improved her neurological problems. In the PRS patients who develop myelopathy from kyphoscoliosis, static and dynamic X-ray, CT, and MRI are recommended to determine the treatment methods. If the curve was flexible and there was no compression from disc or vertebra ventral to spinal cord, posterior correction and fusion without decompression is a safe and effective treatment.

## What is already known on this topic?

Pierre Robin sequence (PRS) is a syndrome that associated with micrognathia, glossoptosis, and posterior U-shaped cleft palate. Some orthopedic related problems in PRS such as polydactyly, paraxial hemimelia, toe overlying, fusion of rib, and wide thoracic spinal canal are reported. There were only two cases of PRS reported occipitoatlantoaxial instability and thoracolumbar scoliosis without neurological symptoms.

## What this study adds?

To the authors' knowledge, this is the first report of dynamic thoracic kyphoscoliosis with spinal cord compression in PRS. We performed deformity correction by posterior fusion with instrumentation. The successful correction of kyphoscoliosis demonstrated significant spinal cord decompression. The patient's neurological sequelae gradually resolved to normal.

### Potential conflicts of interest

None.

### References

1. Randall P, Krogman WM, Jahins S. Pierre robin and the syndrome that bears his name. *Cleft Palate J* 1965; 36: 237-46.
2. Printzlau A, Andersen M. Pierre Robin sequence in Denmark: a retrospective population-based epidemiological study. *Cleft Palate Craniofac J* 2004; 41: 47-52.
3. Molnar S, Szappanos L, Kormendi Z, Veres R. Occipitoatlantoaxial instability and congenital thoracic vertebral deformity in Pierre Robin sequence: a case report. *Spine (Phila Pa 1976)* 2007; 32: E501-4.
4. Al Kaissi A, Ganger R, Klaushofer K, Grill F. Cervico-thoracic kyphosis in a girl with Pierre Robin sequence. *Ger Med Sci* 2011; 9: Doc06.
5. Wynne-Davies R. Acetabular dysplasia and familial joint laxity: two etiological factors in congenital dislocation of the hip. A review of 589 patients and their families. *J Bone Joint Surg Br* 1970; 52: 704-16.
6. McMaster MJ, Singh H. Natural history of congenital kyphosis and kyphoscoliosis. A study of one hundred and twelve patients. *J Bone Joint Surg Am* 1999; 81: 1367-83.
7. Khanna N, Molinari R, Lenke L. Exertional myelopathy in type 2 congenital kyphosis. *Spine (Phila Pa 1976)* 2002; 27: E488-92.
8. Sariali E, Panier S, Glorion C. Mechanical spinal cord compression at the apex of a kyphosis: a propos of one case. Review of the literature. *Eur Spine J* 2009; 18 (Suppl 2): 160-4.
9. Fujibayashi S, Neo M, Nakamura T. Flexion myelopathy of the thoracic spine. Case report. *J Neurosurg Spine* 2007; 6: 68-72.
10. Yamazaki M, Okawa A, Koda M, Goto S, Minami S, Moriya H. Transient paraparesis after laminectomy for thoracic myelopathy due to ossification of the posterior longitudinal ligament: a case report. *Spine (Phila Pa 1976)* 2005; 30: E343-6.

---

การรักษาการกดทับไขสันหลังบริเวณ กระดูกสันหลังระดับทรวงอกในผู้ป่วย โรค *Pierre Robin sequence*: รายงานผู้ป่วย 1 ราย

สมบัติ คุณากรสวัสดิ์, วีระ สติธอังกูร, ธวัช ประสาทฤทธา, วีระ สุดประเสริฐ, รัชตะ ตั้งศิริพัฒน์

ภูมิหลัง: การศึกษาเกี่ยวกับภาวะกระดูกสันหลังผิดรูปร่วมกับอาการทางระบบประสาทถูกกดทับในผู้ป่วยโรค *Pierre Robin sequence (PRS)* ยังคงมีไม่มากนัก

วัตถุประสงค์: เพื่อรายงานผลการรักษาอาการไขสันหลังถูกกดทับจากกระดูกสันหลังส่วนทรวงอกผิดรูปแบบ *flexible kyphoscoliosis* วัสดุและวิธีการ: รายงานผู้ป่วยเพศหญิงโรค *PRS* อายุ 15 ปี มาด้วยปัญหาไขสันหลังบริเวณระดับกระดูกทรวงอกถูกกดทับทำให้เกิดภาวะอ่อนแรงของขาทั้ง 2 ข้าง เป็นเวลา 4 เดือน จากการที่กระดูกสันหลังส่วนทรวงอกคดและโก่งงอ ได้รับการรักษาแก้ไขภาวะกระดูกสันหลังที่คดและโก่งงอให้ดีขึ้น โดยผ่าตัดเข้าทางด้านหลังใช้ตะขอ (*Cotrel-Dubousset*) ยึดตรึงและเชื่อมกระดูกสันหลังส่วนทรวงอกข้อที่ 1 ถึง 9 โดยไม่ใช้การตัดกระดูกเพื่อเปิดช่องไขสันหลัง

ผลการศึกษา: อาการอ่อนแรงกลับมาเป็นปกติ grade 5/5 ภายใน 2 เดือน ภายหลังจากผ่าตัด และระบบปัสสาวะกลับมาเป็นปกติ ภายหลังจากผ่าตัด 4 เดือน

สรุป: ภาวะไขสันหลังบริเวณระดับกระดูกทรวงอกถูกกดทับแบบ *flexible kyphosis* ในผู้ป่วยโรค *PRS* สามารถรักษาได้ผลดี โดยแก้ไขภาวะกระดูกสันหลังที่คดและโก่งงอด้วยวิธีการผ่าตัดเข้าทางด้านหลังเพื่อเชื่อมกระดูกสันหลังโดยไม่ต้องตัดกระดูกเพื่อเปิดช่องไขสันหลัง