

¹⁸F-FDG PET/Contrast-Enhanced CT for Initial Staging and Strategic Treatment of Non-Small Cell Lung Cancer: A Prospective Study

Chetsadaporn Promteangtrong MD*,
Anchisa Kunawudhi MD*, Rossarin Phadungrerk RN*,
Chanidapa Iamsa-art RT*, Chanisa Chotipanich MD*

* National Cyclotron and PET Centre, Chulabhorn Hospital, Bangkok, Thailand

Background: Selection of the best treatment option for non-small cell lung cancer (NSCLC) depends on optimal initial staging.

Objective: Evaluate the clinical impact of ¹⁸F-FDG PET/CT on the management of Thai patients with NSCLC.

Material and Method: Twenty-four patients with NSCLC underwent FDG PET/CT for initial staging. The best treatment options between pre- and post-FDG PET/CT staging were identified for each patient. Changes in treatment management decisions and the diagnostic values (sensitivity, specificity, positive predictive value, negative predictive value, and accuracy) of nodal and distant metastases were assessed.

Results: Pre-FDG PET/CT staging included five patients with stage IA, four patients with stage IB, one patient with stage IIB, three patients with stage IIIA, and 11 patients with stage IV disease. A difference between pre- and post-FDG PET/CT staging was noted in 10/24 patients (41.7%). FDG PET/CT examination resulted in upstaging in 7/24 patients (29%) and downstaging in three patients (12.5%). The pre-FDG PET/CT staging was accurate in 14/24 patients (58.3%) while the post-FDG PET/CT staging was accurate in 19/24 patients (79.2%). The treatment management decisions were changed in 5/24 patients (20.8%). FDG PET/CT prevented futile surgery in two patients.

Conclusion: FDG PET/CT has an important role in NSCLC staging. Additional PET/CT information could influence therapeutic options and reduced unnecessary surgery in patients with metastatic disease.

Keywords: Lung cancer, Non-small cell, FDG, PET/CT, Staging

J Med Assoc Thai 2015; 98 (10): 1010-8

Full text. e-Journal: <http://www.jmatonline.com>

Contrast-enhanced chest CT is a standard modality for the staging of non-small cell lung cancer (NSCLC). However, it still has limited reliability regarding mediastinal metastasis with a sensitivity and specificity in detecting node metastasis of 52% and 69%, respectively^(1,2).

According to the National Comprehensive Cancer Network, 2-deoxy-2-[¹⁸F]fluoro-D-glucose positron emission tomography combined with computed tomography (FDG PET/CT) is currently one of imaging recommended for NSCLC staging. It is superior to conventional imaging because of its capability of providing metabolic and anatomical information simultaneously. A meta-analysis has shown that FDG PET has a superior sensitivity and

specificity for metastatic node detection of 85% and 90%, respectively when compared with 61% and 79%, respectively using contrast-enhanced CT⁽²⁾. For integrated FDG PET/CT, a meta-analysis by Lv et al⁽³⁾ achieved pool weight FDG PET/CT sensitivity and specificity of 73% and 92%, respectively with precise diagnostic values in detecting the systemic involvement of either osseous or extra-osseous metastases⁽⁴⁾; thus, the number of tests and invasive procedures required in the evaluation of patients with NSCLC has been reduced. However, FDG PET/CT has some limitations in nodal staging. Additionally in Thailand, clinical impact of FDG PET/CT for NSCLC has not been studied.

The primary aim of the present study was to investigate the impact of FDG PET/CT in newly diagnosed NSCLC patients regarding changes in the initial treatment planning suggested by conventional staging methods. The secondary aim was evaluation of the diagnostic accuracy of FDG PET/CT in the detection of mediastinal nodes and distant metastasis.

Correspondence to:

Promteangtrong C, National Cyclotron and PET Centre, Chulabhorn Hospital, 54 Kamphang Phet 6 Road, Laksi, Bangkok 10210, Thailand.

Phone: +66-2-5766060, Fax: +66-2-5744724

E-mail: jadesadaporn018@gmail.com

Material and Method

Patients

The prospective study was approved by the Chulabhorn Institutional Review Board, and written informed consents were obtained from all of the patients. Patients with histopathological specimen-proved NSCLC were enrolled. All patients underwent FDG PET/CT for initial staging at the National Cyclotron and PET Centre, Chulabhorn Hospital between July 2013 and February 2014. Exclusion criteria were diabetes mellitus, pregnancy, and breast feeding. Diagnosis of the primary tumor was histopathologically proven in all patients; the diagnosis of lymph node involvement and distant metastasis was based on histopathology and/or contrast-enhanced CT imaging.

FDG PET/CT imaging procedures

Patients fasted for six hours before undergoing FDG PET/CT using a Siemens/Biograph 16 scanner in 3D mode. Plasma glucose level was determined and imaging was performed 90 minutes after intravenous injection of 5 MBq/kg FDG. Contrast-enhanced CT was undertaken following the administration of intravenous contrast media. Image acquisition was performed from the skull base to the proximal thigh as follows, three minutes per bed position, four iterations and eight subsets, a matrix size of 168, zoom = 1, and a Gaussian filter with full width at half maximum = 5.0.

Data analysis

PET/CT results were analyzed by two independent experienced nuclear medicine physicians blinded to the clinical and imaging information obtained from contrast-enhanced chest CT, conventional imaging, and histopathological analysis at the time of review. The visual analyses regarding areas of non-physiologically increased uptake were defined as malignant lesions by consensus.

Determination of disease stage and treatment

Staging was performed according to the seventh edition of the American Joint Committee on Cancer staging system⁽⁵⁾. Each patient was assigned to pre-FDG PET/CT staging based on conventional staging information including clinical data, physical examination, histopathology, contrast-enhanced CT, brain MRI and bone scans. After FDG PET/CT, post-FDG PET/CT staging was performed in all patients. The pre- and post-FDG PET/CT staging was

undertaken within one week of each other. The difference between pre- and post-FDG PET/CT staging, including distinctive treatment options such as curative surgery, concurrent chemoradiotherapy, neoadjuvant therapy, and palliation were identified in all patients.

Reference standard

Histopathological diagnosis was used as the reference standard. Because the histological confirmation of all metastatic lesions was not technically feasible, lesions showing focally increased tracer uptake beyond the physiological range together with a corresponding CT abnormality were also defined as true positive sites of malignancy. In case of PET positive but CT negative or PET negative but CT positive, we carried out clinical, radiological, and analytical follow-up for one year. We considered that there was benign lesion when there was clinical and radiological stability in the follow-up after one year.

Statistical analysis

The sensitivity, specificity, positive predictive value (PPV), negative predictive value (NPV), and accuracy of FDG PET/CT in the assessment of nodal metastasis and distant metastases were calculated. A *p*-value of ≤ 0.05 was considered as being statistically significant.

Results

Twenty-four patients were included. Patient characteristics were shown in Table 1. The details of pre- and post-FDG PET/CT staging for each patient were summarized in Table 2.

Initial staging

The number of patients in pre- and post-FDG PET/CT staging were shown in Table 3. The post-FDG PET/CT staging differed from the pre-FDG PET/CT staging in 10 patients (41.7%), seven patients (29%) were upstaged, and three (12.5%) were downstaged. The pre-FDG PET/CT staging was correct in 14 patients (58.3%) while post-FDG PET/CT staging was correct in 19 patients (79.2%; *p*-value = 0.125). Of 10 patients with discordant pre- and post-FDG PET/CT staging, FDG PET/CT accurately upstaged six patients (60%) and downstaged one patient (10%). Incorrect FDG PET/CT upstaging and downstaging was observed in one (1%) and two (2%) patients, respectively. Fig. 1 and 2 were examples of accurate upstaged and downstaged FDG PET/CT, respectively.

Table 1. Patient characteristics

Patient characteristics	Number (%)
Sex	
Male	11 (45.8)
Female	13 (54.2)
Age (years)	
Mean	61.4
Range	44-74
Histology	
Adenocarcinoma	21 (87.5)
Squamous cell carcinoma	2 (8.3)
Bronchioloalveolar carcinoma	1 (4.2)
Pre-FDG PET/CT staging	
IA	5 (20.8)
IB	4 (16.7)
IIA	0 (0)
IIB	1 (4.2)
IIIA	3 (12.5)
IIIB	0 (0)
IV	11 (45.8)

FDG PET/CT = fluoro-D-glucose positron emission tomography/computed tomography

Detection of nodal metastasis

Pre-FDG PET/CT staging with contrast-enhanced CT revealed 16 patients with N0, four with N2, and four with N3 stages. Pathology was confirmed in seven patients. The sensitivity, specificity, PPV, NPV, and accuracy of FDG PET/CT were 33.3%, 75%, 50%, 60%, and 57.1%, respectively, on a per-patient basis. The contrast-enhanced CT showed sensitivity, specificity, PPV, NPV, and accuracy were 0%, 75%, 0%, 50%, and 42.9%, respectively, on a per-patient basis. There was no significant difference in detecting nodal metastasis between FDG PET/CT and contrast-enhanced CT (p -value = 1.00). The post-FDG PET/CT staging changed the N stage in nine patients (37.5%), with eight upstaged and one downstaged. The patient who was downstaged by FDG PET/CT was confirmed by histopathology.

Identification of metastasis

The pre-FDG PET/CT staging showed metastasis (M1) in 11 patients, while the post-FDG PET/CT showed M1 in 14 patients. Of the 24 patients, the metastatic sites included five intrapulmonary, five pleural, three brain, six bone, two adrenal gland, two muscle, and one liver. The pre-FDG PET/CT staging achieved 66.7% sensitivity, 88.9% specificity, 90.9% PPV, 61.5% NPV, and 75% accuracy, in detecting metastatic disease on a per-patient basis. In contrast,

Table 2. Details of pre- and post-FDG PET/CT staging

Patients	Pre-FDG PET/CT staging	Post-FDG PET/CT staging	Remarks
1	IA	IA	
2	IV	IV	
3	IV	IV	
4	IV	IV	
5	IB	IV	PET/CT: M1b (bone)
6	IB	IB	
7	IB	IB	
8	IA	IIIA	CT: N0; PET/CT: N2
9	IA	IV	PET/CT: M1b (bone)
10	IV	IV	
11	IA	IA	
12	IV	IV	
13	IV	IV	
14	IA	IB	CT: T1b; PET/CT: T2a
15	IV	0	PET/CT: false negative
16	IV	IV	
17	IIIA	IV	CT: N2M0; PET/CT: N3M1a
18	IB	IB	
19	IV	IV	
20	IIB	IV	PET/CT: M1b (brain, bone, muscle)
21	IV	IIIA	CT: M1a; PET/CT: M0
22	IV	IV	
23	IIIA	0	PET/CT: false negative in BAC
24	IIIA	IV	PET/CT: M1b (liver, bone, muscle)

BAC = bronchioloalveolar carcinoma

the post-FDG PET/CT staging showed superior efficacy with 93.3% sensitivity, 100% specificity, 100% PPV, 90% NPV, and 95.8% accuracy, on a per-patient basis. There was no significant difference in detecting distant metastasis between FDG PET/CT and conventional imaging (p -value = 0.125). In three patients with M1 in the pre-FDG PET/CT staging, FDG PET/CT additionally revealed one bone metastasis and two adrenal metastases. The pre-FDG PET/CT staging suspected the presence of M1a (single intrapulmonary metastasis) in one patient, whereas the post-FDG PET/CT staging classified

Table 3. Number of patients involved in pre- and post-FDG PET/CT staging of NSCLC

Pre-PET/CT stage	Post-PET/CT stage									Downstaged (%)	Upstaged (%)
	0	IA	IB	IIA	IIB	IIIA	IIIB	IV	Total		
IA	0	2	1	0	0	1	0	1	5	0 (0)	3 (60)
IB	0	0	3	0	0	0	0	1	4	0 (0)	1 (25)
IIA	0	0	0	0	0	0	0	0	0	0 (0)	0 (0)
IIB	0	0	0	0	0	0	0	1	1	0 (0)	1 (100)
IIIA	1	0	0	0	0	0	0	2	3	1 (33)	2 (67)
IIIB	0	0	0	0	0	0	0	0	0	0 (0)	0 (0)
IV	1	0	0	0	0	1	0	9	11	2 (18)	0 (0)
Total	2	2	4	0	0	2	0	14	24	3 (13)	7 (29)

NSCLC = non-small cell lung cancer

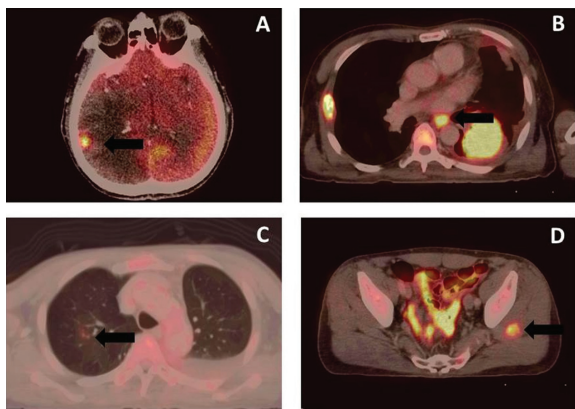


Fig. 1 Upstaged FDG PET/CT. A 61-year-old man with metastatic NSCLC. A-D: FDG PET/CT showed unexpected brain, mediastinal node, intrapulmonary and gluteus muscle metastases.

it as M0. Pathologic findings were negative for malignancy.

Impact of post-PET/CT stage on treatment

The patients who underwent changed treatment planning were listed in Table 4. FDG PET/CT resulted in the delivery of a changed treatment protocol in five patients (20.8%). The goal of treatment was changed from curative to palliative intent in four patients (16.7%), two from curative surgery and two from concurrent chemoradiotherapy. Treatment of one patient (4%) who was downstaged with FDG PET/CT was changed from receiving palliative treatment to receiving concurrent chemoradiotherapy and curative surgery. One of the 24 patients had incidental finding of increased FDG uptake in the ascending colon, which was biopsy-confirmed as low-grade tubular adenoma.

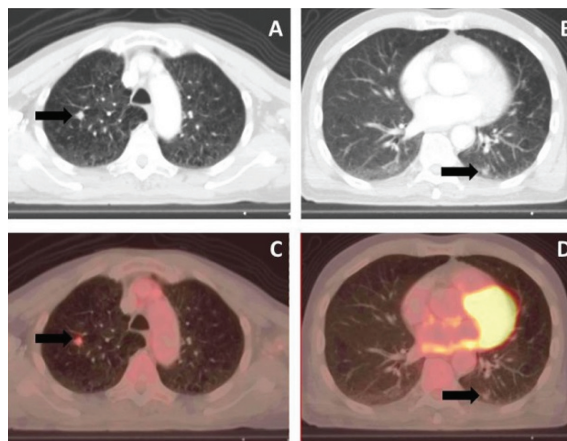


Fig. 2 Downstaged FDG PET/CT. A 71-year-old man with NSCLC. A, B: CT suggested primary cancer at RUL and intrapulmonary metastasis at LLL. Pre-FDG PET/CT M staging was M1a. C, D: FDG PET/CT showed only hypermetabolic nodule at RUL. Post-FDG PET/CT M staging was M0. Histopathologic confirmation of nodule at LLL was negative for malignancy.

Discussion

The present study found that FDG PET/CT staging was superior to conventional staging; post-FDG PET/CT staging was correct in 79.2% of patients, whereas pre-FDG PET/CT staging was correct in 58.3% of patients. Using FDG PET/CT, 29% of patients were upstaged, and 12.5% downstaged, similar to the findings of Hicks et al⁽⁶⁾, where 33% of patients were upstaged and 10% downstaged. Using post-FDG PET/CT staging, we found that 60% of patients were correctly upstaged and 10% were correctly downstaged, in the case of patients where the pre- and post-FDG PET/CT staging were not identical. Our data showed

Table 4. Details of changed treatment planning after post-FDG PET/CT staging

Patient	Intended treatment	Treatment after post-FDG PET/CT staging	Discordant image findings	Remarks
1	Surgery	Chemotherapy	CT: No bony metastasis PET/CT: T5 and right femur metastases	
2	Surgery and adjuvant chemotherapy	Chemotherapy	CT: N2 stage and no intrapulmonary metastasis PET/CT: N3 stage with intrapulmonary metastasis	
3	CCRT and surgery	Chemotherapy	CT: No mediastinal or distant metastasis PET/CT: Mediastinal and intrapulmonary metastases Multiple brain metastases Bone metastases at right scapula and right 5 th rib Metastasis at left gluteus muscle	
4	Chemotherapy	CCRT and surgery	CT: N0 stage with intrapulmonary metastasis at LLL PET/CT: N2 stage and no intrapulmonary metastasis	Metastasis in LN group 4, negative malignancy at LLL nodule
5	CCRT	Chemotherapy	CT: N2 stage without distant metastasis PET/CT: N3 stage with liver, paravertebral muscle metastases and multiple bony metastases	

CCRT = concurrent chemoradiation; LLL = left lower lung; LN = lymph node

a larger percentage of correctly upstaged results than the randomized trial of Maziak et al⁽⁷⁾, where 13.8% of patients were correctly upstaged. This could be explained by the considerable difference in the number of subjects involved in the two studies. The accuracy of the initial staging involving the NSCLC guidelines offers clinicians the optimal treatment strategy and treatment results. We were able to avoid futile surgery in two patients and to change the therapeutic intent from curative to palliation in four patients.

A number of studies have shown a variety of diagnostic accuracy of FDG PET or FDG PET/CT in detecting the N stage⁽⁸⁻¹⁴⁾; Lv et al reported a 73% sensitivity and 92% specificity in a recent meta-analysis⁽³⁾. The high NPV of FDG PET and FDG PET/CT^(10,11,15,16) allows the omission of invasive procedures such as mediastinoscopy with biopsy in patients whose PET scan was negative for mediastinal nodal metastasis. In the present study, we found false positive lymph node metastasis in one patient with a 1.1 cm diameter right paratracheal node, and a 0.9 cm right hilar node. False positive results were likely to be obtained for the enlarged nodes^(17,18). In a meta-analysis by Gould et al⁽²⁾, FDG PET showed higher sensitivity but lower specificity, when CT had detected enlarged lymph nodes (median sensitivity 100% and median specificity 78%) than when CT had detected no lymph node enlargement (median sensitivity 82% and median specificity 93%). If the PET/CT scan was positive in the mediastinum, then pathological confirmation was needed for lymph node status⁽¹⁹⁾. According to our data, two patients whose post-FDG PET/CT staging was N0, had pathologic confirmation of nodal metastasis; one patient had a peribronchial node and the other had a lymph node located at American Thoracic Society nodal map (ATS) station 5. Some studies have reported false negative results for N1 disease because of masking by the primary tumor⁽²⁰⁾ and N2 at ATS stations 5, 6, and 7⁽¹⁷⁾. Despite only seven patients with pathological confirmation of nodal status, our data showed that the FDG PET/CT provided more sensitivity, PPV, NPV, and accuracy than the contrast-enhanced CT in detecting mediastinal lymph node metastasis.

Besides the N3 stage, distant metastasis also precludes curative surgery. FDG PET/CT has been beneficial in this regard as a result of whole body imaging data. Previous studies by Reed et al⁽¹⁵⁾ and Pieterman et al⁽⁸⁾ have reported unrecognized distant metastasis in 6.3% and 11%, respectively of patients determined to have resectable disease using

conventional staging. In the present study, five of 13 patients patients (38.5%) were found to have distant metastasis using FDG PET/CT. The sensitivity, specificity, PPV, NPV, and accuracy in detecting distant metastasis using FDG PET/CT in present study were superior to the conventional approaches (93.3%, 100%, 100%, 90%, and 95.8% vs. 66.7%, 88.9%, 90.9%, 61.5%, and 75%, respectively).

In present study, FDG PET/CT diagnosed multiple bone metastases in one patient whose bone scan was only indicative of trauma in the left ninth rib. Some studies have claimed that the diagnostic accuracy of FDG PET or PET/CT is superior to bone scintigraphy⁽²¹⁻²³⁾. Kruger et al⁽²³⁾ reported that FDG PET/CT was more effective than ^{99m}Tc-methylene diphosphonate bone scintigraphy in the detection of osteolytic bone metastasis in NSCLC patients. The bone lesions in NSCLC are often lytic; thus, they are more easily detectable using FDG PET/CT rather than a bone scan, which is more sensitive to osteoblastic lesions. A meta-analysis by Qu et al⁽²⁴⁾ indicated that both FDG PET/CT and FDG PET were better imaging modalities for detecting bone metastasis from lung cancer than MRI and bone scintigraphy. The pool sensitivity and specificity of FDG PET/CT was 92% and 98%, respectively.

Lu et al⁽²⁵⁾ evaluated the usefulness of FDG PET/CT in differentiating benign from metastatic malignant adrenal masses (size range, 0.5 to 6.3 cm; mean size, 1.9 cm) in patients with lung cancer. The degree of FDG uptake compared to liver uptake could be used to differentiate an adrenal mass, and FDG PET/CT achieved 97% sensitivity, 94% specificity, and 95% accuracy in this regard. However, false-positive lesions for malignancy were encountered using FDG PET/CT in approximately 3-13% of adrenal lesions, including adrenal adenomas, pheochromocytomas, adrenal endothelial cysts, inflammation, and infection⁽²⁶⁾. In the present study, FDG PET/CT showed adrenal metastases in two patients. However, adrenal lesions were not validated by further investigation as a definite diagnosis of adrenal metastasis does not change patient care.

Even though FDG PET/CT could identify brain metastases in the present study, it has a limited role in the detection of brain metastasis because of high background FDG uptake in the normal brain parenchyma. As compared with brain CT or MRI, FDG PET provided no additional information regarding the presence of brain metastasis⁽²⁷⁾. FDG has also been shown to have variable uptake in metastatic brain

lesions because one-third of brain metastases from lung cancer exhibit hypometabolism⁽²⁸⁾. Dedicated brain MRI is a standard modality for the detection of brain metastatic lesions.

Muscle metastasis in NSCLC is quite rare; however, it does occur. We found two cases with muscle metastasis, one in the left gluteus and the other in the psoas muscle. Some previous studies have reported NSCLC metastasis to the psoas and thigh muscle^(29,30). There was one patient with liver metastasis in the present study. Rates of unsuspected liver metastases were 3 to 6% in patients with lung cancer and normal hepatic function. FDG PET is reported to detect liver metastases in $\leq 2\%$ of patients free of liver metastases based on conventional imaging⁽³¹⁾.

The current study was limited by the small number of recruited patients. Although there were no statistically significant differences between the pre- and post-FDG PET/CT staging regarding the detection of nodal and distant metastases, FDG PET/CT had clinical impact concerning strategic treatment and reduced the number of futile operations in patients with NSCLC.

Conclusion

In conclusion, our data showed the superiority of FDG PET/CT in the initial staging of patients with NSCLC when compared with conventional imaging. Additional FDG PET/CT information influenced the therapeutic options and reduced unnecessary surgery in patients with metastatic disease.

What is already known on this topic?

Accurate staging is critical in deciding the treatment options in patients NSCLC. Contrast-enhanced chest CT is the standard modality for NSCLC staging but has limited reliability regarding the detection of mediastinal metastasis. FDG PET/CT is currently one of the imaging modalities recommended for NSCLC staging. It is superior to conventional imaging because it can provide metabolic and anatomical information simultaneously. In addition, it has been reported that accurate staging using FDG PET/CT can reduce the rate of unnecessary surgeries. However, use of FDG PET/CT in Thailand is still limited because it is relatively expensive modality and not widely available.

What this study adds?

This is the first study evaluating clinical impact of FDG PET/CT for NSCLC in Thailand. The present study added information of diagnostic accuracy

and role of FDG PET/CT in strategic treatment for Thai patients with NSCLC.

Acknowledgements

The present study was supported by the Chulabhorn Hospital Research Fund. The authors acknowledge the kind help of Wantana Juiklom for routine PET/CT imaging and Sunattee Kessung for English grammar editing. Additionally, we thank the Data Management Unit, Chulabhorn Hospital for statistical analysis.

Potential conflicts of interest

None.

References

1. Webb WR, Gatsonis C, Zerhouni EA, Heelan RT, Glazer GM, Francis IR, et al. CT and MR imaging in staging non-small cell bronchogenic carcinoma: report of the Radiologic Diagnostic Oncology Group. *Radiology* 1991; 178: 705-13.
2. Gould MK, Kuschner WG, Rydzak CE, Maclean CC, Demas AN, Shigemitsu H, et al. Test performance of positron emission tomography and computed tomography for mediastinal staging in patients with non-small-cell lung cancer: a meta-analysis. *Ann Intern Med* 2003; 139: 879-92.
3. Lv YL, Yuan DM, Wang K, Miao XH, Qian Q, Wei SZ, et al. Diagnostic performance of integrated positron emission tomography/computed tomography for mediastinal lymph node staging in non-small cell lung cancer: a bivariate systematic review and meta-analysis. *J Thorac Oncol* 2011; 6: 1350-8.
4. Cuaron J, Dunphy M, Rimner A. Role of FDG-PET scans in staging, response assessment, and follow-up care for non-small cell lung cancer. *Front Oncol* 2012; 2: 208.
5. Detterbeck FC, Boffa DJ, Tanoue LT. The new lung cancer staging system. *Chest* 2009; 136: 260-71.
6. Hicks RJ, Kalff V, MacManus MP, Ware RE, Hogg A, McKenzie AF, et al. (18)F-FDG PET provides high-impact and powerful prognostic stratification in staging newly diagnosed non-small cell lung cancer. *J Nucl Med* 2001; 42: 1596-604.
7. Maziak DE, Darling GE, Inculet RI, Gulenchyn KY, Driedger AA, Ung YC, et al. Positron emission tomography in staging early lung cancer: a randomized trial. *Ann Intern Med* 2009; 151: 221-48.
8. Pieterman RM, van Putten JW, Meuzelaar JJ, Mooyaart EL, Vaalburg W, Koeter GH, et al. Preoperative staging of non-small-cell lung cancer with positron-emission tomography. *N Engl J Med* 2000; 343: 254-61.
9. Guhlmann A, Storck M, Kotzerke J, Moog F, Sunder-Plassmann L, Reske SN. Lymph node staging in non-small cell lung cancer: evaluation by [18F]FDG positron emission tomography (PET). *Thorax* 1997; 52: 438-41.
10. Poncelet AJ, Lonneux M, Coche E, Weynand B, Noirhomme P. PET-FDG scan enhances but does not replace preoperative surgical staging in non-small cell lung carcinoma. *Eur J Cardiothorac Surg* 2001; 20: 468-74.
11. Gupta NC, Graeber GM, Rogers JS, Bishop HA. Comparative efficacy of positron emission tomography with FDG and computed tomographic scanning in preoperative staging of non-small cell lung cancer. *Ann Surg* 1999; 229: 286-91.
12. Kubota K, Murakami K, Inoue T, Itoh H, Saga T, Shiomi S, et al. Additional value of FDG-PET to contrast enhanced-computed tomography (CT) for the diagnosis of mediastinal lymph node metastasis in non-small cell lung cancer: a Japanese multicenter clinical study. *Ann Nucl Med* 2011; 25: 777-86.
13. Yang W, Fu Z, Yu J, Yuan S, Zhang B, Li D, et al. Value of PET/CT versus enhanced CT for locoregional lymph nodes in non-small cell lung cancer. *Lung Cancer* 2008; 61: 35-43.
14. Scott WJ, Gobar LS, Terry JD, Dewan NA, Sunderland JJ. Mediastinal lymph node staging of non-small-cell lung cancer: a prospective comparison of computed tomography and positron emission tomography. *J Thorac Cardiovasc Surg* 1996; 111: 642-8.
15. Reed CE, Harpole DH, Posther KE, Woolson SL, Downey RJ, Meyers BF, et al. Results of the American College of Surgeons Oncology Group Z0050 trial: the utility of positron emission tomography in staging potentially operable non-small cell lung cancer. *J Thorac Cardiovasc Surg* 2003; 126: 1943-51.
16. Billé A, Pelosi E, Skanjeti A, Arena V, Errico L, Borasio P, et al. Preoperative intrathoracic lymph node staging in patients with non-small-cell lung cancer: accuracy of integrated positron emission tomography and computed tomography. *Eur J Cardiothorac Surg* 2009; 36: 440-5.
17. Al Sarraf N, Gately K, Lucey J, Wilson L,

- McGovern E, Young V. Lymph node staging by means of positron emission tomography is less accurate in non-small cell lung cancer patients with enlarged lymph nodes: analysis of 1,145 lymph nodes. *Lung Cancer* 2008; 60: 62-8.
18. Shiraki N, Hara M, Ogino H, Shibamoto Y, Iida A, Tamaki T, et al. False-positive and true-negative hilar and mediastinal lymph nodes on FDG-PET--radiological-pathological correlation. *Ann Nucl Med* 2004; 18: 23-8.
 19. Ettinger DS, Akerley W, Borghaei H, Chang AC, Cheney RT, Chirieac LR, et al. Non-small cell lung cancer, version 2.2013. *J Natl Compr Canc Netw* 2013; 11: 645-53.
 20. Halter G, Buck AK, Schirrmeister H, Aksoy E, Liewald F, Glatting G, et al. Lymph node staging in lung cancer using [18F]FDG-PET. *Thorac Cardiovasc Surg* 2004; 52: 96-101.
 21. Bury T, Barreto A, Daenen F, Barthelemy N, Ghaye B, Rigo P. Fluorine-18 deoxyglucose positron emission tomography for the detection of bone metastases in patients with non-small cell lung cancer. *Eur J Nucl Med* 1998; 25: 1244-7.
 22. Liu N, Ma L, Zhou W, Pang Q, Hu M, Shi F, et al. Bone metastasis in patients with non-small cell lung cancer: the diagnostic role of F-18 FDG PET/CT. *Eur J Radiol* 2010; 74: 231-5.
 23. Krüger S, Buck AK, Mottaghy FM, Hasenkamp E, Pauls S, Schumann C, et al. Detection of bone metastases in patients with lung cancer: 99mTc-MDP planar bone scintigraphy, 18F-fluoride PET or 18F-FDG PET/CT. *Eur J Nucl Med Mol Imaging* 2009; 36: 1807-12.
 24. Qu X, Huang X, Yan W, Wu L, Dai K. A meta-analysis of (1)(8)FDG-PET-CT, (1)(8)FDG-PET, MRI and bone scintigraphy for diagnosis of bone metastases in patients with lung cancer. *Eur J Radiol* 2012; 81: 1007-15.
 25. Lu Y, Xie D, Huang W, Gong H, Yu J. 18F-FDG PET/CT in the evaluation of adrenal masses in lung cancer patients. *Neoplasma* 2010; 57: 129-34.
 26. Sahdev A, Willatt J, Francis IR, Reznick RH. The indeterminate adrenal lesion. *Cancer Imaging* 2010; 10: 102-13.
 27. Posther KE, McCall LM, Harpole DH Jr, Reed CE, Putnam JB Jr, Rusch VW, et al. Yield of brain 18F-FDG PET in evaluating patients with potentially operable non-small cell lung cancer. *J Nucl Med* 2006; 47: 1607-11.
 28. Lee HY, Chung JK, Jeong JM, Lee DS, Kim DG, Jung HW, et al. Comparison of FDG-PET findings of brain metastasis from non-small-cell lung cancer and small-cell lung cancer. *Ann Nucl Med* 2008; 22: 281-6.
 29. Strauss JB, Shah AP, Chen SS, Giolda BT, Kim AW. Psoas muscle metastases in non-small cell lung cancer. *J Thorac Dis* 2012; 4: 83-7.
 30. Giugliano FM, Alberti D, Guida G, Palma GD, Iadanza L, Mormile M, et al. Non small-cell lung cancer with metastasis to thigh muscle and mandible: two case reports. *J Med Case Rep* 2013; 7: 98.
 31. Behzadi A, Ung Y, Lowe V, Deschamps C. The role of positron emission tomography in the management of non-small cell lung cancer. *Can J Surg* 2009; 52: 235-42.

¹⁸F-FDG PET/contrast-enhanced CT ในการกำหนดระยะและวางแผนการรักษาโรคมะเร็งปอดชนิด non-small cell: การศึกษาแบบไปข้างหน้า

เจษฎาพร พร้อมเที่ยงตรง, อัญชิสา คุณาวุฒิ, รสรินทร์ ผดุงฤกษ์, ชนิตาภา เอี่ยมสอาด, ชนิตา โชติพานิช

ภูมิหลัง: การกำหนดระยะของโรคที่ถูกต้องแม่นยำมีผลต่อการเลือกวิธีการรักษาที่เหมาะสมให้กับผู้ป่วยมะเร็งปอดชนิด non-small cell

วัตถุประสงค์: เพื่อศึกษาผลทางคลินิกของ FDG PET/CT ในการดูแลรักษาผู้ป่วยมะเร็งปอดชนิด non-small cell ชาวไทย
วัสดุและวิธีการ: ผู้ป่วยมะเร็งปอดชนิด non-small cell จำนวน 24 ราย ได้รับการตรวจ FDG PET/CT เพื่อกำหนดระยะของโรคก่อนเริ่มการรักษา ข้อมูลทางคลินิกทั้งหมดก่อนและหลังตรวจ FDG PET/CT จะนำมากำหนดระยะของโรคและแผนการรักษา เปรียบเทียบระยะของโรคและแผนการรักษาระหว่างก่อนและหลังตรวจ FDG PET/CT ของผู้ป่วยแต่ละราย คำนวณค่า diagnostic value (sensitivity, specificity, positive predictive value, negative predictive value และ accuracy) ของ FDG PET/CT ในการวินิจฉัยการแพร่กระจายไปต่อมน้ำเหลืองและการแพร่กระจายไปอวัยวะอื่น

ผลการศึกษา: ระยะของโรคก่อนตรวจ FDG PET/CT ประกอบด้วยระยะ IA (5 ราย) ระยะ IB (4 ราย) ระยะ IIB (1 ราย) ระยะ IIIA (3 ราย) และระยะ IV (11 ราย) ระยะของโรคระหว่างก่อนและหลังตรวจ FDG PET/CT แตกต่างกันในผู้ป่วย 10/24 ราย (41.7%) ผู้ป่วย 7/24 ราย (29%) มีระยะของโรคเพิ่มขึ้น และ 3/24 ราย (12.5%) มีระยะของโรคลดลงหลังตรวจ FDG PET/CT การกำหนดระยะของโรคก่อนตรวจ FDG PET/CT ถูกต้องในผู้ป่วย 14/24 ราย (58.3%) ขณะที่ระยะของโรคหลังตรวจ FDG PET/CT ถูกต้องในผู้ป่วย 19/24 ราย (79.2%) หลังตรวจ FDG PET/CT แผนการรักษาของผู้ป่วย 5/24 ราย (20.8%) เปลี่ยนไปจากแผนการรักษาเดิม การตรวจ FDG PET/CT ช่วยป้องกันการผ่าตัดที่ไม่จำเป็นในผู้ป่วย 2 ราย

สรุป: FDG PET/CT มีบทบาทสำคัญในการกำหนดระยะของโรคมะเร็งปอดชนิด non-small cell ข้อมูลที่ได้จาก FDG PET/CT มีผลต่อแนวทางการรักษาผู้ป่วยและลดการผ่าตัดที่ไม่จำเป็นในผู้ป่วยที่มีการแพร่กระจายของโรค
