

# Case Report

## Laparoscopic Transperitoneal Gonadal Vein Ligation for Treatment of Pelvic Congestion Secondary to Nutcracker Syndrome: A Case Report

Vichit Viriyaraj MD\*, Prinya Akranurakkul MD\*,  
Bunlung Muyphuag MD\*, Maethaphan Kitporntheranunt MD\*\*

\* Department of Surgery, Faculty of Medicine, Srinakharinwirot University, Nakhon Nayok, Thailand

\*\* Department of Obstetrics & Gynecology, Faculty of Medicine, Srinakharinwirot University, Nakhon Nayok, Thailand

---

*Nutcracker syndrome is the term used to describe the patient with clinical symptoms of entrapment of the left renal vein between the aorta and the superior mesenteric artery. Pelvic congestion syndrome, which is a cause of chronic pelvic pain in women, may be due to Nutcracker syndrome. There are many modalities of treatment for Nutcracker syndrome. This is a case report of a 32-year old woman with pelvic congestion syndrome due to Nutcracker syndrome, who subsequently underwent laparoscopic transperitoneal left gonadal vein ligation. She has had complete remission of pain in 4 months after the operation and after 12 months of follow-up. Laparoscopic transperitoneal gonadal vein ligation is an approach that is safe, simple and provides good results for patient with pelvic congestion syndrome secondary to Nutcracker syndrome.*

**Keywords:** Nutcracker syndrome, Pelvic congestion syndrome, Laparoscopic gonadal vein ligation, Chronic pelvic pain, Entrapment of left renal vein

**J Med Assoc Thai 2012; 95 (Suppl. 12): S142-S145**

**Full text. e-Journal:** <http://jmat.mat.or.th>

---

The Nutcracker phenomenon is characterized by compression of the left renal vein (LRV) between the aorta and the superior mesenteric artery (SMA). This morphologic feature is caused by dilatation of the renal vein and gonadal vein. The term “Nutcracker syndrome” is reserved for patients, who display clinical symptoms associated with this phenomenon. The clinical features vary from asymptomatic hematuria to severe pelvic congestion. Pelvic congestion syndrome (PCS) is a condition of chronic pelvic pain with the presence of ovarian and pelvic varices. Most patients with PCS present with noncyclical pain for more than 6 months, which is worsened by sitting, standing, during or after intercourse, or just before the onset of menstruation. Management of PCS includes many modalities such as medical management with hormonal treatment, surgical ligation of ovarian veins, hysterectomy with salpingo-oophorectomy and transcatheter embolization of the ovarian veins. The authors described a case of laparoscopic transperitoneal

gonadal vein ligation for treatment pelvic congestion secondary to Nutcracker syndrome.

### Case Report

A 32-year old woman, gravida 4, para 1-0-3-1, last child 6 years of age presented with chronic pelvic pain for the last 5 years. The pelvic pain was noncyclical and the visual analogue pain score (VAS) was 8/10, which indicates disturbance in the quality of life. She also had dyspareunia and secondary amenorrhea. No hematuria was present. Her physical examination was found to be unremarkable. Routine laboratory evaluation showed normal values and blood examination work up for amenorrhea showed normal thyroid function test, prolactin level, estradiol (E2) levels, luteinizing hormone (LH) levels and follicle stimulating hormone (FSH) levels. Transvaginal ultrasonography showed dilated and tortuous vessels around the uterus and parametrium. She then underwent diagnostic laparoscopy which revealed dilation and engorgement of the veins at the left pelvic wall, both adnexa and both infundibulopelvic (IP) ligaments (Fig. 1-2). Computerized tomography (CT) scan showed compression of the left renal vein between the aorta and the superior mesenteric artery, also demonstrating that the angle and distance between the two vessels

---

### Correspondence to:

Viriyaraj V, Department of Surgery, Faculty of Medicine, Srinakharinwirot University, 62 Moo7, Ongkharak, Nakhon Nayok 26120, Thailand.

Phone: 037-395-085 ext. 11201

E-mail: [vivichit@yahoo.com](mailto:vivichit@yahoo.com)

measured at 18 degrees and 3 mm respectively (the cutoff value for the angle and distance is  $< 39.3$  degrees and  $< 3.10$  mm). There was also distal dilation of the left renal vein and congestion of the left ovarian and uterine veins. These findings were compatible with Nutcracker syndrome (Fig. 3-4).

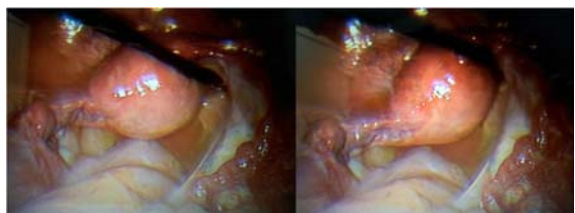
The patient had not shown a response to DMPA injections. She then underwent laparoscopic transperitoneal left gonadal vein ligation and was discharged two days after the operation and without any complications. She was followed-up 1, 2, 3 and 4 months later and her VAS score was 8, 7, 5 and 0 respectively. She did not require additional analgesic drugs and her menstruation was regular again. CT scan demonstrated that there was no longer any dilatation of the gonadal vein and pelvic varicosities present at 3 months after the operation. She had complete remission of pain at the 12 months follow-up visit.

## Discussion

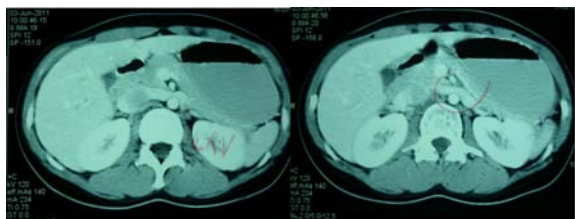
Entrapment of the LRV between the abdominal aorta and SMA has been described by Grant, an anatomist, in the year 1937<sup>(1)</sup>. In 1950, El-Sadr and Mina reported the first clinical case of this phenomenon<sup>(2)</sup>. The term “Nutcracker syndrome” is reserved for patients with clinical symptoms that are associated with this phenomenon. The term Nutcracker syndrome was first described by De Schepper in 1972<sup>(3)</sup>. Nutcracker

syndrome most often occurs in the second or third decade of life. The clinical symptoms vary from asymptomatic hematuria to severe pelvic congestion. They most commonly include hematuria, abdominal or flank pain, orthostatic proteinuria, orthostatic intolerance and pelvic congestion syndrome. A diagnosis of Nutcracker syndrome may be made when there is a clinically suspected and radiologic demonstration of LRV entrapment by venography, doppler ultrasonography, computerized tomography or magnetic resonance imaging. A venous pressure gradient between the left renal vein and the inferior vena cava during venography is the “gold standard” for the diagnosis of left renal vein compression (normal  $< 1$  mmHg)<sup>(4)</sup>. Computerized tomography is able to find the angle and the distances between the aorta and SMA. Normally, the angle and the distance are  $90 \pm 10$  degrees and  $12 \pm 1.8$  mm, respectively. In Nutcracker syndrome, the angles and distances are  $39.3 \pm 4.3$  degrees and  $3.1 \pm 0.2$  mm, respectively<sup>(5)</sup>. In this particular case, the angle and distance between two vessels measured at 18 degrees and 3 mm, which is compatible with a diagnosis of Nutcracker syndrome.

Pelvic congestion syndrome is characterized by the presence of ovarian and pelvic varicosities in the patient that has chronic pelvic pain. The pain is defined as continuous or intermittent noncyclical pain for more than 6 months that is worsened by sitting or standing. The patient may also have associated dyspareunia, dysmenorrhea and postcoital pain. In the past, chronic pelvic pain has often been overlooked and underdiagnosed. 10-30% of patients with chronic pelvic pain have Pelvic congestion syndrome<sup>(6)</sup>, which is a condition that was first described by Taylor in 1949<sup>(7)</sup>. The typical age of affected patients are 20-30 years. The pathogenesis of Pelvic congestion syndrome is multifactorial. Some authors classify the syndrome into primary and secondary pelvic congestion syndrome. The factors associated with primary pelvic congestion syndrome include pregnancy, autonomic nervous system imbalance and psychiatric conditions<sup>(8)</sup>. Nutcracker syndrome, in which the left renal vein and left gonadal vein are compressed by the superior mesenteric artery and aorta is a syndrome that leads to secondary pelvic congestion syndrome. Diagnosis of pelvic congestion syndrome is based upon awareness and clinical suspicion. Pelvic ultrasound and computerized tomography scan are usually the initial imaging modalities for pelvic congestion syndrome. Pelvic ultrasound will demonstrate multiple dilated ovarian vein ( $> 4$  mm) with slow



**Fig. 1-2** Laparoscopy revealed dilatation and engorgement of the veins at the left pelvic wall, both adnexa, and both infundibulopelvic (IP) ligaments



**Fig. 3-4** Computerized tomography (CT) scan revealed compression of the left renal vein between the aorta and the superior mesenteric artery

blood flow (< 3 cm/second), a tortuous arcuate vein across the myometrium communicating with bilateral pelvic varicose veins and reversed caudal or retrograde venous flow<sup>(6)</sup>. CT scan and MRI may demonstrate a dilated, tubular contrast enhancing structure adjacent to the adnexa that is more than 4 mm in diameter<sup>(9)</sup>.

The treatment of secondary pelvic congestion syndrome is essentially the treatment of the primary cause. Management options of Nutcracker syndrome depend on the severity of symptoms. Conservative treatment with observation is recommended for mild hematuria. Surgical treatment such as LRV transposition, LRV bypass, SMA transposition and renal autotransplantation is reserved for cases with persistent hematuria<sup>(10)</sup>. More recently, endoscopic treatment such as an intravascular self-expanding stent has also been utilized as an additional novel modality of treatment. Many modalities of treatment have been proposed for patients with chronic pelvic pain due to pelvic congestion syndrome. Medical treatment includes psychotherapy, hormonal analogues (medroxyprogesterone acetate, goserelin) and nonsteroidal anti-inflammatory drugs (NSAIDs)<sup>(11)</sup>. In this patient, medical treatment was attempted but was not successful. Edwards et al first reported transcatheter embolization of the ovarian vein in patient with PCS in 1993<sup>(12)</sup>. This modality of treatment may provide up to 83% of symptomatic improvement<sup>(13)</sup>. The complication rates with complications such as gonadal vein perforation, non-target embolization including pulmonary coil embolization, and cardiac arrhythmias are high with this treatment<sup>(14)</sup>. Surgical treatment such as hysterectomy with oophorectomy give moderate relief of pain but the recurrence rate is 30%<sup>(15)</sup>. More recently, laparoscopic ovarian vein ligation has become a treatment option for patients with pelvic congestion syndrome. The first case of pelvic congestion syndrome managed by laparoscopic transperitoneal ovarian ligation was done by Mathis BV et al in 1995<sup>(16)</sup>. Thereafter, Takeuchi K et al reported two cases of laparoscopic varicocele ligation for PCS<sup>(17)</sup>. In a series by Gargiulo et al, the patients with PCS who underwent laparoscopic transperitoneal ligation of ovarian veins were in complete remission of pain at 12 months<sup>(18)</sup>. The laparoscopic ligation gonadal vein approach has the advantage of rapid recovery with good clinical as well as cosmetic results. The authors think laparoscopic transperitoneal gonadal vein ligation is an approach which is safe, simple and provides good results for the patient with pelvic congestion syndrome secondary to Nutcracker

syndrome.

### Conclusion

The diagnosis of Nutcracker syndrome should be considered on the basis of careful clinical examination in patients with chronic pelvic pain. Laparoscopic transperitoneal gonadal vein ligation approach can be an effective treatment of the patient with Nutcracker and Pelvic congestion syndrome. There are many available modalities treatment of Nutcracker and pelvic congestion syndrome; a laparoscopic approach will be a safe, simple option that provides good results.

### Potential conflicts of interest

None.

### References

1. Grant JCB. A method of anatomy, descriptive and deductive. 3<sup>rd</sup> ed. Baltimore, MD: Williams and Wilkins; 1944.
2. El Sadr AR, Mina E. Anatomical and surgical aspects in the operative management of varicocele. *Urol Cutaneous Rev* 1950; 54: 257-62.
3. de Schepper A. "Nutcracker" phenomenon of the renal vein and venous pathology of the left kidney. *J Belge Radiol* 1972; 55: 507-11.
4. Beinart C, Sniderman KW, Tamura S, Vaughan ED Jr, Sos TA. Left renal vein to inferior vena cava pressure relationship in humans. *J Urol* 1982; 127: 1070-1.
5. Fu WJ, Hong BF, Gao JP, Xiao YY, Yang Y, Cai W, et al. Nutcracker phenomenon: a new diagnostic method of multislice computed tomography angiography. *Int J Urol* 2006; 13: 870-3.
6. Beard RW, Highman JH, Pearce S, Reginald PW. Diagnosis of pelvic varicosities in women with chronic pelvic pain. *Lancet* 1984; 2: 946-9.
7. Taylor HC Jr. Vascular congestion and hyperemia; their effect on function and structure in the female reproductive organs; the clinical aspects of the congestion-fibrosis syndrome. *Am J Obstet Gynecol* 1949; 57: 637-53.
8. Beck RP. Pelvic congestion syndrome. *Can Fam Physician* 1969; 15: 46-50.
9. Coakley FV, Varghese SL, Hricak H. CT and MRI of pelvic varices in women. *J Comput Assist Tomogr* 1999; 23: 429-34.
10. Kurklinsky AK, Rooke TW. Nutcracker phenomenon and nutcracker syndrome. *Mayo Clin Proc* 2010; 85: 552-9.

11. Soysal ME, Soysal S, Vicdan K, Ozer S. A randomized controlled trial of goserelin and medroxyprogesterone acetate in the treatment of pelvic congestion. *Hum Reprod* 2001; 16: 931-9.
12. Edwards RD, Robertson IR, MacLean AB, Hemingway AP. Case report: pelvic pain syndrome—successful treatment of a case by ovarian vein embolization. *Clin Radiol* 1993; 47: 429-31.
13. Kim HS, Malhotra AD, Rowe PC, Lee JM, Venbrux AC. Embolotherapy for pelvic congestion syndrome: long-term results. *J Vasc Interv Radiol* 2006; 17: 289-97.
14. Maleux G, Stockx L, Wilms G, Marchal G. Ovarian vein embolization for the treatment of pelvic congestion syndrome: long-term technical and clinical results. *J Vasc Interv Radiol* 2000; 11: 859-64.
15. Carter JE. Surgical treatment for chronic pelvic pain. *JSLs* 1998; 2: 129-39.
16. Mathis BV, Miller JS, Lukens ML, Paluzzi MW. Pelvic congestion syndrome: a new approach to an unusual problem. *Am Surg* 1995; 61: 1016-8.
17. Takeuchi K, Mochizuki M, Kitagaki S. Laparoscopic varicocele ligation for pelvic congestion syndrome. *Int J Gynaecol Obstet* 1996; 55: 177-8.
18. Gargiulo T, Mais V, Brokaj L, Cossu E, Melis GB. Bilateral laparoscopic transperitoneal ligation of ovarian veins for treatment of pelvic congestion syndrome. *J Am Assoc Gynecol Laparosc* 2003; 10: 501-4.

---

รายงานผู้ป่วย 1 ราย ที่รักษาภาวะเลือดคั่งในอุ้งเชิงกราน สาเหตุเนื่องจาก *Nutcracker syndrome* โดยการส่องกล้องผ่าตัดผ่านทางช่องท้องเพื่อผูกเส้นเลือดดำ gonadal

วิจิต วิริยะโรจน์, ปริญา อัครานุรักษ์กุล, บัลลังก์ มุขเผือก, เมธาพันธ์ กิจพรธีรานันท์

ภาวะ *Nutcracker syndrome* เป็นภาวะที่เกิดกับผู้ป่วยที่มีอาการจากการโดนกดเบียดของเส้นเลือดดำที่ไปเลี้ยงไตด้านซ้ายโดยเส้นเลือดแดงใหญ่ในช่องท้อง (aorta) กับเส้นเลือดแดง superior mesenteric การโดนกดเบียดของเส้นเลือดดำที่ไปเลี้ยงไตด้านซ้ายจะทำให้มีภาวะเลือดคั่งในอุ้งเชิงกราน ทำให้ผู้ป่วยมีอาการปวดท้องในอุ้งเชิงกรานแบบเรื้อรัง การรักษาภาวะ *Nutcracker syndrome* สามารถรักษาได้หลายวิธี รายงานฉบับนี้ได้นำเสนอผู้ป่วยหญิง อายุ 32 ปี ที่มีอาการปวดท้องในอุ้งเชิงกรานแบบเรื้อรังจากเลือดคั่งในอุ้งเชิงกรานที่มีสาเหตุเนื่องจาก *Nutcracker syndrome* ได้รับการรักษาโดยการส่องกล้องผ่าตัดผ่านทางช่องท้องเพื่อไปผูกเส้นเลือดดำ gonadal หลังจากการผ่าตัดผู้ป่วยหายจากการปวดท้องในอุ้งเชิงกราน ภายในเวลา 4 เดือน และไม่มีอาการปวดท้องอีกตลอดระยะเวลา 12 เดือนที่ติดตามการรักษา วิธีการส่องกล้องผ่าตัดผ่านทางช่องท้องเพื่อผูกเส้นเลือดดำ gonadal เป็นวิธีการที่ง่ายและปลอดภัย ให้ผลการรักษาที่ดีสำหรับผู้ป่วยที่มีภาวะเลือดคั่งในอุ้งเชิงกราน สาเหตุเนื่องจาก *Nutcracker syndrome*

---