

Ovarian Reserve Evaluation by Anti-Mullerian Hormone in Women Undergoing Laparoscopic Cystectomy of Endometrioma

Singpetch Suksompong MD*, Surachai Dejarkom MD*,
Somsin Petyim MD*, Chongdee Dangrat MSc**,
Daunpen Orachon BNS*, Rounsin Choavaratana MD*

* Infertility Unit, Department of Obstetrics and Gynecology, Faculty of Medicine Siriraj Hospital,
Mahidol University, Bangkok, Thailand

** Gynecologic Endocrinology Unit, Department of Obstetrics and Gynecology, Faculty of Medicine Siriraj Hospital,
Mahidol University, Bangkok, Thailand

Objective: To study the serial changes of serum AMH to determine ovarian reserve recovery after laparoscopic cystectomy of endometrioma.

Material and Method: Forty-three endometrioma patients who underwent laparoscopic cystectomy of endometrioma were tested for levels of serum AMH at preoperation, 1 week, and 3 months postoperation.

Results: Median serum AMH was 2.11 ng/mL (range = 0.22 to 9.24 ng/mL) before surgery. This level also reduced at first week postoperation ($p < 0.01$) but did not reach a significant difference between the first week and the third month (1.02 ng/mL and 1.06 ng/mL, respectively). The recovery rate of AMH level in unilateral endometrioma was higher than bilateral endometrioma (32.4% vs. -3.6%, $p = 0.02$).

Conclusion: Ovarian reserve was decreased after laparoscopic cystectomy of endometrioma and did not significantly restore after three months of postoperation. The recovery of ovarian reserve after unilateral endometriotic cystectomy was faster than that after bilateral endometriotic cystectomy.

Key words: Ovarian reserve, Anti-mullerian hormone, Endometrioma, Laparoscopic cystectomy

J Med Assoc Thai 2012; 95 (11): 1389-95

Full text. e-Journal: <http://jmat.mat.or.th>

Endometrioma, a formation of a cyst with ectopic endometrial lining within the ovary, is found in 17% to 44% of patients suffering from endometriosis⁽¹⁾. The patients, who suffer from this disease, especially in the advanced stage of endometriosis, are associated with increased morbidity⁽²⁾. Nowadays, laparoscopic ovarian cystectomy is currently the treatment of choice for treatment of endometrioma and has gained acceptance among gynecologic surgeons, but the safety of this technique in terms of ovarian damage has been questioned⁽³⁾. The ovarian damage may occur after the removal of normal ovarian tissue during cystectomy as well as thermal damage during the use of bipolar coagulation to stop bleeding in the ovarian tissue.

The term of ovarian reserve is defined as the quantity and quality of oocytes in the ovaries of a woman⁽⁴⁾. The ovarian reserve cannot be measured directly. It can be measured indirectly by ultrasound for antral follicle count (AFC) or ovarian volume, or biochemical test evaluated by various serums testing, such as day 3 FSH, day 3 inhibin B, and antimullerian hormone (AMH). Recent data has indicated that AMH is the best marker of ovarian reserve⁽⁵⁾.

Antimullerian hormone (AMH), also known as Mullerian inhibiting substance (MIS), is a member of the TGF- β family of glycoprotein differentiated factors produced by granulosa cells of preantral and small antral follicles (2-6 mm). It may play a role in initial recruitment and in a selection of the dominant follicle⁽⁶⁾. There are potential advantages of AMH over other conventional markers of ovarian reserve⁽⁷⁻⁹⁾. For example, it is the most sensitive marker to change according to a patient's age and it is not affected by GnRH agonist, gonadotropin, pregnancy, or sex hormone⁽¹⁰⁻¹²⁾. During the menstruation cycle, this

Correspondence to:

Suksompong S, Infertility Unit, Department of Obstetrics and Gynecology, Faculty of Medicine Siriraj Hospital, Mahidol University, Bangkok 10700, Thailand

Phone: 0-2419-7000 ext. 4651-2

E-mail: dejarkom@hotmail.com

hormonal level is stable throughout; therefore, it seems to be a good marker anytime during the cycle^(13,14). Some studies used serum AMH for monitoring ovarian reserve change after the patient receives chemotherapy⁽¹⁵⁾ or after ovarian cystectomy in a patient with benign ovarian cyst^(16,17).

Many of these studies supported the view that removal of endometrioma contributes to the detriment of the ovarian reserve and most of these studies only partly involved patients who required assisted reproductive technology (ART). Their results also showed that the number of retrieved oocytes in operative gonads markedly decreases compared with the intact ovary^(3,18-20). However, there is no study directly evaluating ovarian damage and residual ovarian reserve after ovarian cystectomy in endometrioma, especially in the group of infertile patients. In the present study, ovarian reserves after laparoscopic cystectomy of endometrioma, were therefore evaluated by using the analysis of serum AMH.

Material and Method

This prospective study, which was conducted in accordance with the ethical principles stated in the recent version of the Declaration of Helsinki, was performed in the Infertility unit and Gynecologic Endocrinology unit, Department of Obstetrics and Gynecology, Faculty of Medicine Siriraj Hospital, Mahidol University starting in March 2009 until completing sample collection and follow-up. This study protocol was approved by Siriraj Institutional Review Board (SiRB), Faculty of Medicine, Siriraj Hospital, Mahidol University. The protocol number is EC617/2551(EC1), and informed consents were obtained from all patients.

Inclusion criteria of the present study were as follows: Reproductive age of women 20 to 40 years, normal menstrual cycle between 21 and 35 days, endometrioma size ≥ 4 cm and no previous history of ovarian surgery. The exclusion criteria were other ovarian operations such as ovarian drainage or oophorectomy.

Since endometrioma was diagnosed and its size was indicated for surgery, the laparoscopic cystectomy was performed by two experienced surgeons through a 10 mm subumbilical port and two 5 mm ports in the lower abdomen. During laparoscopic surgery, an initial diagnostic evaluation of the pelvic pathology was identified, and then the endometrioma was decompressed. Removal of the cyst was carried

out carefully by identifying the cyst wall and removing it from the ovarian cortex by traction and counter traction with two atraumatic grasping forceps. Bipolar forceps were used carefully for haemostasis when necessary. No suturing of ovarian tissue was used in the present study.

Blood samples were collected from each patient at the pre-operation stage and during two follow-up visits at one-week and three-months after surgery, not specifically obtained in early follicular phase. The serum was immediately separated from cellular content by centrifuging at 3,000 rpm for 10 minutes, and was transferred to 1.5 ml of sterile eppendorf tubes stored at -20°C until further experiments. After collecting all the serum samples, all frozen serums were thawed at room temperature for 30 minutes and an AMH assay was performed. All samples in the present study were re-evaluated by duplicated AMH assay.

Serum AMH was measured by enzyme-linked immunosorbent assay (ELISA, Beckman Coulter, France). The measurement range of the test was 0.14 to 21 ng/mL. The intraassay and interassay coefficients of variation were below or equal to 12.3% and 14.2%. The main outcome measurements were serum AMH at pre-operation, one-week, and three-month postoperation and the changes of serum AMH levels during the follow-up period. The changes of serum AMH level were calculated by the formulas presented as following⁽²¹⁾:

Rate of decline (%) = [(preoperative AMH – AMH at 1 wk) / preoperative AMH] x 100

Rate of recovery (%) = [(AMH at 3 month – AMH at 1 wk) / (preoperative AMH – AMH at 1wk)] x 100

Since the presentation of endometriomas varied in their sizes and the number of ovaries involved (unilateral ovary or bilateral ovaries), subgroup analysis of the data from these patients was performed. Regarding the number of disease-involved ovaries, comparison of the data from unilateral and bilateral endometrioma was analyzed. With respect to various sizes of endometriomas, the patients were grouped by using the size of endometrioma into three groups 1) endometrioma < 5 cm both ovaries, 2) endometrioma ≥ 5 cm in one ovary and < 5 in the other ovary, 3) endometrioma ≥ 5 cm both ovaries.

Statistical analysis

Statistical analysis was performed using Statistics Package for Social Sciences (SPSS) for

Windows, version 13.0 (SPSS Inc., Chicago, IL, USA). A Kolmogorov-Smirnov test was applied to a normality test. Descriptive data was presented as mean and median. A Wilcoxon-signed-rank test was used to compare serum AMH between preoperative, one-week, and three-month postoperation, while a Mann-Whitney U test and Kruskal-Wallis test were applied for the comparison between groups. The results were considered statistically significant at $p < 0.05$.

Results

Fifty patients who underwent laparoscopic cystectomy of endometrioma were enrolled in the present study. Five patients were lost during follow-up and two patients were excluded because they underwent ovarian drainage and oophorectomy. Thus, 43 patients were completely followed until the end of the study (Fig. 1). All ovarian cysts, which were removed, were sent for pathological diagnosis, and were diagnosed of endometriotic cyst.

The baseline characteristic data of patients is shown in Table 1. Mean age of these patients was 33.0 ± 4.5 years and mean BMI was 19.7 ± 2.1 kg/m². Eighty-six percent of patients were nulliparous and 65% had unilateral endometrioma. Five percent of

Table 1. Baseline characteristic of patients

Patient characteristics	Value
Age (years), mean \pm SD	33.0 \pm 4.5
BMI (kg/m ²), mean \pm SD	19.7 \pm 2.1
PCOS, n (%)	
Present	2 (4.7)
Absent	41 (95.3)
Parity, n (%)	
Nulliparous	37 (86.0)
Multiparous	6 (14.0)
Laterality, n (%)	
Unilateral	28 (65.1)
Bilateral	15 (34.9)
Pre operative hormone, n (%)	
None	36 (83.7)
OCP	2 (4.7)
Progestin	0 (0)
GnRH agonist	5 (11.6)
Post operative hormone, n (%)	
None	28 (65.1)
OCP	8 (18.6)
Progestin	3 (7.0)
GnRH agonist	4 (9.3)

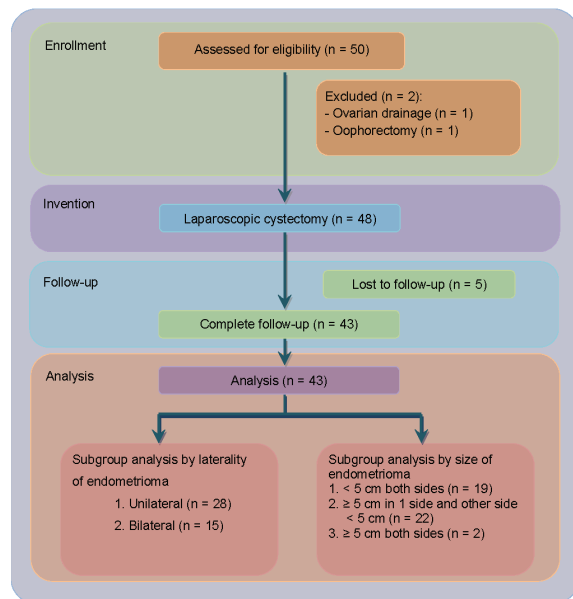


Fig. 1 Flow chart showing flow participants and research methodology

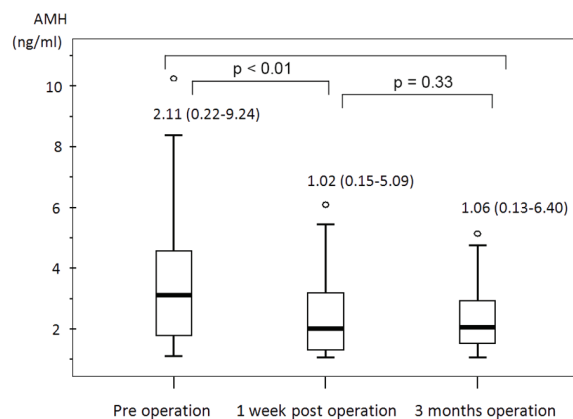


Fig. 2 Serial changes of serum AMH level before and after laparoscopic cystectomy of endometrioma (a) Statistical significant between pre-operation and 1 week after operation ($p < 0.01$) (b) No statistical significant between 1 week and 3 months post operation ($p = 0.33$)

patients had polycystic ovarian syndrome according to Rotterdam criteria. Most patients in the present study did not use hormonal treatment for endometrioma.

The median level of preoperative serum AMH was 2.11 ng/ml (range = 0.22 to 9.24 ng/ml). This level significantly decreased to 1.02 ng/ml after one week postoperation ($p < 0.01$; range = 0.15 to 5.09 ng/ml). At three months after laparoscopic surgery, serum AMH was not significantly different from its previous

level, 1.06 ng/ml ($p = 0.33$; range = 0.13 to 6.40 ng/ml) (Fig. 2). The decline rate of serum AMH was 42.7% (range = 5.6% to 94.7%), while the recovery rate was 12.5% (range = -388.9% to 336.1%).

According to the subgroup analysis of laterality of endometrioma (Table 2), serum AMH significantly decreased at 1 week after surgery ($p < 0.01$) and had no difference of decline rate between both groups ($p = 0.91$) (Table 2). At three months after surgery, serum AMH in the unilateral endometrioma group increased from its level at 1 week but did not reach a level that was statistically significant ($p = 0.08$), while in the bilateral group it slightly decreased. Comparing both groups, the unilateral endometrioma group had a higher significant recovery rate of serum AMH than the bilateral endometrioma group ($p = 0.02$) (Table 2).

The size of endometrioma was divided into three subgroups. The first group was endometrioma < 5 cm on both sides of the ovaries. The second group was endometrioma ≥ 5 cm on one side and < 5 cm on the other side. And the third group was endometrioma ≥ 5 cm on both sides of the ovaries. The serum AMH level after operation declined in all of the three groups (39.7%, 42.5%, and 61.8% respectively), with no significant differences between each group ($p = 0.65$) (Table 2). At three months after surgery, serum AMH was recovered 31.5%, 16.1%, and 3.3% respectively and showed no statistical significance between the three subgroups, $p = 0.94$ (Table 2).

Discussion

Endometrioma is a common gynecologic disease resulting in anatomical distortion and usually is associated with infertility problems. Laparoscopic cystectomy is the treatment of choice for endometrioma, especially in infertile women⁽²²⁾. Several studies have showed strong evidence that ovarian cystectomy had adverse effects on ovarian reserve, evaluated by ovarian stimulation outcomes^(3,18-20). However, there was a little evidence of detrimental effect on women evaluated by other methods or not having received any ovarian stimulation^(16,21). Nowadays, ovarian reserve could be precisely evaluated by using serum AMH⁽⁷⁻¹⁴⁾. Hence, serum AMH was selected in the present study to determine the serial change of ovarian reserve assessing after laparoscopic cystectomy of endometrioma.

In the present study, the results showed that serum AMH significantly decreased after surgery but there was no significant difference between one week and three months postoperation. The significant

Table 2. Serial changes of serum AMH level before and after surgery (subgroup analysis by laterality and size of endometrioma) and comparison of decline rate and recovery rate of serum AMH after laparoscopic cystectomy of endometrioma (subgroup analysis by laterality and size of endometrioma)

Subgroup (total n = 43)	Serum AMH level preoperation (ng/ml)		Serum AMH level postoperation (ng/ml)		Rate of decline		Rate of recovery	
	preoperation (ng/ml)		1 week	3 months	%	p-value	%	p-value
Laterality								
Unilateral endometrioma*** (n = 28)	2.14 (0.22 to 9.24)		1.18 (0.15 to 5.09)	1.45 (0.13 to 6.40)	43.8 (5.6 to 94.7)	0.91	32.4 (-117.7 to 336.1)	0.02
Bilateral endometrioma*** (n = 15)	2.11 (0.48 to 6.48)		0.79 (0.16 to 4.45)	0.74 (0.20 to 3.76)	42.5 (8.5 to 91.3)		-3.6 (-388.9 to 220)	
Size of endometrioma								
< 5 cm both sides*** (n = 19)	2.11 (0.31 to 9.24)		0.95 (0.15 to 5.09)	1.65 (0.13 to 6.40)	39.7 (5.6 to 73.4)	0.65	31.5 (-388.9 to 336.1)	0.94
≥ 5 cm on 1 side and other side < 5 cm*** (n = 22)	1.88 (0.22 to 4.47)		1.09 (0.15 to 2.80)	0.72 (0.16 to 3.33)	42.5 (8.5 to 94.7)		16.1 (-164.8 to 150)	
≥ 5 cm both sides*** (n = 2)	1.42 (0.48 to 2.37)		0.59 (0.16 to 1.02)	0.57 (0.20 to 0.94)	61.8 (60.0 to 66.7)		3.3 (-5.9 to 12.5)	

Note: The data were expressed as median (range)

* Significance difference of serum AMH between before and 1 week after surgery

*** No significance difference of serum AMH between 1 week and 3 months after surgery

reduction of serum AMH after laparoscopic cystectomy of endometrioma could be explained by several reasons. Firstly, laparoscopic cystectomy would also remove some normal ovarian tissue adjacent to the endometriotic cyst wall⁽²³⁾. Secondly, normal ovarian tissue would be destroyed from direct electrical injury during surgery especially for hemostasis. Lastly, the inflammatory reaction in the operative ovarian tissues would detrimentally affect folliculogenesis⁽²¹⁾. Regarding serum AMH levels after post ovarian surgery, the previous studies demonstrated inconsistent results and were inconclusive^(16,21). Duru et al presented that laparoscopic cystectomy of endometrioma did not impair the healthy ovarian tissue, which was still secreting the same level of serum AMH⁽¹⁶⁾. Recently, the study published by Chang et al⁽²¹⁾ and Iwase et al⁽²⁴⁾ supported the authors' findings in the present study in that the level of AMH decreased after cystectomy of endometrioma. In contrast to the study by Chang et al⁽²¹⁾, the present study showed no significant increases of serum AMH at three months post-operation. This unexpected result might relate to the blood samples, which were investigated only in endometrioma patients. Moreover, the operation of endometrioma removal related to a high chance of tissue damage from either disease or surgery and resulted in less recovery of the ovary from the operation. However, the ovarian reserve in the authors' study could be recovered by about 12.5%. The exact mechanism of this recovery was unknown but, several mechanisms have been proposed^(21,25-27). The first mechanism proposed relates to the re-establishment of vasculature in the ovary after surgery and the release of AMH from the remaining follicles. The second mechanism is associated with the compensation of remained granulosa cells' function to secrete AMH. The third mechanism postulated that the follicles could be rescued from atretic follicles⁽²⁵⁾. The last mechanism is a controversial theory that surgery-related inflammation induced the regeneration of ovarian follicles from the epithelium ovarian surface^(26,27).

In the present study, the level of serum AMH in unilateral declined at one week postoperation as did AMH levels in bilateral endometrioma (43.8% vs. 42.5%, respectively). However, these findings, contrast with the results from a previous study, reporting a significant decrease of serum AMH in bilateral group⁽²⁴⁾. This result may be confounded by the age of patients and size of endometrioma. In the unilateral endometrioma group, similar to a previous study⁽²¹⁾, the level of serum AMH was significantly recovered

more rapidly than in the bilateral group (32.4% vs. -3.6%, respectively; $p = 0.02$). This could be partially explained by a different degree of cellular damage with more extensive post-operative ovarian tissue injury presented in the bilateral endometrioma than in unilateral endometrioma.

In the subgroup analysis, regarding the difference in size of endometrioma, the decline rates of serum AMH between groups had no statistical significant differences, but the trend of serum AMH was increased in the group with larger size of endometrioma. The recovery rates also showed no statistical significant differences between groups and that the trend of recovery rate decreased in the group with larger size of endometrioma. These results may relate to small samples' size to detect the difference between each group.

Since most patients suffering from endometrioma are highly associated with infertility problems, most of them, especially with a severe degree of endometrioma, required surgical treatment of endometrioma including laparoscopic cystectomy before starting infertility treatment. However, there is little evidence of an appropriate time for starting ovarian stimulation after laparoscopic cystectomy of endometrioma. The results of the present study showed that the ovarian reserve assessed by serum AMH during period of three months after surgery could be partially recovered from one-week postoperation, especially in unilateral or with a smaller size of endometrioma. This restoration of ovarian reserve would indicate the time to start ovarian stimulation after surgery.

The limitation in the present study was related to the short period of follow-up (3 months post-operation). However, it can represent the new cohort of growing follicles because the total duration from a primordial follicle to achieve the preovulatory follicle was approximately 85 days⁽²⁸⁾. During the three months periods in the present study, the level of serum AMH post-operative was successfully presented as the degree of ovarian injury and demonstrated the capability of ovary recovering from the surgery after three months. Future studies should be designed to follow-up the level of serum AMH at after three months post operation (*e.g.* 6 to 12 months) to find out whether a longer period of ovarian recovery has any benefit in terms of the recovery of the ovarian reserve or ovarian stimulated outcome. Other factors that might have confounded the results in the present study were pre- and post-operative hormonal treatment, but it is not a significant effect to the level of AMH^(7,10-12).

Conclusion

Ovarian reserves significantly decreased after laparoscopic cystectomy of endometrioma and could not fully recover as they did before the operation within three months after ovarian cystectomy. Patients with unilateral endometrioma had better recovery of ovarian reserve than bilateral endometrioma.

Acknowledgements

The present study was supported by a Siriraj fund for research and development, Faculty of Medicine, Siriraj Hospital, Mahidol University. I wish to thank Associate Professor Kitirat Techatrasak and Professor Chanchai Vantanasiri for the permission to perform this research. I wish to thank all of the staff members of the Infertility Unit and Gynecologic Endocrinology Unit for their help in conducting the study and Ms. Julaporn Pooliam for her comments on research methodology and statistical analysis. I also thank Adam Williams for helping with the English-proofing the manuscript. Finally, I wish to thank all participants of this research.

Potential conflicts of interest

None.

References

1. Vercellini P, Chapron C, De Giorgi O, Consonni D, Frontino G, Crosignani PG. Coagulation or excision of ovarian endometriomas? *Am J Obstet Gynecol* 2003; 188: 606-10.
2. Busacca M, Vignali M. Ovarian endometriosis: from pathogenesis to surgical treatment. *Curr Opin Obstet Gynecol* 2003; 15: 321-6.
3. Ho HY, Lee RK, Hwu YM, Lin MH, Su JT, Tsai YC. Poor response of ovaries with endometrioma previously treated with cystectomy to controlled ovarian hyperstimulation. *J Assist Reprod Genet* 2002; 19: 507-11.
4. Broekmans FJ, Kwee J, Hendriks DJ, Mol BW, Lambalk CB. A systematic review of tests predicting ovarian reserve and IVF outcome. *Hum Reprod Update* 2006; 12: 685-718.
5. La Marca A, Broekmans FJ, Volpe A, Fauser BC, Macklon NS. Anti-Mullerian hormone (AMH): what do we still need to know? *Hum Reprod* 2009; 24: 2264-75.
6. Visser JA, de Jong FH, Laven JS, Themmen AP. Anti-Mullerian hormone: a new marker for ovarian function. *Reproduction* 2006; 131: 1-9.
7. Fanchin R, Schonauer LM, Righini C, Frydman N, Frydman R, Taieb J. Serum anti-Mullerian hormone dynamics during controlled ovarian hyperstimulation. *Hum Reprod* 2003; 18: 328-32.
8. Tremellen KP, Kolo M, Gilmore A, Lekamge DN. Anti-mullerian hormone as a marker of ovarian reserve. *Aust N Z J Obstet Gynaecol* 2005; 45: 20-4.
9. Kwee J, Schats R, McDonnell J, Themmen A, de Jong F, Lambalk C. Evaluation of anti-Mullerian hormone as a test for the prediction of ovarian reserve. *Fertil Steril* 2008; 90: 737-43.
10. van Rooij IA, Broekmans FJ, te Velde ER, Fauser BC, Bancsi LF, de Jong FH, et al. Serum anti-Mullerian hormone levels: a novel measure of ovarian reserve. *Hum Reprod* 2002; 17: 3065-71.
11. Streuli I, Fraise T, Pillet C, Ibecheole V, Bischof P, de Ziegler D. Serum antimullerian hormone levels remain stable throughout the menstrual cycle and after oral or vaginal administration of synthetic sex steroids. *Fertil Steril* 2008; 90: 395-400.
12. La Marca A, Giulini S, Orvieto R, De L, V, Volpe A. Anti-Mullerian hormone concentrations in maternal serum during pregnancy. *Hum Reprod* 2005; 20: 1569-72.
13. Hehenkamp WJ, Looman CW, Themmen AP, de Jong FH, Te Velde ER, Broekmans FJ. Anti-Mullerian hormone levels in the spontaneous menstrual cycle do not show substantial fluctuation. *J Clin Endocrinol Metab* 2006; 91: 4057-63.
14. La Marca A, Stabile G, Arsenio AC, Volpe A. Serum anti-Mullerian hormone throughout the human menstrual cycle. *Hum Reprod* 2006; 21: 3103-7.
15. Anderson RA, Themmen AP, Al Qahtani A, Groome NP, Cameron DA. The effects of chemotherapy and long-term gonadotrophin suppression on the ovarian reserve in premenopausal women with breast cancer. *Hum Reprod* 2006; 21: 2583-92.
16. Duru NK, Ceyhan T, Goktolga U, Hasimi A, Orhon E, Baser I. Anti-Mullerian hormone is decreased in patients with ovarian endometrioma. *Proceedings of the 23rd Annual meeting of the ESRHE; 2007 July 1-4; Lyon, France: Oxford University Press; 2007.*
17. Han SH, Jee BC, Suh CS, Kim KC, Lee WD, Kim SH. Serial measurement of serum anti-mullerian hormone in women undergoing laparoscopic conservative ovarian surgery [abstract]. *Fertil Steril* 2007; 88(Suppl 1): 169.

18. Nargund G, Cheng WC, Parsons J. The impact of ovarian cystectomy on ovarian response to stimulation during in-vitro fertilization cycles. *Hum Reprod* 1996; 11: 81-3.
19. Loh FH, Tan AT, Kumar J, Ng SC. Ovarian response after laparoscopic ovarian cystectomy for endometriotic cysts in 132 monitored cycles. *Fertil Steril* 1999; 72: 316-21.
20. Ragni G, Somigliana E, Benedetti F, Paffoni A, Vegetti W, Restelli L, et al. Damage to ovarian reserve associated with laparoscopic excision of endometriomas: a quantitative rather than a qualitative injury. *Am J Obstet Gynecol* 2005; 193: 1908-14.
21. Chang HJ, Han SH, Lee JR, Jee BC, Lee BI, Suh CS, et al. Impact of laparoscopic cystectomy on ovarian reserve: serial changes of serum anti-Mullerian hormone levels. *Fertil Steril* 2010; 94: 343-9.
22. Alborzi S, Zarei A, Alborzi S, Alborzi M. Management of ovarian endometrioma. *Clin Obstet Gynecol* 2006; 49: 480-91.
23. Hachisuga T, Kawarabayashi T. Histopathological analysis of laparoscopically treated ovarian endometriotic cysts with special reference to loss of follicles. *Hum Reprod* 2002; 17: 432-5.
24. Iwase A, Hirokawa W, Goto M, Takikawa S, Nagatomo Y, Nakahara T, et al. Serum anti-Mullerian hormone level is a useful marker for evaluating the impact of laparoscopic cystectomy on ovarian reserve. *Fertil Steril* 2010; 94: 2846-9.
25. Fujimori K, Nakamura RM, Tonetta SA, di Zerega GS. Cessation of transition-phase follicle growth in the guinea pig by follicle-regulatory protein. *Biol Reprod* 1987; 37: 812-22.
26. Bukovsky A, Caudle MR, Svetlikova M, Upadhyaya NB. Origin of germ cells and formation of new primary follicles in adult human ovaries. *Reprod Biol Endocrinol* 2004; 2: 20.
27. Bukovsky A, Svetlikova M, Caudle MR. Oogenesis in cultures derived from adult human ovaries. *Reprod Biol Endocrinol* 2005; 3: 17.
28. Gougeon A. Regulation of ovarian follicular development in primates: facts and hypotheses. *Endocr Rev* 1996; 17: 121-55.

การเปลี่ยนแปลงของ *ovarian reserve* ภายหลังการผ่าตัดเลาะถุงน้ำผ่านกล้องในผู้ป่วยเอนโดเมตรีโอมา ประเมินโดยใช้ระดับแอนติมูลเลอร์เลียนฮอร์โมน

สิงห์เพชร สุขสมปอง, สุรัชย์ เดชอาคม, สมสิญจน์ เพ็ชรยิ้ม, จงดี แดงรัตน์, เดือนเพ็ญ อรชร, เรืองศิลป์ เขาวรัตน์

วัตถุประสงค์: เพื่อศึกษาการเปลี่ยนแปลงของ *ovarian reserve* ภายหลังการผ่าตัดเลาะถุงน้ำผ่านกล้องในผู้ป่วยเอนโดเมตรีโอมา ประเมินโดยใช้ระดับแอนติมูลเลอร์เลียนฮอร์โมน

วัสดุและวิธีการ: ผู้ป่วยเอนโดเมตรีโอมา 43 ราย ที่ได้รับการผ่าตัดเลาะถุงน้ำผ่านกล้อง ได้รับการตรวจวัดระดับฮอร์โมนแอนติมูลเลอร์เลียนในซีรัมก่อนผ่าตัด 1 สัปดาห์ และ 3 สัปดาห์หลังผ่าตัด

ผลการศึกษา: มัชฐานของระดับแอนติมูลเลอร์เลียนฮอร์โมนในซีรัมก่อนผ่าตัด 2.11 นก./มล. (พิสัย = 0.22-9.24 นก./มล.) ระดับแอนติมูลเลอร์เลียนฮอร์โมนในซีรัมลดลงหลังผ่าตัด 1 สัปดาห์ ($p < 0.01$) แต่ไม่พบการเปลี่ยนแปลงระหว่างระดับแอนติมูลเลอร์เลียนฮอร์โมนในซีรัมที่ 1 สัปดาห์ และ 3 เดือน อย่างมีนัยสำคัญทางสถิติ (1.02 และ 1.06 นก./มล. ตามลำดับ) อัตราการเพิ่มขึ้นของระดับแอนติมูลเลอร์เลียนฮอร์โมนในซีรัมในกลุ่มที่มีเอนโดเมตรีโอมาข้างเดียว มากกว่าในกลุ่มที่มีเอนโดเมตรีโอมาสองข้าง (32% และ -3.6%, $p = 0.02$)

สรุป: *Ovarian reserve* ลดลงภายหลังการผ่าตัดเลาะถุงน้ำผ่านกล้องในผู้ป่วยเอนโดเมตรีโอมา และไม่สามารถกลับคืนมา ภายหลังการติดตามนาน 3 เดือน ในผู้ป่วยที่มีเอนโดเมตรีโอมาข้างเดียวจะมีการกลับคืนมาของ *ovarian reserve* มากกว่าผู้ป่วยที่มีเอนโดเมตรีโอมาทั้งสองข้าง