

Case Report

Result of Arthroscopic Removal of an Enchondroma at the Talar Dome: A Case Report

Artit Laoruengthana MD*,
Monton Galassi MD*, Santi Weerakul MD*,
Piya Assawaboonyadej MD*, Julintorn Somran MD**

* Department of Orthopaedics, Faculty of Medicine, Naresuan University, Phitsanulok, Thailand

** Department of Pathology, Faculty of Medicine, Naresuan University, Phitsanulok, Thailand

Enchondroma is a benign tumor that is generally asymptomatic and rarely found in the talus. A forty-nine-year-old man, had a chronic left ankle pain which related to moderate to heavy activity. A plain radiograph and magnetic resonance imaging (MRI) revealed a 1.3 cm benign lobulated intramedullary lesion at the middle 1/3 of medial part of talar dome with sclerotic rim. An arthroscopic intralesional curettage of the ankle joint was performed without bone grafting. Histologic examination was consistent with the diagnosis of an enchondroma. The patient was asymptomatic and without restriction on his job at 6 months. At 1 year of follow-up, the CT scan and MRI demonstrated no recurrence of the tumor but the defect was not filled up.

Keywords: Enchondroma, Talus, Arthroscopic intralesional curettage

J Med Assoc Thai 2012; 95 (Suppl. 10): S226-S229

Full text. e-Journal: <http://jmat.mat.or.th>

Enchondroma is a benign tumor that is generally asymptomatic and identified incidentally. In the Mayo clinic series⁽¹⁾, 50% was found in the second to fourth decades of life and the most common site was small bone of hands and feet. Other common site was metaphyseal area of long bones such as humerus and femur while there was only 1 located in the talus. The intralesional curettage is considered to be sufficiency for the enchondroma and it may be conventionally done through an arthrotomy of the ankle or transmalleolar osteotomy approach^(2,3). Since the arthroscopic ankle surgery has been well established in its advantage for diagnosis and certain procedures. It is the author's purpose to apply the minimally invasive surgery to treat this nonaggressive benign tumor of the talar dome instead of a conventional approach. The patient and family were informed that data concerning this case would be submitted for publication.

Case Report

A forty-nine-year-old man, master sergeant, had had left ankle pain for one year which was related to moderate to heavy activity such as long distance

Correspondence to:

Laoruengthana A, Department of Orthopaedics, Faculty of Medicine, Naresuan University, Phitsanulok 65000, Thailand.
Phone:

E-mail: artitlao@gmail.com

walking, running and jumping. He reported no weight loss, fevers, or night pain. Prior to presentation, he had used of nonsteroidal anti-inflammatory medications for pain relief prescribed by several different physicians. Physical and neurological examination revealed unremarkable. A plain radiograph of left ankle demonstrated an ill-defined lytic lesion of the medial talar dome (Fig. 1) and magnetic resonance imaging (MRI) revealed a 1.3 cm lobulated intramedullary lesion at the middle 1/3 of medial part of talar dome with sclerotic rim. The lesion exhibited hypointense signal on T1W and heterogeneous hyperintense with some cystic-like area on T2W (Fig. 2).

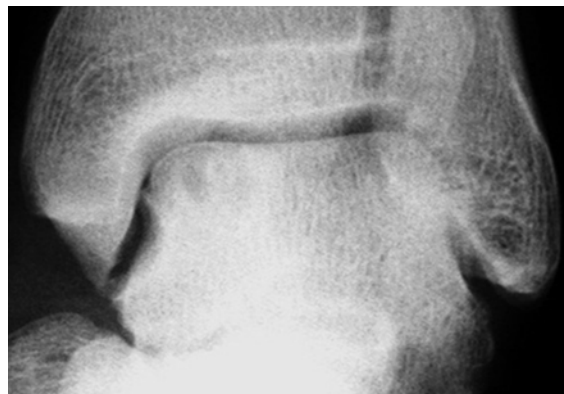

Fig. 1 Preoperative plain radiograph of the left talus

The preliminary diagnosis by diagnostic radiologist was a benign tumor at medial talar dome with a possibility of being chondroblastoma, osteoblastoma and benign cartilaginous tumor. A minimally invasive surgery was performed by arthroscopic assisted through 3 portal approach consisted of superomedial, inferomedial and anterolateral portal. A 30 degree, 2.7 mm arthroscope was used through the anterolateral and superomedial portal for viewing of the lesion, while the superomedial and inferomedial portal was used as a working portal. The loose cartilage was removed and intralesional curettage was done followed with motorized burr until the bleeding bone was demonstrated (Fig. 3). There was no neurological injury, wound complication or infection after the procedure. The short leg cast was applied and the weight-bearing was protected for 6 weeks. Histologic findings of the lesion reveal slate gray or relatively hypocellular lobules of proliferating chondrocytes with no cellular atypia. There is an enchondral bone ossification at the periphery (Fig. 4).

The patient underwent a physical therapy until the motion and weight-bearing of the left ankle was fully recovered at 12 weeks. The patient was asymptomatic with full motion of left ankle and performed his job without restriction at 6 months. The second MRI done at 1 year of follow-up had revealed minimal bone edema surrounding the subchondral bone defect (size 12.5 x 12 x 8.8 mm) at the medial talar dome without evidence of recurrence of the tumor (Fig. 5). The CT scan at 1 year of follow-up demonstrated the residual bone defect without bone filled (Fig. 6).

Discussion

Enchondroma is rarely identified in the talus⁽¹⁾, thus the best treatment option could not be concluded. It is generally accepted that the intralesional curettage is sufficiency and it may appropriately done through the minimally invasive surgery since many author reported a successful result of arthroscopic removal of osteoid osteoma at the talar neck⁽⁴⁻⁶⁾ and intraosseous talar ganglion cyst at the talar dome⁽⁷⁾ and posterior portion of the talus⁽⁸⁾. There was no recurrence of the tumor and the arthroscopic surgery can decrease morbidity, shorten the period of rehabilitation and accelerate the patient function. In the present study, the author preferred the 3 portals technique described by Uysal et al⁽⁷⁾ which they use the superomedial portal to impact the graft. The authors used the superomedial portal to view the bottom of the lesion and check adequacy of the bleeding surface after motorized burr (Fig. 7). The patient in the present study underwent

the arthroscopic intralesional curettage of the left ankle was asymptomatic and recovered with full motion of ankle joint and function. The tumor did not recurred at 1 year of follow-up demonstrated by CT scan and MRI (Fig. 5, 6).

There are several reports of a good result following curettage of the benign tumor of talus without grafting⁽⁹⁻¹²⁾. Ogilvie-Harris et al⁽⁹⁾ reported 9 patients with a satisfactory result and radiographic healing of the defect after treatment of the post-traumatic talar cyst by an arthroscopic removal of the gelatinous material and abraded the cavity without grafting, even in the lesion up to 2 cm. The recent study of treating the

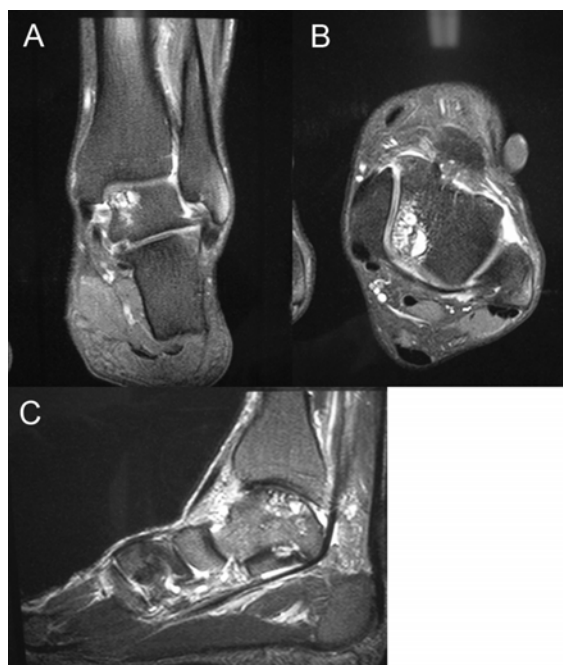


Fig. 2 A-C, Preoperative MRI of the left talus

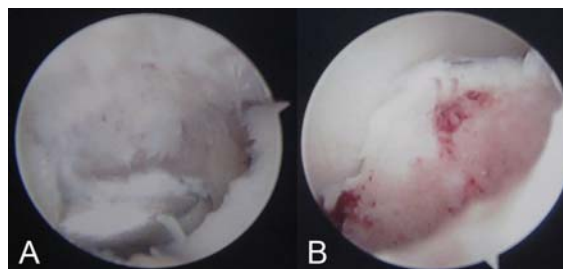


Fig. 3 A, Arthroscopic intralesional curettage of the medial talar dome removed a soft white tissue. B, The rim of the lesion was abraded until bleeding bone was demonstrated

enchondroma with open⁽¹⁰⁾ and/or endoscopic⁽¹¹⁾ curettage without grafting revealed a spontaneous bone formation that its period correlated with the tumor size. Shears et al⁽¹²⁾ stated a full consolidation of the defect within 6 to 12 months among all 8 patients underwent the curettage for the benign tumor without bone grafting. They found no talar collapse or fracture but one had a tibiotalar osteoarthritic progression that comparable to the osteoarthritis development of grafted patients in other series⁽¹³⁾. In the present patient, the CT scan and MRI studied at 1 year of follow-up could not demonstrated a spontaneously regeneration of the bone or cartilage. Otherwise, it might require more time to fill up the defect after curettage of the enchondroma of the talar dome. However, the patient in the present study had a satisfactory clinical result that might be because of the defect involving a small area of the bearing surface.

There are reports^(2,7) that recommend the bone

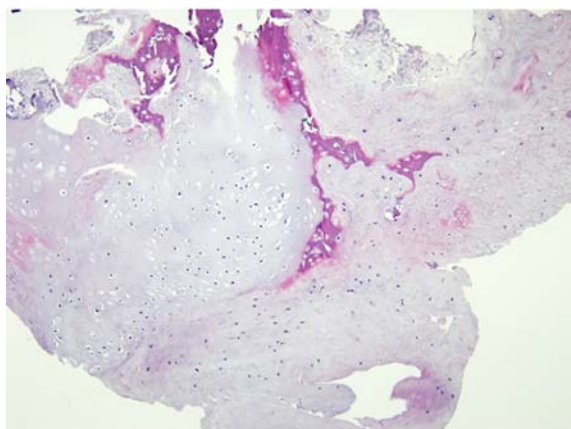


Fig. 4 Enchondroma containing benign cartilaginous lobules rimmed with bony trabeculae (H&E x 100)

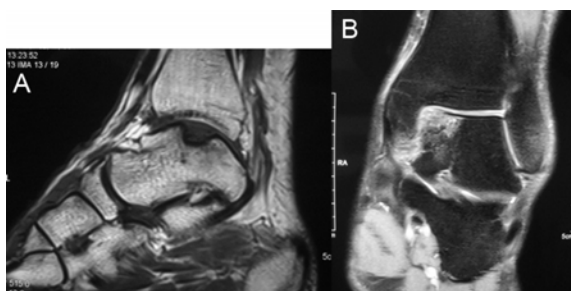


Fig. 5 The MRI at 1 year of follow-up revealed minimal bone edema surrounding the subchondral bone defect at the medial talar dome.

grafting following the curettage of intraosseous talar cyst to obtain a good result. Uysal et al⁽⁷⁾ has clearly demonstrated the osseous filling at the defect after impacting with autograft from the proximal tibia while the cartilage restoration was not clarified. Koulalis et al⁽¹⁴⁾ proposed the chondral restoration should be considered if the defect exceeded 2 cm in diameter beside the osseous restoration. They showed a good outcome of an autologous cultivated chondrocytes transplantation that resulted in a chondral continuity of fibrocartilage. Schoenfeld et al⁽¹⁵⁾ addressed a viability of reconstruction with fresh-frozen osteochondral allograft if an aggressive local resection was required.

This case report illustrates the value of arthroscopic intralesional curettage for removing the enchondroma of the talar dome. The spontaneous regeneration of the bone is questionable, otherwise the bone grafting and/or articular cartilage restoration should be considered.

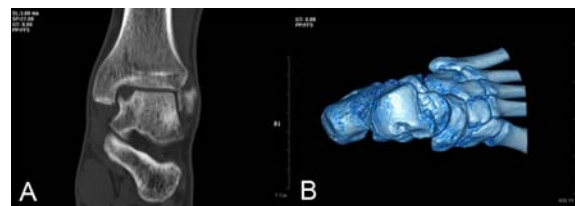


Fig. 6 The CT scan of left ankle following the surgery showed the residual bone defect.

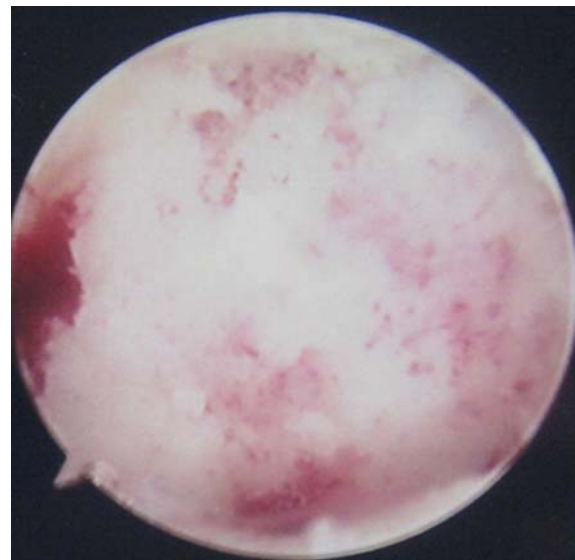


Fig. 7 The bleeding bone of the bottom of the lesion demonstrated through the superomedial portal.

Potential conflicts of interest

None.

References

1. Unni KK. Chondroma. In: Unni KK, Inwards CY, editors. Dahlin's bone tumor: general aspects and data on 10,165 cases. Philadelphia: Lippincott Williams & Wilkins; 2010: 22-40.
2. Patterson RH, Jones M, Tuten R. Intraosseous ganglion cyst of the talus: case report. Foot Ankle 1993; 14: 538-9.
3. Oznur A. Medial malleolar window approach for osteochondral lesions of the talus. Foot Ankle Int 2001; 22: 841-2.
4. Resnick RB, Jarolem KL, Sheskiev SC, Desai P, Cisa J. Arthroscopic removal of an osteoid osteoma of the talus: a case report. Foot Ankle Int 1995; 16: 212-5.
5. Bojanic I, Orlic D, Ivkovic A. Arthroscopic removal of a juxtaarticular osteoid osteoma of the talar neck. J Foot Ankle Surg 2003; 42: 359-62.
6. Tuzuner S, Aydin AT. Arthroscopic removal of an osteoid osteoma at the talar neck. Arthroscopy 1998; 14: 405-9.
7. Uysal M, Akpınar S, Ozalay M, Ozkoc G, Cesur N, Hersekli MA, et al. Arthroscopic debridement and grafting of an intraosseous talar ganglion. Arthroscopy 2005; 21: 1269.
8. Ogut T, Seker A, Ustunkan F. Endoscopic treatment of posteriorly localized talar cysts. Knee Surg Sports Traumatol Arthrosc 2011; 19: 1394-8.
9. Ogilvie-Harris DJ, Sarrosa EA. Arthroscopic treatment of post-traumatic cysts of the talus. Arthroscopy 2000; 16: 197-201.
10. Morii T, Mochizuki K, Tajima T, Satomi K. Treatment outcome of enchondroma by simple curettage without augmentation. J Orthop Sci 2010; 15: 112-7.
11. Sekiya I, Matsui N, Otsuka T, Kobayashi M, Tsuchiya D. The treatment of enchondromas in the hand by endoscopic curettage without bone grafting. J Hand Surg Br 1997; 22: 230-4.
12. Shears E, Dehne K, Murata H, Abudu A, Grimer RJ, Tillman RM, et al. Healing of ungrafted bone defects of the talus after benign tumour removal. Foot Ankle Surg 2008; 14: 161-5.
13. Casadei R, Ruggieri P, Moscato M, Ferraro A, Picci P. Aneurysmal bone cyst and giant cell tumor of the foot. Foot Ankle Int 1996; 17: 487-95.
14. Koulalis D, Schultz W. Massive intraosseous ganglion of the talus: reconstruction of the articular surface of the ankle joint. Arthroscopy 2000; 16: E14.
15. Schoenfeld AJ, Leeson MC, Grossman JP. Fresh-frozen osteochondral allograft reconstruction of a giant cell tumor of the talus. J Foot Ankle Surg 2007; 46: 144-8.

ผลของการรักษาเนื้องอกชนิด *Enchondroma* บริเวณกระดูก *Talus* โดยวิธีผ่าตัดเอาเนื้องอกออกผ่านกล้อง

อาทิศย์ เหล่าเรืองธนา, มณฑล ภาพสีห์, สันติ วีรกุล, ปิยะ อัครบุญญาเดช, จุลินทร สำราญ

เนื้องอกชนิดเอนคอนโดรมา เป็นเนื้องอกชนิดไม่ร้ายแรงที่มักจะพบบ่อยบริเวณกระดูกชนิดแท่งโดยเฉพาะกระดูกนิ้วมือ และมีโอกาสพบน้อยมากที่บริเวณกระดูก *talus* การศึกษานี้รายงานผู้ป่วยชายอายุ 49 ปีที่มีอาการปวดข้อเท้าซ้ายเรื้อรังมานาน 1 ปี ผลการตรวจทางรังสีวิทยาและคลื่นแม่เหล็กไฟฟ้าแสดงลักษณะของเนื้องอกชนิดไม่ร้ายแรงขนาดเส้นผ่านศูนย์กลาง 1.3 ซม. ผู้ป่วยได้รับการรักษาโดยการผ่าตัดขูดเนื้องอกออกผ่านแผลขนาดเล็กโดยใช้กล้องส่องข้อเท้าช่วยในการผ่าตัด ผลตรวจทางพยาธิวิทยาให้การวินิจฉัยตรงกับเนื้องอก *enchondroma* ผู้ป่วยสามารถทำงานได้ตามปกติโดยไม่มีอาการปวดข้อเท้าที่ระยะเวลา 6 เดือน เมื่อติดตามผลการตรวจด้วยเอกซเรย์คอมพิวเตอร์และคลื่นแม่เหล็กไฟฟ้าที่ระยะเวลา 1 ปี ไม่พบการกลับเป็นซ้ำของเนื้องอก *enchondroma* ที่บริเวณ *talus* แต่ยังไม่พบการงอกของกระดูกเข้ามาเติมเต็มบริเวณหลุมกระดูกที่เคยเป็นพยาธิสภาพ