

Chronic Monteggia Lesions Treatment with Open Reduction and Z-Lengthening Technique with Annular Ligament Reconstruction

Perajit Eamsobhana MD*,
Kamolporn Kaewpornasawan MD*

* Department of Orthopaedic Surgery, Faculty of Medicine, Siriraj Hospital, Bangkok, Thailand

Background: The purpose of the present study is to evaluate the clinical and radiographic outcomes after open reduction and Z-lengthening technique with annular ligament reconstruction for the treatment of a chronic Monteggia fracture-dislocation.

Material and Method: The authors postoperatively investigated the clinical and radiographic outcomes for ten children with a chronic Monteggia fracture. The present study group included seven boys and three girls mean age of nine years and one month at the time of open reduction. Each patient had been treated with open reduction of the radial head combined with ulna osteotomy and elongation, bending with z-plasty technique and annular ligament reconstruction. Clinical and radiographic outcomes were reviewed over a mean duration of follow-up of thirty-eight months.

Results: The postoperative Mayo Elbow Performance Index (MEPI) at the time of follow-up ranged from 95 to 100 and no poor results. The radial head remained in a completely reduced position in ten patients. In three patients, osteoarthritic changes were observed at the radiohumeral joint. Radiographically, there were seven good, three fair and no poor results. A fair radiographic result was obtained in the patients who had undergone open reduction more than three years after the injury and two patients was operation at the age of eleven and thirteen years old.

Conclusion: Good clinical and radiographic outcomes can be expected if open reduction for the treatment of a chronic Monteggia fracture is performed when the patient is less than twelve years of age or within three years after the injury. Open reduction and Z-lengthening technique with annular ligament reconstruction for the treatment of a chronic Monteggia fracture-dislocation is safe with good clinical and radiologic outcomes without the need for bone graft. No nonunion is report in our series.

Keywords: Chronic Monteggia, Open reduction, Annular ligament reconstruction, Z-lengthening

J Med Assoc Thai 2012; 95 (Suppl. 9): S47-S53

Full text. e-Journal: <http://jmat.mat.or.th>

Chronic Monteggia lesions in children is often miss diagnosed. The ulna mostly has plastic deformation with radial head dislocation which may not obvious to the clinician. The neglected radial head dislocation is diagnosed several months after the injury when the patient complains of bony prominent, slight or moderate elbow pain, decreased elbow flexion, valgus deformity of the elbow and neurologic problems (sensory or motor loss caused by a tardy ulnar nerve palsy or a posterior interosseous nerve palsy)⁽¹⁻⁶⁾.

Chronic Monteggia lesion is defined as the dislocation is not reduced and still present 4 weeks after injury⁽¹⁾. If left untreated, the dislocated radial head loss its concave articular surface and demonstrates hypertrophic changes and the humeral capitellum

configuration flattens, thereby limiting the range of elbow flexion and extension^(1,2,7). There are many options to treat this problems in growing child, ranging from “neglected” and resection if patient has a symptoms at skeletal maturity⁽⁸⁾, open reduction and ulna osteotomy with or without annular ligament reconstruction. Many authors have recommended that a missed radial head dislocation in a child should be treated with open reduction as early as possible once it is diagnosed^(1,3,8-12).

Even though many authors agree that open reduction is necessary to reduce the radial head, opinions still differ regarding the need for reconstruction annular ligament and the need for overcorrection of the ulna.

Patient age and interval time from injury to operation are also the important factors that affect the surgical outcome after open reduction.

From 2001-2009, ten children with a chronic Monteggia fracture-dislocation have been managed

Correspondence to:

Eamsobhana P, Department of Orthopaedics Surgery, Faculty of Medicine, Siriraj Hospital, Bangkok 10700, Thailand.
Phone: 08-9674-3554
E-mail: peerajite@gmail.com

with open reduction of the radial head combined with z-lengthening ulnar osteotomy and annular ligament reconstruction. The present report describes our surgical technique as well as the clinical and radiographic outcomes.

Material and Method

During the period from 2001 to 2009 ten children with a missed radial head dislocation after a Monteggia fracture were managed consecutively at our hospital with open radial head reduction combined with z-lengthening ulnar osteotomy and annular ligament reconstruction with add transradiocapitellar pin in seven patients.

The present study group included seven boys and three girls with a mean age of nine years (range, 6-13 years) at the time of open reduction. All patients were treated surgically and were followed for at least twenty-four months (mean 38.8 months; range, 24 to 120 months). At the time of follow-up, all patients were interviewed and examined individually by two of the authors about elbow pain, range of elbow movement, elbow stability and any disabilities in daily life, work, or sports. Evaluate of Mayo Elbow Performance score by interview and physical examination is interpreted as excellent (90 or > 90 points), good (75-89 points) fair (60-74 points) and poor (< 60 points).

Range of motion (ROM) measurement

Preoperative and postoperative ROM, expressed as the sum of the flexion-extension arc and pronation-supination arc, was determined with a goniometer using standard method. The authors defined a full flexion-extension arc as 140 degrees, full pronation arc as 80 degrees and full supination arc as 85 degrees.

Radiographic assessment all patients had routine anteroposterior and lateral radiographs of the elbow, which were checked for deformity of the radial head, osteoarthritic changes and dislocation or subluxation of the radial head. The deformity of the radial head was evaluated on the anteroposterior and lateral radiographs according to Kim et al⁽¹⁹⁾. Radial head hypertrophy was determined by measuring the diameter of the radius at the widest portion of the metaphysis adjacent to the physis (a) and the narrowest portion of the neck just proximal to the bicipital tuberosity (b). If a/b was >1.5, radial head hypertrophy was considered to be present. Subluxation of the radial head was considered to be present when a line drawn down the center of the radial neck did not pass through the central one-third of the capitellum on the lateral

radiograph. The radiographic results were divided into three categories: good (complete reduction of the radial head without osteoarthritic changes of the elbow), fair (reduction with radial head subluxation or osteoarthritic changes of the elbow) and poor (radial head dislocation).

Surgical technique

A skin incision was made beginning at the posterior and distal of the humerus and go along distal on the lateral side of the radiocapitellar joint, passing to the level of the proximal metaphysis of the ulna and extending to the middle part of the posterior aspect of the ulna along the bony border of ulna. The radiohumeral joint was approached between the extensor carpi ulnaris and anconeus muscles and fibrous tissue was removed. The radial head was exposed and the state of the cartilage of the radial head was assessed. The remnant of annular ligament was identified and used for augment in the reconstruction of annular ligament with triceps fascia. In all cases, an ulnar osteotomy with z-lengthening technique was performed first and then the radial head was reduced. An ulnar osteotomy with z-lengthening was performed in all patients with Bado type 1, in Bado type 3 the ulna osteotomy was performed to corrected varus deformity but bending and lengthening was not done. The ulna was stabilized with a plate containing four to eight screw holes (Fig. 1).

After reduction of the radial head and fixation of the ulna with a plate, annular ligament reconstruction was performed at the level of the radial neck with triceps fascia and augment with the remnant of annular ligament⁽⁸⁾ in all case. Transradiocapitellar pinning was used in seven case depend on stability after reduction of radial head intraoperatively. Suction drain was applied at the osteotomy site. Postoperatively, a cast was applied with the elbow flexed to 90 degrees and the forearm in a supination position in Bado type 1. The immobilization period was approximately six weeks following surgery. Transradiocapitellar pin was remove at 6 weeks. After removal of the cast, active elbow motion was encouraged, light activity was allowed. Return to physical activity was allowed after radiographic union was seen. There was no specific physiotherapy program.

Results

A summary of the preoperative data is shown in (Table 1). In total ten patients, eight were classified as Bado type I and two were classified as Bado type III.

Anteroposterior and lateral radiographs of the elbow revealed that all patients had a complete dislocation of the radial head; the direction of the dislocation was anterior in eight patients and anterolateral in two. Radial head deformity was observed in three patients, loss of concavity of the radial head was seen in two of these

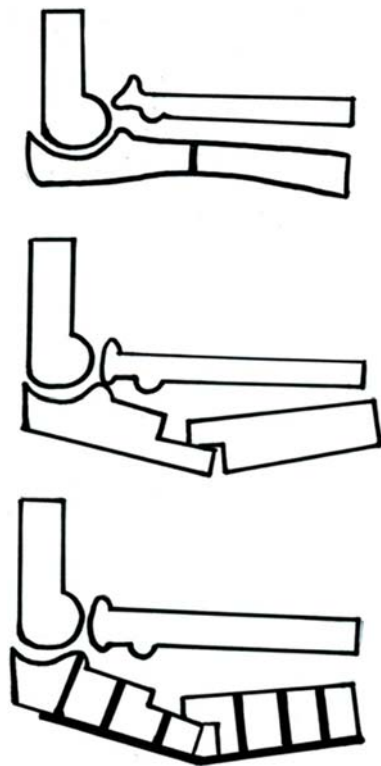


Fig. 1 Ulnar osteotomy with z-lengthening technique and fixation with eight holes plate, without bone graft

patients, and hypertrophy of the radial head was noted in one patient. The overall postoperative clinical results, radiographic results and complications are shown in (Table 2 and 3).

Clinical results

The average MEPI score at the time of the latest follow-up was 99.5, with all excellent results. No patient complained of pain. None of the patient complained of limitations of daily life.

Radiographic results

At the time of the latest follow-up, the radial head was maintained in a completely reduced position in all of the patients. Redislocation of the radial head was observed in one patient postoperatively (patient No. 10) but after closed reduction and fixation with transradiocapitellar pin and pin removal after 6 weeks, no dislocation at 24-month follow-up. Osteoarthritic changes of the radiohumeral joint were observed in three patients, the changes were mild in all three patients.

Mean interval between the injury and open reduction was 38.8 months. Hypertrophy of the radial head was found in one patient, all of whom showed radial head deformity had undergone surgery more than three years after the initial injury.

On the basis of our radiographic evaluation criteria, seven patients were rated as good, three were rated as fair and none were rated as poor (Table 3). The mean MEPI score was 99.5. The mean interval between the injury and open reduction was 28 months for the patients who were rated as good and 64 months for those who were rated as fair. The mean age at the time

Table 1. Clinical data of the ten children in the Study

Pt. No.	Sex	Injury Age	Bado Type	Age at Operation	Preop Delay (mo)	Treatment	f/u (mo)
1	M	5 yr	I	8 yr	36	UO + OR + AR	38
2	M	8 yr	III	11 yr	36	UO + OR + AR	72
3	M	3 yr	I	7 yr	24	UO + OR + AR + TP	36
4	M	5 yr	I	8 yr	36	UO + OR + AR + TP	24
5	M	3 yr	I	6 yr	36	UO + OR + AR + TP	39
6	M	5 yr	I	9 yr	24	UO + OR + AR + TP	25
7	F	8 yr	III	9 yr	8	UO + OR + AR + TP	24
8	M	8 yr	I	13 yr	60	UO + OR + AR + TP	28
9	F	6 yr	I	7 yr	8	UO + OR + AR + TP	29
10	F	3 yr	I	13 yr	120	UO + OR + AR	24

UO: ulna osteotomy, OR: open reduction of radial head, AR: Annular ligament reconstruction, TP: transradiocapitellar pin, F/u, duration of follow-up

Table 2. Pre and Post operative range of motion and complications

Pt. No.	Before Surgery		After Surgery		complication
	Pro-0-sup	Flex-0-ext	Pro-0-sup	Flex-0-ext	
1	60-0-70	120-0-0	80-0-85	130-0-0	-
2	50-0-70	120-0-0	70-0-80	130-0-0	-
3	60-0-80	120-0-0	60-0-80	140-0-0	-
4	60-0-80	100-30-30	70-0-80	120-30-30	-
5	80-0-80	120-0-0	80-0-80	130-0-0	broken of transradiocapitellar pin
6	60-0-80	120-0-0	80-0-85	140-0-0	broken of transradiocapitellar pin
7	80-0-80	120-0-0	80-0-85	140-0-0	-
8	60-0-80	120-0-0	70-0-80	130-0-0	-
9	80-0-80	120-0-0	80-0-85	140-0-0	-
10	50-0-80	100-0-0	70-0-80	120-10-10	re-dislocation

* Complication: broken of transradiocapitella pin, re-dislocation

Table 3. Radiographic results

Pt. No.	Radiographic finding	Radiographic results	Age at Operation	Preop. Delay (mo)
1	no osteoarthritis change, no subluxation	good	8 yr	36 mo
2	no subluxation, hypertrophy of radial head, mild osteoarthritis change	fair	11 yr	36 mo
3	no osteoarthritis change, no subluxation	good	7 yr	24 mo
4	no osteoarthritis change, no subluxation	good	8 yr	36 mo
5	mild osteoarthritis change, no subluxation	fair	6 yr	36 mo
6	no osteoarthritis change, no subluxation	good	9 yr	24 mo
7	no osteoarthritis change, no subluxation	good	9 yr	8 mo
8	no osteoarthritis change, no subluxation	good	13 yr	60 mo
9	no osteoarthritis change, no subluxation	good	7 yr	8 mo
10	mild osteoarthritis change, no subluxation	fair	13 yr	120 mo

of open reduction was 8.7 years for the patients who were rated as good and 10 years for those who were rated as fair. The relationships between the clinical data at the time of open reduction and the radiographic results at the time of follow-up are shown in (Table 3). Reduction of the radial head was maintained with osteoarthritic change in two patients who were less than twelve years old at the time of the operation. No patient who has interval of less than three years between the injury and the operation had radial head with osteoarthritic change. When the age at the time of open reduction was twelve years or more and the interval to open reduction was longer than three years, three had osteoarthritic changes of radiohumeral joint. One patient (No. 8) has good radiologic outcome even the preoperative delay was 60 months and the age at surgery was 13 years old.

Discussion

Patient age at the time of open reduction and the interval between a Monteggia fracture and surgery, remain controversial. With respect to age, Wilkins proposed that reconstruction should be performed only in patients under 12 years old⁽¹¹⁾. Hirayama et al⁽⁵⁾ and Stoll et al⁽⁶⁾ recommended open reduction for children less than ten years of age; however, they did not recommend surgery when radial head deformity, flattening of the capitellum, or valgus deformity of the radial neck was present. Horii et al⁽¹²⁾ reported that open reduction was beneficial for patients younger than twelve years of age without radial head deformity and this finding was confirmed by Wang and Chang⁽¹³⁾. The present results also show that the older the child at the time of open reduction and the longer the interval from injury to open reduction, the lower the likelihood

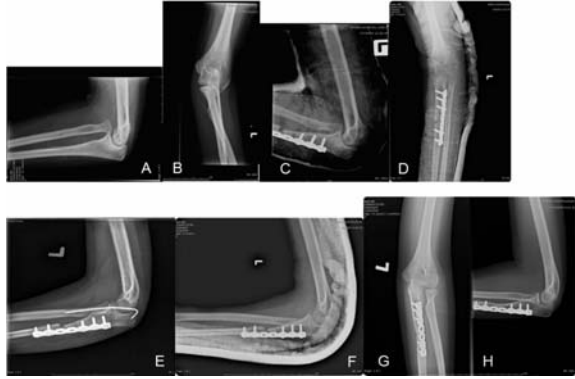


Fig. 2 (A, B) Thirteen years old girl with Monteggia Bado type 1, interval from injury to operation is ten years, (C, D) immediate dislocation post-operatively (E) after closed reduction with transradiocapitellar pin radial head was reduced, (F) remove transradiocapitellar pin at 6 weeks, (G, H) at follow-up 24 months with no subluxation, osteoarthritis of radiohumeral joint was observed (Patient No. 10)

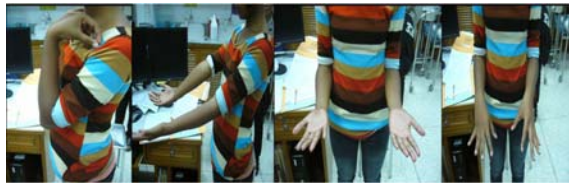

Fig. 3 Clinical and range of motion of chronic Monteggia left elbow 24 months after surgery (Patient No. 10)

of a good result but in our series has one patient (No. 8) has 13 years old at the time of surgery and preoperative delay for 60 months shows good result with no osteoarthritis change. No patient with an age of less than twelve years at the time of open reduction with an interval of less than three years between the injury and open reduction showed subluxation of the radial head or osteoarthritic changes of the radiohumeral joint.

With regard to the interval between the injury and open reduction, the findings have varied among reports, with Wang and Chang⁽¹³⁾ stating that the acceptable interval is three years, Stoll et al⁽⁸⁾ stating that it is four years and Best⁽¹⁴⁾ stating that it is six years. However, none of those authors provided statistical evidence to support their indications. The present results show that six patients who has preoperative delay more than 36 months, only three

patients (pt. no. 2, 5, 10) have osteoarthritis change. The present results cannot concluded that patient age more than 12 years old or preoperative delay more than three years should not performed surgery until the authors has more statistical evident to support the indications. However, even if the patient does not meet the criteria, open reduction for a missed Monteggia fracture-dislocation is still advisable because almost all clinical outcomes of our patients were improved after surgery. If open reduction is to be performed for such patients, however, it should be informed about the high risk of subluxation of the radial head and osteoarthritic changes.

Regarding the surgical procedures for reconstruction of the annular ligament, several methods have been proposed, such as using a free palmaris longus tendon, pedicled forearm fascia, fascia of the triceps and the remnant of the annular ligament. Kalamchi⁽¹⁵⁾ also used the torn annular ligament to stabilize the radial head in two cases. Seel and Peterson⁽¹⁶⁾ found that the annular ligament was impinged between the radial head and the humerus in all seven of their cases and they used it for reconstruction in five. Reconstruction of the annular ligament was thought to result in limit rotation of the forearm if it is not properly tensioned⁽¹⁷⁾. Limit rotation, especially in pronation, have been reported after annular ligament reconstruction. The authors used annular ligament reconstruction with triceps fascia in all patients because most of the patients have preoperative delay more than 24 months and intraoperatively the remnant of annular ligament was not healthy enough to use for reconstruction, but in some case, the authors can use annular ligament to augment the tricep fascia. Postoperative range of motion still has some limitation of pronation but improve compared to preoperative and all have excellent MEPI score.

Two types of ulna correction have been proposed, a simple correction^(18,19) and an angular overcorrective osteotomy⁽⁵⁾ fixed with plate or intramedullary wire. Hirayama⁽⁵⁾ performed overcorrective osteotomy with lengthening. Inoue and Shionoya⁽⁴⁾ compared simple correction versus overcorrection and annular ligament reconstruction and found better results on second group. The concept of ulnar osteotomy is to tightened the interosseous membrane sufficiently to keep the radial head in a correct anatomical position. To preserve all of the interosseous membrane and to use its tension to pull the radial head posteriorly. Proximal ulnar osteotomy has the advantages of having an unnoticeable posterior

curvature and avoiding restriction of forearm rotation because the tension in the whole interosseous membrane remains constant. In our series the authors done ulna osteotomy with posterior bending and lengthening technique and fixed with six to eight holes plate and screws, this technique not required bone graft and no nonunion or delayed union in the present series. Range of motion and MEPI score improve compare to preoperative.

The present study had several limitations. First, for the evaluation of the condition of the radial head, the authors measured its size and shape with use of conventional radiographs. Magnetic resonance imaging currently has the ability to evaluate the size, configuration of the articular surface and quality of articular cartilage of the radial head and it can also display the condition of the radial notch of the ulna.

In the future, open reduction should be based on the preoperative anatomical or functional status of the radial head, the radial notch of the ulna and the remnant of the annular ligament as detected with magnetic resonance imaging or other advance imaging techniques. Second, the authors used the MEPI as a functional score although it has not been validated for use in studies of children.

From the viewpoint of performing an open radial head reduction with a posterior bending elongation ulnar osteotomy combined with an annular ligament reconstruction, the authors considered these two methods to be similar enough to be analyzed as one group. Last, although multivariate analysis with logistic regression is necessary to identify significant risk factors related to outcome, the number of patients in the present study was insufficiently to be analyzed in this way. Therefore, the authors could not prove that patients who undergo the operation within three years after the injury or before the age of twelve years have a significantly higher chance of obtaining a good result. Despite such limitations, our data support that, if open reduction for the treatment of a chronic Monteggia fracture dislocation is performed before the patient is twelve years of age or within three years after the injury, good long-term clinical and radiographic outcomes should be expected.

Technique of posterior bending elongation with Z plasty technique combined with annular ligament reconstruction leads to stable reduction of the radial head, safe, no need for bone grafting and no delay union in the present series and the authors support this technique to treat chronic Monteggia fracture dislocation.

Potential conflict of interest

None.

References

1. Rodgers WB, Waters PM, Hall JE. Chronic Monteggia lesions in children. Complications and results of reconstruction. *J Bone Joint Surg Am* 1996; 78: 1322-9.
2. Lloyd-Roberts GC, Bucknill TM. Anterior dislocation of the radial head in children: aetiology, natural history and management. *J Bone Joint Surg Br* 1977; 59-B: 402-7.
3. Holst-Nielsen F, Jensen V. Tardy posterior interosseous nerve palsy as a result of an unreduced radial head dislocation in Monteggia fractures: a report of two cases. *J Hand Surg Am* 1984; 9: 572-5.
4. Inoue G, Shionoya K. Corrective ulnar osteotomy for malunited anterior Monteggia lesions in children. 12 patients followed for 1-12 years. *Acta Orthop Scand* 1998; 69: 73-6.
5. Hirayama T, Takemitsu Y, Yagihara K, Mikita A. Operation for chronic dislocation of the radial head in children. Reduction by osteotomy of the ulna. *J Bone Joint Surg Br* 1987; 69: 639-42.
6. Chen WS. Late neuropathy in chronic dislocation of the radial head. Report of two cases. *Acta Orthop Scand* 1992; 63: 343-4.
7. Miura T. Congenital dislocation of the radial head. *J Hand Surg Br* 1990; 15: 477-81.
8. Stoll TM, Willis RB, Paterson DC. Treatment of the missed Monteggia fracture in the child. *J Bone Joint Surg Br* 1992; 74: 436-40.
9. Bell Tawse AJ. The treatment of malunited anterior Monteggia fractures in children. *J Bone Joint Surg Br* 1965; 47: 718-23.
10. Bado JL. The Monteggia lesion. *Clin Orthop Relat Res* 1967; 50: 71-86.
11. Wilkins KE. Changes in the management of monteggia fractures. *J Pediatr Orthop* 2002; 22: 548-54.
12. Horii E, Nakamura R, Koh S, Inagaki H, Yajima H, Nakao E. Surgical treatment for chronic radial head dislocation. *J Bone Joint Surg Am* 2002; 84-A: 1183-8.
13. Wang MN, Chang WN. Chronic posttraumatic anterior dislocation of the radial head in children: thirteen cases treated by open reduction, ulnar osteotomy, and annular ligament reconstruction through a Boyd incision. *J Orthop Trauma* 2006; 20: 1-5.

14. Best TN. Management of old unreduced Monteggia fracture dislocations of the elbow in children. J Pediatr Orthop 1994; 14: 193-9.
15. Kalamchi A. Monteggia fracture-dislocation in children. Late treatment in two cases. J Bone Joint Surg Am 1986; 68: 615-9.
16. Seel MJ, Peterson HA. Management of chronic posttraumatic radial head dislocation in children. J Pediatr Orthop 1999; 19: 306-12.
17. De Boeck H. Treatment of chronic isolated radial head dislocation in children. Clin Orthop Relat Res 2000; 215-9.
18. Kim HT, Park BG, Suh JT, Yoo CI. Chronic radial head dislocation in children, Part 2: results of open treatment and factors affecting final outcome. J Pediatr Orthop 2002; 22: 591-7.
19. Kim HT, Conjares JN, Suh JT, Yoo CI. Chronic radial head dislocation in children, Part 1: pathologic changes preventing stable reduction and surgical correction. J Pediatr Orthop 2002; 22: 583-90.

การรักษาภาวะกระดูกหักข้อเคลื่อนของแขนชนิดมอนเทจเจียที่มารับการรักษาซ้ำ ด้วยการผ่าตัดเปิดจัดหัวกระดูกเรเดียสให้เข้าที่, ตัดกระดูกอัลนาโดยเทคนิคการเพิ่มความยาวรูปตัวแชดและการสร้างเอ็นแอนนูลาใหม่

พีระจิตร เอี่ยมโสภณา, กมลพร แก้วพรสวรรค์

ภูมิหลัง: การศึกษานี้มีจุดประสงค์เพื่อทำการศึกษาผลของการรักษาภาวะกระดูกหักข้อเคลื่อนของแขนชนิดมอนเทจเจียที่มารับการรักษาซ้ำด้วยวิธีผ่าตัดเปิดจัดหัวกระดูกเรเดียสให้เข้าที่, ตัดกระดูกอัลนาโดยเทคนิคการเพิ่มความยาวรูปตัวแชดและการสร้างเอ็นแอนนูลาใหม่ โดยวัดผลการรักษาจากการตรวจร่างกายและเอกซเรย์

วัสดุและวิธีการ: ทำการศึกษาผลการรักษาโดยการซักประวัติ, ตรวจร่างกายและวิเคราะห์ผลเอกซเรย์จากผู้ป่วย 10 คน ประกอบด้วยชาย 7 คน และหญิง 3 คน, อายุเฉลี่ย 9 ปี ในวันที่ทำการผ่าตัด ผู้ป่วยจะได้รับการผ่าตัดด้วยวิธีจัดหัวกระดูกเรเดียสให้เข้าที่, ตัดกระดูกอัลนาโดยเทคนิคการเพิ่มความยาวโดยตัดเป็นรูปตัวแชด และสร้างเอ็นแอนนูลาใหม่ ผลการรักษาทั้งจากการตรวจร่างกายและเอกซเรย์ได้ทำการตรวจติดตามเฉลี่ย 38 เดือน

ผลการศึกษา: วัดผลการรักษาโดยวัดการทำงานของข้อศอกด้วยวิธี Mayo Elbow Performance Index (MEPI) เมื่อผู้ป่วยมาทำการตรวจติดตาม โดยได้คะแนนตั้งแต่ 95 ถึง 100 คะแนน ซึ่งอยู่ในเกณฑ์ดีมาก ระดับคะแนนเฉลี่ยอยู่ที่ 99.5 คะแนน ไม่พบว่ามีกระดูกเคลื่อนหลุดของหัวกระดูกเรเดียสหลังการผ่าตัด พบลักษณะของข้อเสื่อมในผู้ป่วย 3 ราย การประเมินทางเอกซเรย์พบว่า มีผู้ป่วย 7 คน ได้ผลดี 3 คน ได้ผลปานกลางและไม่พบว่ามีผู้ป่วยที่ได้ผลไม่ดีจากการประเมินทางเอกซเรย์ ในผู้ป่วยที่ได้ผลปานกลางพบว่าเป็นผู้ป่วยที่มาผ่าตัดหลังจากเกิดอุบัติเหตุมากกว่า 3 ปีขึ้นไปและผู้ป่วยสองคนที่ได้ผลปานกลางมารับการรักษาที่อายุ 11 ปี และ 13 ปีตามลำดับ

สรุป: ในผู้ป่วยที่ได้รับการผ่าตัดก่อนอายุ 12 ปี หรือได้รับการผ่าตัดภายใน 3 ปีหลังเกิดอุบัติเหตุได้ผลการรักษาที่ดี การรักษาด้วยวิธีผ่าตัดเปิดและจัดหัวกระดูกเรเดียสให้เข้าที่, ตัดกระดูกอัลนาโดยเทคนิคการเพิ่มความยาว โดยตัดเป็นรูปตัวแชดและการสร้างเอ็นแอนนูลาใหม่ ในภาวะกระดูกข้อเคลื่อนของแขนชนิดมอนเทจเจียที่มารับการรักษาซ้ำมีความปลอดภัยได้ผลดี และไม่มีความจำเป็นต้องใช้การปลูกกระดูกร่วมด้วย และไม่มีรายงานภาวะกระดูกติดเชื้อหรือกระดูกไม่ติด