

Anatomical Landmark to Locate the Ankle Center for Determination of the Mechanical Axis of the Lower Extremity in Thai Subjects

Tanutum Pikulkaew MD*,
Chaturong Pornrattanamaneeuwong MD*, Keerati Chareancholvanich MD*

*Department of Orthopaedic Surgery, Faculty of Medicine, Siriraj Hospital, Mahidol University, Bangkok, Thailand

Objective: The present study was carried out to determine the relationship of true ankle center, the extreme-midpoint of the ankle and tibial axis for identification of lower limb alignment in Thai subjects.

Material and Method: There were 26 volunteers in our study, 13 male and 13 female with their ages ranged between 20 and 40 years. All underwent plain true antero-posterior radiograph of their both ankle joint including distal one-third of their tibiae, which were controlled by a special splint. Three variables were made on the radiograph including one line and two points. The line was the axis of the distal tibia, which was performed by the use of connecting of center points of tibial diaphysis and metaphysis. The first point was the center of talar dome at the subchondral bone or the true ankle center and the second point, the anatomical ankle center or the extreme-midpoint of the ankle, which was the mid-point between the lateral most rim of lateral malleolus and the medial most rim of medial malleolus. Then the distances between the tibial axial line and these two points were measured by the use of perpendicular lines between the tibial axial line and those points.

Results: The center of the talar dome was in the distal tibial axis in all radiographs. The anatomical ankle center or the extreme-midpoint of the ankle located lateral to the axis with an average distance of 2.1 ± 1.1 mm. This finding did not depend on our volunteers' biodata.

Conclusion: To identify the lower end point of mechanical axis of the lower extremity in Thai subjects, the true ankle center located approximately 2 mm medial to the extreme-midpoint, which commonly used as anatomic landmark of the ankle center.

Keywords: Landmark, Ankle center, Extreme midpoint, Mechanical axis, Thai

J Med Assoc Thai 2012; 95 (Suppl. 9): S1-S5

Full text. e-Journal: <http://jmat.mat.or.th>

Accurate coronal alignment of the lower limb is important for the success of several orthopedic procedures, especially in reconstructive surgery around the knee. Correction of the mechanical axis, which passes through the lateral compartment of the knee, is the principle of the high tibial osteotomy procedure for the treatment of varus osteoarthritic knee⁽¹⁻³⁾. For total knee arthroplasty (TKA), restoration of the neutral mechanical axis has been proposed to be associated with good clinical outcomes^(4,5). Malalignment after these procedures has been reported to correlate with suboptimal post-operative outcomes and higher complication and failure rates⁽⁶⁻⁸⁾.

The center of the ankle, which is usually

defined as the center of the proximal articular surface of the talar dome, is the crucial point for the identification of the distal end of the mechanical axis. Although several anatomic methods to determine the ankle center have been published⁽⁹⁻¹¹⁾, the midpoint between the most medial and most lateral rims of the malleoli, so-called the extreme-midpoint, was commonly used and proved to be the most accurate and precise method⁽¹²⁾. However, a lateral error of 4.5 ± 4.1 mm was reported from using this point to identify the center of the ankle. This error might be varied by the structure of the body or race. Therefore, the purpose of the present study was to find out the relationship between the ankle center and the extreme-midpoint in Thais for our clinical use.

Correspondence to:

Chareancholvanich K, Department of Orthopaedic Surgery, Faculty of Medicine, Siriraj Hospital, Mahidol University, Bangkok 10700, Thailand.
Phone: 0-2419-7968, Fax: 0-2412-8172
E-mail: sikcr@mahidol.ac.th

Material and Method

The present study was carried out between July and August 2009. Twenty-six healthy Thai volunteers, 13 male and 13 female, with their ages ranged between 20 and 40 years were included in the present

study. Exclusion criteria were 1) patients who had ankle pain, 2) patients who had a history of ankle injury or disorders, 3) patients who had previous ankle surgery and 4) patients who had osteoarthritic ankle. The present study was approved by the Ethics Committee of Siriraj Hospital.

A special designed plastic-wooden splint was applied to the volunteer ankle up to their knees. The splint could fix the volunteer's ankle in neutral position with the knee at full extension. Fixation was reinforced by the use of 2 Velcro-straps, at the thigh and leg. While the volunteer was in supine position, the prepared ankle was underwent a digital plain radiography in antero-posterior view with a x-ray beam centered and perpendicular to the ankle joint (Fig. 1). The distance between the x-ray tube and the cassette was 0.6 meters. Radiographic accuracy was defined when the ankle joint line was perpendicular to the anatomical axis of the distal tibia and the tibiotalar articular surfaces were parallel.

The obtained digital films were interpreted by the use of measurement tools of the patient archiving and communication system (PACS). Three radiographic

landmarks were created from these radiographs, including one line and two points. First was the axis of distal tibia, which connecting between midpoints of tibial diaphysis and metaphysis. Second was the true center of the ankle, which identified as the center of the talus at the level of subchondral bone⁽¹³⁾. And the third was the anatomical center of the ankle or the extreme-midpoint, which defined as the midpoint of a line connecting the medial and lateral most rims of the malleoli (Fig. 2). Then, the distances between the distal tibial axis and these two points were measured in

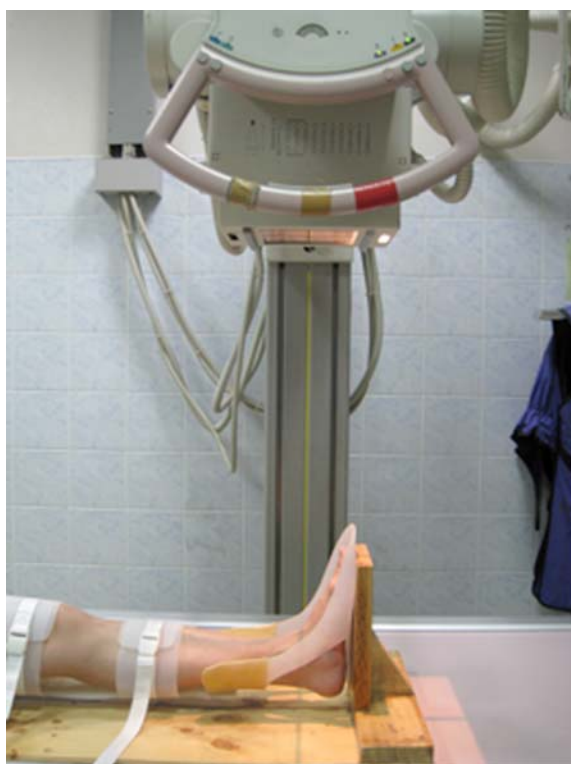

Fig. 1 The picture demonstrates the radiographic method to obtain a supine anteroposterior ankle film with the specially designed splint

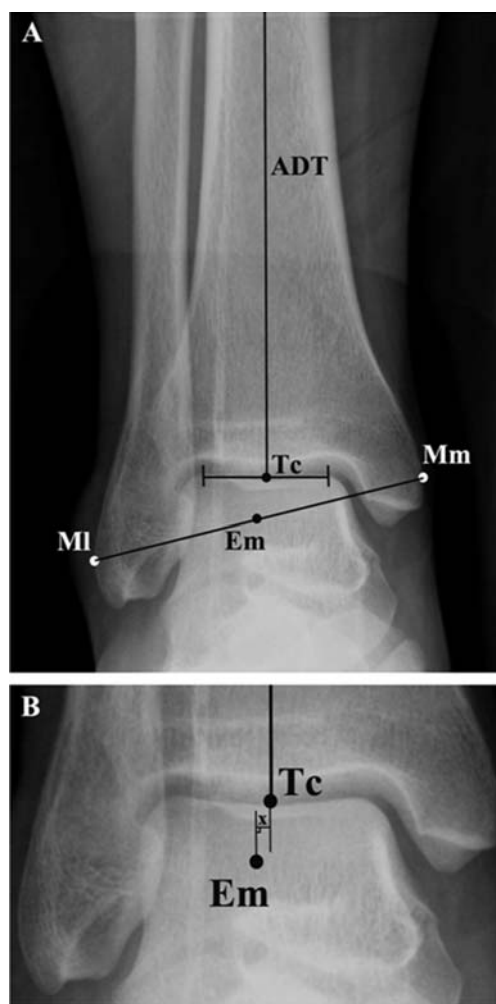


Fig. 2 (A) The ankle radiograph shows the identification of the anatomical axis of the distal tibia (ADT), the center of the talus (Tc) and the extreme-midpoint [Em: the midpoint of a line connecting the most medial (Mm) and most lateral (Ml) aspects of the malleoli] (B) The zoom-in image demonstrates the measurement of the distance deviation (X)

perpendicular plane to the distal tibial axis. The distance deviations of the extreme-midpoint from the center of the talus were calculated and set as positive if lateral deviation of extreme-midpoint was present and as negative if medial deviation of extreme-midpoint was present (Fig. 2).

The data were analyzed using the SPSS statistical software, version 13.0. Quantitative data are expressed as the mean \pm SD and the differences were analyzed using the Student's t-test. Pearson's correlation coefficient was used to determine the correlation between the distance deviations of two points and the subjects' demographics. P-values less than 0.05 were regarded as statistically significant. The intra- and inter-observer reliability for the two investigators in measuring the radiographic outcome was expressed as the intraclass correlation coefficients (ICCs).

Results

The mean age of the subjects was 29.4 ± 4.2 years (range 23 to 39 years). On average, the female subjects were slightly older than the male subjects ($p = 0.75$). There were significant differences in height and weight between the genders but the calculated body mass indexes (BMI) were not significantly different ($p = 0.696$). The subjects' biodata are summarized in the Table 1.

Based on the radiographic evaluation, the true center of the ankle located along the axial line of the distal tibia in all films. 94.2% of the extreme-midpoint located lateral to the true center of the ankle and the remaining 5.8% was in the same point. The mean distance deviation between these two points was 2.1 ± 1.1 mm (range 0.0 to 4.8 mm). In male volunteers, the mean lateral deviation of the extreme midpoint from the tibial axial line was 1.9 ± 1.2 mm, whereas the mean lateral deviation of 2.3 ± 1.0 mm was found in female volunteers. However, there was no significant difference between the groups ($p = 0.250$). Pearson's correlation coefficients did not demonstrate any correlations

between the distance deviations and the subjects' characteristics ($p > 0.05$). Furthermore, for the reliability of the radiographic measurements, ICCs of more than 0.95 were expressed as either intra- or inter-rater agreement.

Discussion

The center of the ankle is one of the most important referent points for determining the overall alignment of the lower limb, especially in the coronal plane. In corrective osteotomy around the knee or in conventional TKA, a rigid or traditional mechanically guided rod is used to achieve the desired post-operative alignment. However, several techniques using the anatomical landmarks to identify the ankle center have been proposed⁽⁹⁻¹¹⁾. With the most accurate and precise anatomic method, the extreme-midpoint, an error of 4.5 ± 4.1 mm was still observed⁽¹²⁾. The authors therefore aimed to determine the relationship of true ankle center, the extreme-midpoint and tibial axis in Thai subjects.

From the present study, the extreme-midpoint located lateral to the true ankle center and the distal tibial axis with a mean distance of 2.1 ± 1.1 mm which was significantly different from the previous report⁽¹²⁾. In addition to the limitation of sample size, the extreme-midpoint of that study was located by digitizing the anatomic landmarks via the computer-assisted navigation system and represented the midpoint of the actual transmalleolar axis. Compared to our study, with a greater sample size, the authors determined the extreme-midpoint in the coronal plane only that could be easily applied in traditional reconstructive knee surgery. However, there are some limitations in the present study. The authors focused only on the coronal plane. In the sagittal plane, the center of the ankle determined the posterior tibial slope, which could affect the outcomes or tibiofemoral kinematics after reconstructive knee surgery⁽¹⁴⁻¹⁶⁾. In addition, the clinical trial using our method should be carried out to confirm its reliability.

In conclusion, the true ankle center and the

Table 1. The subjects' characteristics

Characteristics	Female (n = 13)	Male (n = 13)	p-value
Age (yrs)	30.9 ± 5.1	27.9 ± 2.5	0.750
Weight (kgs)	57.5 ± 12.5	73.1 ± 8.6	0.001
Height (cms)	156.7 ± 6.8	174.2 ± 5.9	< 0.001
BMI (kg/m ²)	23.5 ± 5.1	24.1 ± 2.9	0.696

All values are presented as the Mean \pm Standard Deviation. BMI = Body mass index

tibial axis of Thai subjects were found to be located medially to the extreme-midpoint by approximately 2 mm.

Potential conflicts of interest

None.

References

1. Paley D. Realignment for mono-compartment osteoarthritis of the knee. In: Paley D, Herzenberg JE, editors. Principles of deformity correction. Vol.1. New York: Springer-Verlag; 2002: 479-85.
2. Dugdale TW, Noyes FR, Styer D. Preoperative planning for high tibial osteotomy. The effect of lateral tibiofemoral separation and tibiofemoral length. *Clin Orthop Relat Res* 1992; (274): 248-64.
3. Fujisawa Y, Masuhara K, Shiomi S. The effect of high tibial osteotomy on osteoarthritis of the knee. An arthroscopic study of 54 knee joints. *Orthop Clin North Am* 1979; 10: 585-608.
4. Lotke PA, Ecker ML. Influence of positioning of prosthesis in total knee replacement. *J Bone Joint Surg Am* 1977; 59: 77-9.
5. Ritter MA, Faris PM, Keating EM, Meding JB. Postoperative alignment of total knee replacement. Its effect on survival. *Clin Orthop Relat Res* 1994; 153-6.
6. Jeffery RS, Morris RW, Denham RA. Coronal alignment after total knee replacement. *J Bone Joint Surg Br* 1991; 73: 709-14.
7. Sprenger TR, Doerzbacher JF. Tibial osteotomy for the treatment of varus gonarthrosis. Survival and failure analysis to twenty-two years. *J Bone Joint Surg Am* 2003; 85-A: 469-74.
8. Insall JN, Joseph DM, Msika C. High tibial osteotomy for varus gonarthrosis. A long-term follow-up study. *J Bone Joint Surg Am* 1984; 66: 1040-8.
9. Inkpen KB, Hodgson AJ. Accuracy and repeatability of joint center location in computer-assisted knee surgery. In: Taylor C, Colchester A, editors. Lecture notes in computer science. Vol. 1679: Medical image computing and computer-assisted intervention-MICCAI'99: Second International Conference Cambridge, UK, September 19-22, 1999 Proceedings. New York: Springer-Verlag; 1999:1072-9.
10. Krackow KA, Bayers-Thering M, Phillips MJ, Bayers-Thering M, Mihalko WM. A new technique for determining proper mechanical axis alignment during total knee arthroplasty: progress toward computer-assisted TKA. *Orthopedics* 1999; 22: 698-702.
11. Nofrini L, Slomczykowski M, Iacono F, Marcacci M. Evaluation of accuracy in ankle center location for tibial mechanical axis identification. *J Invest Surg* 2004; 17: 23-9.
12. Siston RA, Daub AC, Giori NJ, Goodman SB, Delp SL. Evaluation of methods that locate the center of the ankle for computer-assisted total knee arthroplasty. *Clin Orthop Relat Res* 2005; 439: 129-35.
13. Tang WM, Zhu YH, Chiu KY. Axial alignment of the lower extremity in Chinese adults. *J Bone Joint Surg Am* 2000; 82-A: 1603-8.
14. Suero EM, Citak M, Cross MB, Bosscher MR, Ranawat AS, Pearle AD. Effects of tibial slope changes in the stability of fixed bearing medial unicompartmental arthroplasty in anterior cruciate ligament deficient knees. *Knee* 2011 Aug 10. [Epub ahead of print]. doi: <http://dx.doi.org/10.1016/j.knee.2011.07.004>
15. Asada S, Akagi M, Mori S, Matsushita T, Hashimoto K, Hamanishi C. Increase in posterior tibial slope would result in correction loss in frontal plane after medial open-wedge high tibial osteotomy. *Knee Surg Sports Traumatol Arthrosc* 2012; 20: 571-8.
16. Piazza SJ, Delp SL, Stulberg SD, Stern SH. Posterior tilting of the tibial component decreases femoral rollback in posterior-substituting knee replacement: a computer simulation study. *J Orthop Res* 1998; 16: 264-70.

จุดสังเกตทางกายวิภาคเพื่อระบุตำแหน่งจุดศูนย์กลางของข้อเท้าในคนไทย

ทฤษฎีธรรม พิภูลแก้ว, จตุรงค์ พรรัตน์มณีวงศ์, กิรติ เจริญชลวานิช

วัตถุประสงค์: เพื่อศึกษาหาความสัมพันธ์ของจุดศูนย์กลางของข้อเท้า, จุด extreme-midpoint และแกนของกระดูกหน้าแข้งในคนไทย

วัสดุและวิธีการ: นำอาสาสมัครจำนวน 26 คน (ชาย 13 คน และหญิง 13 คน) ที่มีอายุตั้งแต่ 20 - 40 ปี มาถ่ายภาพรังสีข้อเท้าทั้ง 2 ข้างในแนวหน้า-หลัง โดยควบคุมการจัดตำแหน่งของข้อเท้าด้วยอุปกรณ์ตามขา ชนิดพิเศษ นำภาพถ่ายรังสีที่ได้มาทำการระบุตำแหน่งแกนของกระดูกหน้าแข้ง, จุดศูนย์กลางข้อเท้าหรือ จุดศูนย์กลางของกระดูกทาลัส และจุด extreme-midpoint ซึ่งเป็นจุดกึ่งกลางระหว่างขอบนอกสุดของ medial และ lateral malleolus หลังจากนั้นจะทำการวัดระยะห่างระหว่าง 2 จุดดังกล่าวในแนวตั้งฉากกับแกนกระดูกหน้าแข้ง

ผลการศึกษา: พบว่าจุดศูนย์กลางของกระดูกทาลัสในอาสาสมัครทุกรายตั้งอยู่ในแนวเดียวกับแกนกระดูกหน้าแข้ง และจุดสังเกตทางกายวิภาคที่ใช้หรือ extreme-midpoint นั้นตั้งอยู่ด้านนอก (lateral) ต่อแกนกระดูกหน้าแข้ง โดยมีระยะเฉลี่ยประมาณ 2.1 ± 1.1 มม. นอกจากนี้การศึกษานี้ไม่พบความสัมพันธ์ของระยะห่าง ที่ได้กับ อายุ, น้ำหนัก, ส่วนสูง หรือ ดัชนีมวลกายของผู้เข้าร่วมการศึกษา

สรุป: ในการกำหนด mechanical axis ของรยางค์ส่วนล่างในคนไทยนั้น จุดศูนย์กลางของข้อเท้าจะตั้งอยู่ด้านใน (medial) ต่อ extreme-midpoint ประมาณ 2 มม. ซึ่ง extreme midpoint นี้เป็นจุดสังเกตทางกายวิภาคที่นิยมใช้เพื่อระบุตำแหน่งจุดศูนย์กลางของข้อเท้า
