

# Surgical Outcome of the Non-Shunt Carotid Endarterectomy

Anusak Liengudom MD\*,  
Wuttipong Tirakotai MD\*, Chaiyapol Vuttiopas MD\*

\* Department of Neurosurgery, Prasat Neurological Institute, Bangkok, Thailand

**Background and Objective:** Nearly 60 years after the advent of carotid endarterectomy (CEA), controversy continues regarding the necessity of an indwelling shunt during carotid reconstruction. Reasonable arguments have been made for monitoring-dependent shunting, and remarks can be made in favor of non-shunt procedure. Based on the results of several studies, most strokes after CEA are thromboembolic and result from technical failures e.g. residual plaque fragments, and stenosis during arterial repair. The objective of the present study is to present the details and results of CEA without an intraluminal shunt.

**Material and Method:** A retrospective study was performed to determine the efficacy of non-shunt CEA. During a four-year period, 25 patients, ranging from 49 to 81 years underwent 25 consecutive CEA.

**Results:** The clinical presentations were previous minor stroke in 12, reversible ischemic neurological deficit in eight, and TIA in five. There was no early post-operative mortality. Neither carotid clamp time nor the presence of contralateral disease correlated with the occurrence of post-operative stroke.

**Conclusion:** Although the authors' experience may be limited in terms of numbers of patients, satisfactory results in carotid reconstruction could be obtained using safe performance of CEA without intraluminal shunt.

**Keywords:** Carotid stenosis, Minor stroke, Non-shunt carotid endarterectomy, Reversible ischemic neurological deficit, Transient ischemic attack

*J Med Assoc Thai* 2012; 95 (6): 782-9

Full text. e-Journal: <http://jmat.mat.or.th>

The value of carotid endarterectomy (CEA) in stroke prevention for symptomatic patients with a high-grade (> 70%) internal carotid artery stenosis has been well established<sup>(1-5)</sup>. To obtain the successful operation, the carotid lesion should be an operable one, and the risk of perioperative complication must be very low, at least below 3% for asymptomatic persons, 5% for those with transient ischemic attack, and 7% for patients with an ischemic stroke<sup>(6,7)</sup>. Controversy over CEA technique is mainly centered in usage of indwelling artery shunt or intraluminal shunt during the temporary occlusion of the ipsilateral internal carotid artery. Opinions range from those who never employ shunts, or selective shunts to those who shunt routinely. Several large series presented good surgical outcome without shunt placement under any circumstances, although most of the papers were published in the 1990s<sup>(8-14)</sup>. Certainly, the existence of post-operative stroke cannot be denied. The purposes

of this report are to review the authors' technique of non-intraluminal shunt placement and to ensure the safety of non-shunt CEA.

## Material and Method

### Patient population

The authors retrospectively reviewed the consecutive non-shunt CEA cases with emphasis on pre-operative evaluation of the patients, modification of intra-operative management and post-operative outcome. The present study group included 25 patients consecutively admitted to the Department of Neurosurgery, Prasat Neurological Institute, Bangkok between March 2007 and March 2011. The institutional review board approved this retrospective study of patient data.

### Pre-operative investigation

All patients with a history of transient ischemic attack (TIA), reversible ischemic neurological deficit (RIND), and previous minor stroke underwent CT brain scan to rule out intracranial hemorrhage. Carotid duplex ultrasonography was undertaken and followed by magnetic resonance angiography (MRA) to assess the carotid bifurcation disease and the degree

### Correspondence to:

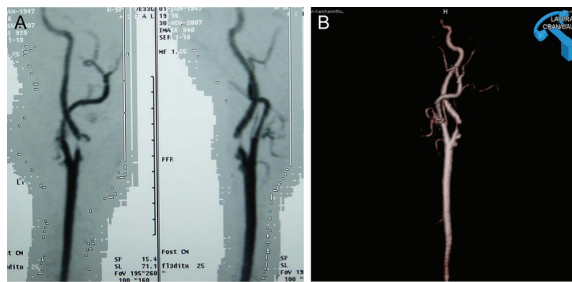
Liengudom A, Department of Neurosurgery, Prasat Neurological Institute, Bangkok, Thailand 312 Rajavithi Rd, Bangkok 10400, Thailand.

Phone: 0-2354-7075 ext. 2399, Fax: 0-2354-7084

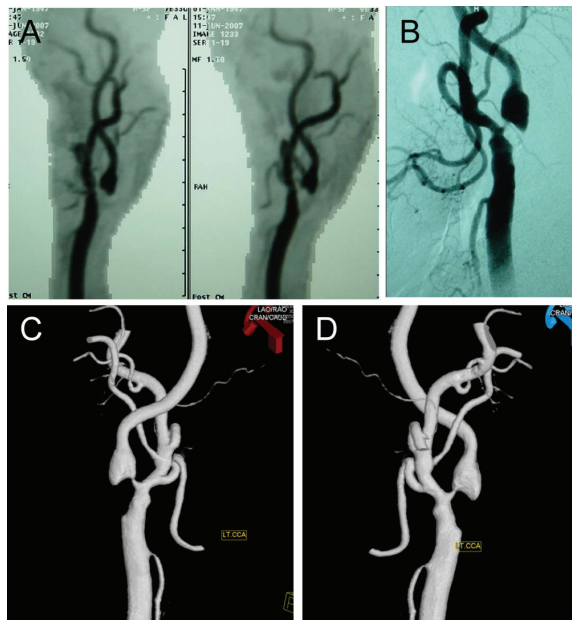
E-mail: [leingudom\\_a@hotmail.com](mailto:leingudom_a@hotmail.com)

of stenosis (Fig. 1). Conventional angiography was performed only in some cases, to delineate the actual stenosis segment (Fig. 2), or to evaluate the carotid disease and status of the collateral circulation. The rest of the patients were operated on based solely on the combination of duplex and magnetic resonance angiography.

The patients were scheduled for CEA when the neurological condition was stable with intact sensorium and normal level of consciousness.



**Fig. 1** A) Post contrasted magnetic resonance angiography (MRA) revealing severe stenosis of the internal carotid artery. B) Three-dimensional (3D) reconstruction image of MRA delineating the stenosis part, 360 degree evaluation is another advantage of 3D picture



**Fig. 2** A) Conventional post contrasted MRA demonstrating an overestimated stenosis portion. B) Angiography showing the proper stenosis portion. C-D) Three-dimensional angiography demonstrating 360 degree stenosis portion

## Operative management

### Anesthesia

The authors prefer doing CEA under general anesthesia. Cerebral protection was performed using thiopental sodium before temporary occlusion of the carotid artery. The single dose of 5000 units' heparin was given intravenously starting prior to the temporary occlusion of internal the carotid artery; usually it takes about 10 minutes before occluding the carotid artery. The blood pressure was also raised 10% above the pre-operative level with the aims not only to promote collateral circulation but also to avoid the ischemic complication during carotid clamping.

### Surgical procedure: carotid endarterectomy

The patient was in supine position. Head was placed on a gelatin headrest. The neck was slightly extended and turned to the contralateral side. The head was above the level of the heart to promote venous drainage.

The incision was outlined along the anterior border of the sternocleidomastoid muscle, not to injure the parotid gland and superficial mandibular branches of the facial nerve.

The incision was carried down through the platysma along the anterior border of the sternocleidomastoid muscle. Multiple stayed-sutures with rubber bands were used to maximize the adequate exposure instead of using a self-retaining retractor. During this stage of dissection multiple stayed-sutures were used to retract the internal jugular vein laterally and tracheal muscle medially. With this maneuver, the carotid sheath became visible and maintained its exposure.

The dissection of the carotid bifurcation and proximal internal carotid artery must be gently performed to avoid disturbing the embolic material along the atherosclerotic plaque. The end of the dissection was the complete exposure of the external carotid artery and the superior thyroid artery. Vascular loops were placed around the common carotid artery, internal carotid artery, external carotid artery, and superior thyroid artery.

The microscope was brought into the field. During this stage of procedure, 5,000 units of heparin were administered intravenously. Bolus dose of 250 mg thiopental sodium followed by continuous infusion at the rate of 5 mg/kg /hour for cerebral protection was also initiated. Blood pressure was raised 10% above the base line before temporary closure of the carotid artery to enhance the cerebral blood flow. A temporary

aneurysm clip was placed on the internal carotid artery first, and an angled DeBakey clamp was placed on the common carotid artery. The additional aneurysm clips were placed on the external and superior thyroid artery. The arteriotomy was started at the common carotid artery and extended distally beyond the end of the atherosclerotic plaque in the internal carotid artery, the approximate length of the arteriotomy could be measured in the pre-operative angiogram. The closure of the arteriotomy would be easier, if the incision line was along the anterolateral side of the artery. The endarterectomy was begun with microdissector. The cleavage plane could be well illustrated under the microscope. The distal end of this plaque was divided. Afterward, circumferential dissection was continued proximally into the common carotid artery and proximal external carotid artery. Cleaning up of the remaining fragile atheromatous and tissue debris was also an important step to eliminate the potential dislodgement of embolic material. The distal lumen was also inspected for intimal flap. Tacking suture was undertaken if needed.

The closure started at the distal internal carotid artery using continuous 8-0 monofilament suture. Before tying suture lines, the distal clip of internal carotid artery was removed to allow back flow of blood washing out any debris and air. Subsequently, the distal clip was reapplied. The remaining blood was again washed out with heparinized saline before closing the arteriotomy. The temporary occlusion of external and common carotid artery was ceased to allow any remaining debris and air floating through the external carotid artery. Before opening the internal carotid artery, the blood pressure was lowered 10% below the base line, to prevent hyperperfusion syndrome. After complete hemostasis, the wound was closed in layers without reversing the heparin.

#### ***Post-operative management***

The patients were monitored in the ICU at least 24 hours for strict blood pressure control, high blood pressure is prohibited. If there were an additional post-operative neurological deficit, further investigation would be performed to identify its cause, whether it is the occlusion of the surgical site, embolic phenomenon or from intracerebral hemorrhage after the post-operative hyperperfusion stage.

#### **Results**

The present study included 25 patients with symptomatic carotid stenosis who were treated by

non-shunt CEA technique between March 2007 and March 2011 (20 men and 5 women) with a mean age of 65.48 years (range, 49 to 81 years). The most common underlying diseases were hypertension (23 of 25, 92%), followed by dyslipidemia (10 of 25, 40%) and diabetes mellitus (10 of 25, 40%). Only three cases (12%) suffered from all three underlying diseases and three individuals (12%) had ischemic heart disease. The majority of patients (12 of 25, 48%) presented with minor stroke with some degrees of recovery. Of the 12 cases of minor stroke, four patients (33%) had a history of previous stroke. Eight patients (32%) presented with RIND. Among eight patients of RIND, one (12.5%) patient had warning TIA and another one (12.5%) had a history of amourosis fugax. In contrast to the literature that most of the patients with symptomatic carotid artery stenosis who undergo CEA usually presented with TIA, only two patients presented with TIA and the other three patients presented with amourosis fugax. Patients' demographic and clinical presentations are summarized in Table 1.

The mean time interval between the initial clinical presentations and operation date was 74.12 days (range, 7 to 162 days). The mean occlusion time was 61.56 minutes (range, 30 to 105 minutes) (Table 2). The most common surgical related complications were perioperative transient weakness, which happened seven hours after surgery in one case and 24 hours post-operatively in two other cases. Two cases had full recovery in 24 hours and another one recovered in two weeks. There was permanent mild weakness in one case. All of the neurological complications occurred in cases of pre-operative minor stroke. Two cases of wound hematoma needed no surgical intervention. Complete obliteration of the ICA without neurological deficit was found in one case (Table 3).

The gross surgical findings could be classified into four components, which were fibrous atheroma, cholesterol abscess, thrombosed material, and calcified plaque. All plaques consisted of the combination of at least two components (Table 4). Fibrous atheroma was the most common surgical finding (25 of 25, 100%) followed by cholesterol abscess (19 of 25, 76%), and calcified plaque (16 of 25, 64%). The least common finding was the intraplaque hemorrhage or thrombosis (7 of 25, 28%).

#### **Discussion**

##### ***Pre-operative evaluation***

To deserve the merit of CEA in stroke prevention, the accuracy of diagnosis is of paramount

**Table 1.** Clinical characteristics

Patients No.	Age (yrs)/sex	Underlying disease				Past history	Presentation
		DLP	DM	HT	IHD		
1	59/M		/	/		2 yr. Lt. hemiparesis	TIA
2	63/F	/		/			AF
3	67/M			/			AF
4	56/M		/				S
5	49/M		/				S
6	81/M		/	/			S
7	60/M	/		/		2 d. Lt. AF	RIND
8	51/M			/		114 d. Lt. hemiparesis	S
9	67/F			/	/	20 d. Rt. hemiparesis	RIND
10	63/M	/	/	/	/		RIND
11	76/M			/		6 m. Rt. hemiparesis	S
12	74/M	/	/	/		30 d. Lt. TIA	RIND
13	66/M			/	/	3 yr. Rt. Hemiparesis	S
14	79/F	/		/			S
15	71/M	/		/		6 m. Rt. hemiparesis	RIND
16	59/M	/		/			S
17	71/M			/		6 m. Lt. hemiparesis	S
18	67/M	/		/			S
19	51/F	/	/	/		8 yr. Rt. hemiparesis	AF
20	68/M			/			TIA
21	70/F		/	/			RIND
22	77/M			/		10 yr. Lt. hemiparesis	RIND
23	76/M			/		12 yr. Rt. hemiparesis	RIND
24	60/M		/	/			S
25	56/M	/	/	/			S

AF = amourosis fugax; CVD = cerebrovascular disease; d = day; DM = diabetes mellitus; DLP = dyslipidemia; F = female; HT = hypertension; IHD = ischemic heart disease; Lt = left; M = male; m = month; Rt = right; RIND = reversible ischemic neurological deficit; S = stroke; TIA = transient ischemic attack; yr = year

importance. NASCET and ECST have established that > 70 to 99% symptomatic ICA stenosis is best treated by a combination of CEA and medical management<sup>(1,2)</sup>. Both different methods of measurement were obtained from contrast angiogram, but angiography is not without risks. In the Asymptomatic Carotid Atherosclerosis Study (ACAS), the angiographic stroke rate was 1.2%, which was slightly greater than half the combined 30-day perioperative morbidity rate of 2.3%<sup>(7)</sup>. Because the annual stroke rate in asymptomatic patient with significant carotid artery disease is only 2 to 5%, this angiographic stroke rate is significant<sup>(7)</sup>. Greater than 70% stenosis or occlusion

of the ICA has been significantly correlated with the occurrence of neurologic complications<sup>(15)</sup>. To avoid such complications, non-invasive screening test with nearly 100% specificity would be a useful alternative tool. Duplex scanning has a reported accuracy of 87 to 95%<sup>(16-23)</sup>. However, Duplex scans tend to underestimate the degree of ICA stenosis<sup>(3)</sup>. MRA is another diagnostic tool that provided sensitivity ranging from 83 to 100%, specificity from 74.5 to 100%, and accuracy from 77 to 96%<sup>(19-21,23)</sup>. Multiple reports have concluded that MRA when combined with Doppler ultrasound can replace conventional angiography for pre-operative assessment of carotid artery stenosis<sup>(3,21,22,24-26)</sup>.

**Table 2.** The interval between initial symptom and operation date as well as carotid artery clamping period

Patients No.	Time interval (days)	Ischemic time (minutes)
1	98	30
2	18	57
3	52	60
4	121	50
5	23	95
6	47	40
7	7	34
8	114	36
9	162	74
10	69	74
11	120	63
12	20	50
13	103	43
14	57	104
15	120	60
16	94	41
17	105	69
18	98	49
19	30	55
20	15	33
21	107	105
22	49	80
23	60	74
24	58	103
25	106	60

**Table 4.** Gross pathology

Patient No.	Plaque character			
	Fibrous atheroma	Cholesterol abscess	Thrombose	Calcify
1	/	/		
2	/	/		/
3	/	/		
4	/	/		
5	/		/	/
6	/			
7	/	/		
8	/	/		/
9	/		/	/
10	/		/	/
11	/	/		/
12	/	/		/
13	/	/		/
14	/	/		/
15	/	/		
16	/		/	/
17	/	/	/	
18	/		/	/
19	/	/	/	/
20	/	/		
21	/	/		/
22	/	/		/
23	/	/		
24	/	/		/
25	/	/		/

**Table 3.** Postoperative outcome

Complications	No. (%)
Silent ICA occlusion	1 (4%)
Mild permanent deficit	1 (4%)
RIND	1 (4%)
TIA	2 (8%)
Wound hematoma	2 (8%)
Pneumonia	1 (4%)

Therefore, in cases of solid evidence of severe stenosis, the authors performed a CEA based solely on the good quality data of Duplex scan and MRA. Additional carotid angiography was undertaken

only in patients with an uncertain degree of arterial stenosis, to delineate the actual stenosis segment and status of the collateral circulation.

#### **Operative management**

Indwelling of shunt during CEA is still the topic of discussion. In cases that non-shunt technique was performed, adequate cerebral perfusion during vessel clamping could be achieved using several measurements to increase cerebral blood flow<sup>(27)</sup>. The most interesting data from the local anesthesia series is that of Steed et al<sup>(28)</sup>. They found that intra-operative neurological deficit was most often associated with carotid dissection or clamp reopening, and only rarely with carotid cross-clamping. Their data supports the



theory that most perioperative neurological deficits are embolic rather than ischemic in nature. Several large series have been presented good surgical results without shunt placement under any circumstances<sup>(8-14)</sup>. Nearly all authors, even those who shunt routinely, agree that shunt was probably not required in the majority of cases<sup>(29)</sup>. Spetzler has likewise reported excellent non-shunt surgical results with a strategy of intra-operative barbiturate and microsurgical technique<sup>(30)</sup>. According to the authors' post-operative results, there was no patient suffering from our non-intraluminal shunt technique. The data demonstrated herein confirm that good clinical results can be achieved without an intraluminal shunt, even in patients with contralateral partial or total obstruction of the carotid artery. Therefore, the authors believe that during clamping the internal carotid without shunt placement, the adequate ipsilateral blood supply could be provided from the naturally developed collateral circulation, intra-operative cerebral protection and increased blood pressure technique. Post-operative neurological deficits; if they occur, are usually due to the embolic phenomenon. This non-shunt technique can be considered as a safe procedure to be performed without the sophisticated intra-operative monitoring (*i.e.* transcranial Doppler, transcranial cerebral oximeter, measuring of stump pressure). However, the surgeon who obtains satisfactory results using the selective shunt or routine shunt should continue to do so.

The benefit of microsurgical carotid endarterectomy, apart from good illumination and magnification, is the ability to remove far rostral extension of the plaque or high carotid bifurcation by tilt the microscope and "look up" under the ankle of mandible. The microscope provides a more precise cleavage plane and complete removal of small fragments and fragile intima. Suture related stenosis could be avoided by smaller suture, closed bites, and delicate vessel wall approximation.

#### **Post-operative management**

The most serious complication after CEA is the hyperperfusion syndrome, although it is an infrequent syndrome, strict blood pressure control is mandatory.

#### **Conclusion**

Although the present study may be limited in terms of number of patients, the authors have found that non-shunt CEA is a safe surgical procedure and has the favorable outcome comparing with the previous

several studies. The need for intra-operative shunting is an individual surgeon's choice.

#### **Potential conflicts of interest**

None.

#### **References**

1. North American Symptomatic Carotid Endarterectomy Trial Collaborators. Beneficial effect of carotid endarterectomy in symptomatic patients with high-grade carotid stenosis. *N Engl J Med* 1991; 325: 445-53.
2. European Carotid Surgery Trialists' Collaborative Group. MRC European Carotid Surgery Trial: interim results for symptomatic patients with severe (70-99%) or with mild (0-29%) carotid stenosis. *Lancet* 1991; 337: 1235-43.
3. Mayberg MR, Wilson SE, Yatsu F, Weiss DG, Messina L, Hershey LA, et al. Carotid endarterectomy and prevention of cerebral ischemia in symptomatic carotid stenosis. Veterans Affairs Cooperative Studies Program 309 Trialist Group. *JAMA* 1991; 266: 3289-94.
4. Goldstein LB, Hasselblad V, Matchar DB, McCrory DC. Comparison and meta-analysis of randomized trials of endarterectomy for symptomatic carotid artery stenosis. *Neurology* 1995; 45: 1965-70.
5. Hobson RW, Weiss DG, Fields WS, Goldstone J, Moore WS, Towne JB, et al. Efficacy of carotid endarterectomy for asymptomatic carotid stenosis. The Veterans Affairs Cooperative Study Group. *N Engl J Med* 1993; 328: 221-7.
6. Moore WS, Barnett HJ, Beebe HG, Bernstein EF, Brener BJ, Brott T, et al. Guidelines for carotid endarterectomy. A multidisciplinary consensus statement from the ad hoc Committee, American Heart Association. *Stroke* 1995; 26: 188-201.
7. Executive Committee for the Asymptomatic Carotid Atherosclerosis Study. Endarterectomy for asymptomatic carotid artery stenosis. *JAMA* 1995; 273: 1421-8.
8. Baker WH, Dorner DB, Barnes RW. Carotid endarterectomy: is an indwelling shunt necessary? *Surgery* 1977; 82: 321-6.
9. Bland JE, Lazar ML. Carotid endarterectomy without shunt. *Neurosurgery* 1981; 8: 153-7.
10. Ferguson GG. Intra-operative monitoring and internal shunts: are they necessary in carotid endarterectomy? *Stroke* 1982; 13: 287-9.
11. Ferguson GG. Carotid endarterectomy: indications

- and surgical technique. *Int Anesthesiol Clin* 1984; 22: 113-21.
12. Ferguson GG. Protection of the brain during carotid endarterectomy. IV. Shunt almost never. *Int Anesthesiol Clin* 1984; 22: 147-52.
  13. Ferguson GG. Carotid endarterectomy. To shunt or not to shunt? *Arch Neurol* 1986; 43: 615-7.
  14. Ott DA, Cooley DA, Chapa L, Coelho A. Carotid endarterectomy without temporary intraluminal shunt. Study of 309 consecutive operations. *Ann Surg* 1980; 191: 708-14.
  15. Heiserman JE, Dean BL, Hodak JA, Flom RA, Bird CR, Drayer BP, et al. Neurologic complications of cerebral angiography. *AJNR Am J Neuroradiol* 1994; 15: 1401-7.
  16. Crew JR, Dean M, Johnson JM, Knighton D, Bashour TT, Ellertson D, et al. Carotid surgery without angiography. *Am J Surg* 1984; 148: 217-20.
  17. Goodson SF, Flanigan DP, Bishara RA, Schuler JJ, Kikta MJ, Meyer JP. Can carotid duplex scanning supplant arteriography in patients with focal carotid territory symptoms? *J Vasc Surg* 1987; 5: 551-7.
  18. Thomas GI, Jones TW, Stavney LS, Manhas DR, Spencer MP. Carotid endarterectomy after Doppler ultrasonographic examination without angiography. *Am J Surg* 1986; 151: 616-9.
  19. Moneta GL, Edwards JM, Chitwood RW, Taylor LM Jr, Lee RW, Cummings CA, et al. Correlation of North American Symptomatic Carotid Endarterectomy Trial (NASCET) angiographic definition of 70% to 99% internal carotid artery stenosis with duplex scanning. *J Vasc Surg* 1993; 17: 152-7.
  20. Mittl RL Jr, Broderick M, Carpenter JP, Goldberg HI, Listerud J, Mishkin MM, et al. Blinded-reader comparison of magnetic resonance angiography and duplex ultrasonography for carotid artery bifurcation stenosis. *Stroke* 1994; 25: 4-10.
  21. Mattle HP, Kent KC, Edelman RR, Atkinson DJ, Skillman JJ. Evaluation of the extracranial carotid arteries: correlation of magnetic resonance angiography, duplex ultrasonography, and conventional angiography. *J Vasc Surg* 1991; 13: 838-44.
  22. Patel MR, Kuntz KM, Klufas RA, Kim D, Kramer J, Polak JF, et al. Preoperative assessment of the carotid bifurcation. Can magnetic resonance angiography and duplex ultrasonography replace contrast arteriography? *Stroke* 1995; 26: 1753-8.
  23. Turnipseed WD, Kennell TW, Turski PA, Acher CW, Hoch JR. Magnetic resonance angiography and duplex imaging: noninvasive tests for selecting symptomatic carotid endarterectomy candidates. *Surgery* 1993; 114: 643-8.
  24. Laster RE Jr, Acker JD, Halford HH 3rd, Nauert TC. Assessment of MR angiography versus arteriography for evaluation of cervical carotid bifurcation disease. *AJNR Am J Neuroradiol* 1993; 14: 681-8.
  25. Anderson CM, Saloner D, Lee RE, Griswold VJ, Shapeero LG, Rapp JH, et al. Assessment of carotid artery stenosis by MR angiography: comparison with x-ray angiography and color-coded Doppler ultrasound. *AJNR Am J Neuroradiol* 1992; 13: 989-1003.
  26. Polak JF, Bajakian RL, O'Leary DH, Anderson MR, Donaldson MC, Jolesz FA. Detection of internal carotid artery stenosis: comparison of MR angiography, color Doppler sonography, and arteriography. *Radiology* 1992; 182: 35-40.
  27. Mackey WC, O'Donnell TF Jr, Callow AD. Carotid endarterectomy contralateral to an occluded carotid artery: perioperative risk and late results. *J Vasc Surg* 1990; 11: 778-83.
  28. Steed DL, Peitzman AB, Grundy BL, Webster MW. Causes of stroke in carotid endarterectomy. *Surgery* 1982; 92: 634-41.
  29. Ojemann RG, Heros RC. Carotid endarterectomy. To shunt or not to shunt? *Arch Neurol* 1986; 43: 617-8.
  30. Spetzler RF, Martin N, Hadley MN, Thompson RA, Wilkinson E, Raudzens PA. Microsurgical endarterectomy under barbiturate protection: a prospective study. *J Neurosurg* 1986; 65: 63-73.

---

## การศึกษาผลลัพธ์ของการผ่าตัดรักษาหลอดเลือดแดงคาโรติดที่คอติดด้วยวิธี *non-shunt carotid endarterectomy*

อนุศักดิ์ เลียงอุดม, วุฒิพงษ์ จุริใจไท, ชัยพล วุฒิโอกาส

**วัตถุประสงค์:** ถึงแม้ว่าการผ่าตัด *carotid endarterectomy* (CEA) จะมีมานานกว่า 60 ปีแล้วก็ตาม แต่ยังคงมีข้อถกเถียงถึงความจำเป็นที่ต้องใส่ *shunt* ระหว่างการทำ CEA, บางกลุ่มจะเลือกใส่ *shunt* ในกรณีที่มีความผิดปกติของค่าการตรวจทางประสาทรีวิวิทยาในท้องผ่าตัด แต่ก็มีกลุ่มที่รายงานถึงผลผ่าตัดที่ดีโดยไม่ต้องใส่ *shunt* มีรายงานมากมายที่ระบุว่า อัมพาตหรืออัมพฤกษ์ หลัง CEA เป็นผลจากการหลุดของอิมไซมัน หรือ เทคนิคการผ่าตัดที่ไม่ดี มากกว่าที่จะเกิดจากสมองขาดเลือดในระหว่างการทำ CEA, รายงานการศึกษานี้มีวัตถุประสงค์ เพื่อบรรยายถึงเทคนิคการผ่าตัด CEA โดยไม่ใส่ *shunt* และวิเคราะห์ผลภายหลังการผ่าตัด

**วัสดุและวิธีการ:** เป็นการศึกษาย้อนหลัง 4 ปี ในผู้ป่วย 25 รายที่มีอายุระหว่าง 49-81 ปี

**ผลการศึกษา:** ผู้ป่วย 25 ราย มาโรงพยาบาลด้วยภาวะของ *minor stroke* 12 ราย, มีภาวะ *reversible ischemic neurological deficit* 8 ราย และอีก 5 รายมาด้วยอาการของ *transient ischemic attack* ไม่มีผู้ป่วยที่เสียชีวิต และไม่พบว่ามีความสัมพันธ์ระหว่างการเกิดอัมพฤกษ์หลังผ่าตัด กับช่วงเวลาที่หนีบหลอดเลือดแดงคาโรติด และไม่สัมพันธ์กับการมีภาวะตีบของหลอดเลือดคาโรติดฝั่งตรงข้าม

**สรุป:** การผ่าตัด CEA โดยการใส่สาย *shunt* ยังคงขึ้นกับความเชื่อของศัลยแพทย์ผู้ผ่าตัด แต่จากข้อมูลการศึกษานี้ พบว่าการผ่าตัด CEA โดยไม่ใส่ *shunt* ยังถือว่ามีความปลอดภัย ถ้าทำอย่างถูกต้องและละเอียดรอบคอบ

---