

# Case Report

## Successful Outcome of Obturator Bypass Surgery in Infected Femoral Pseudoaneurysm: Three Cases Report and Literature Review

Chanean Ruangsetakit MD\*, Khamin Chinsakchai MD\*,  
Suteekhanit Hahtapornsawan MD\*, Chumpol Wongwanit MD\*,  
Nuttawut Sermsathanasawadi MD, PhD\*, Pramook Mutirangura MD\*

\* Vascular Surgery Unit, Department of Surgery, Faculty of Medicine Siriraj Hospital,  
Mahidol University, Bangkok, Thailand

---

*The authors report a successful management of obturator bypass surgery in three patients with infected femoral pseudoaneurysm. This bypass reconstruction is an uncommon operation due to the difficult surgical technique and infrequent indications. In the present report, the authors reviewed the literature published between 1988 and 2008 consisting of 78 cases with the claim of obturator bypass surgery for this condition. It is important to note that this type of extra-anatomical bypass together with debridement and excision of infected femoral pseudoaneurysm might be another option to decrease the risk of vascular conduit infection and increase successful limb salvageability.*

**Keywords:** Infection, Femoral pseudoaneurysm, Obturator bypass, Outcome

**J Med Assoc Thai 2012; 95 (3): 470-5**

**Full text. e-Journal:** <http://www.jmat.mat.or.th>

---

Pseudoaneurysm is attributed to a variety of causes such as infection, anastomotic graft disruption, trauma, intra-arterial drug injection, closure device infection, and arterial access for diagnostic or endovascular procedures<sup>(1)</sup>. It is most frequently seen in the groin region<sup>(2)</sup>. A patient who was diagnosed with infected femoral pseudoaneurysm typically presented with fever, together with swollen, painful, and pulsatile mass. This condition may be misdiagnosed as a simple groin abscess if a general practitioner does not recognize it.

Controversy still exists about the management of the infected femoral pseudoaneurysm. Several surgeons suggested that ligation, excision of pseudoaneurysm, and local debridement are safe treatment modalities to avoid a risk of vascular conduit infection<sup>(3-6)</sup>. Others preferred excision of pseudoaneurysm following extra-anatomic bypass with obturator bypass reconstruction because this bypass is far from an infected groin area<sup>(7-9)</sup>. In

addition, this procedure has lower claudication, rest pain and amputation rates than ligation and resection of pseudoaneurysm<sup>(10)</sup>. To date, the obturator bypass is infrequently performed due to the difficult surgical technique and infrequent indications.

In the present study, the authors wish to report the outcomes of treating three patients with the infected femoral pseudoaneurysm on whom the obturator bypass surgery together with debridement and excision of pseudoaneurysm were performed. The Siriraj ethical committee for research in humans approved this article.

### Case Report

#### Surgical technique

The principle of obturator bypass is to avoid the infected groin region, which was originally addressed by Shaw and Baue<sup>(11)</sup>. The patient was placed on the operating table in the supine position. The operation was performed under general anesthesia. The affected entire leg was prepared and draped. The hip can be flexed and externally rotated to relax the thigh musculature in this position. Abdominal exposure may be gained through a median or a retroperitoneal approach. The retroperitoneal approach was performed through oblique abdominal

---

#### Correspondence to:

Chinsakchai K, Vascular Surgery Unit, Department of Surgery,  
Faculty of Medicine Siriraj Hospital, Mahidol University,  
Bangkok 10700, Thailand.

Phone: 0-2411-1808, Fax: 0-2412-9160

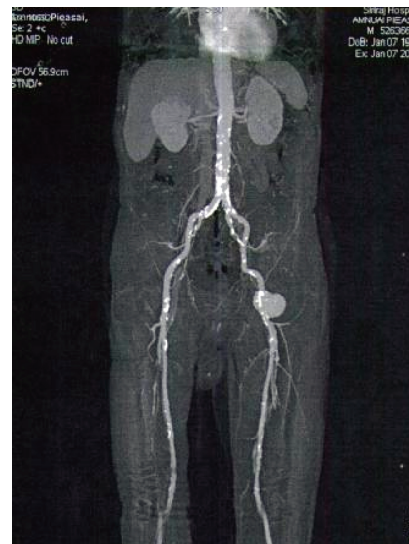E-mail: [khaminc@gmail.com](mailto:khaminc@gmail.com)

incision when preoperative computed tomographic angiography (CTA) showed an iliac artery was suitable as an inflow vessel for the graft. The site selected for distal anastomosis depends on the extent of the disease, as determined by palpation and accurate preoperative CTA. For obturator bypass, the authors usually use a 6- to 8-mm ringed polytetrafluoroethylene (PTFE) graft. The obturator foramen is visualized at posterior to the superior pubic ramus and covered by thick aponeurosis. Gentle sweeping of the peritoneal sac, ureter, and bladder to the midline gives access to this foramen. The obturator artery, vein, and nerve pass through the lateral superior margin of the obturator canal. The obturator aponeurosis was incised by electrocautery and enlarged by fingers. A distal incision was made medially in the lower knee to access popliteal artery. The surgeon now selects an area for making a tunnel through the foramen. This tunnel should be located away from where the obturator artery and nerve pass through, to avoid injury to these two structures. Obturator vein was ligated to prevent accidental injury during the insertion of tunneler. Before systemic heparin administration (80 IU/kg), the tunneler passed the obturator foramen through a plane between the adductor longus and magnus muscles to the popliteal fossa. Then, the PTFE graft placement was inserted into the tunneler. The inflow anastomosis to this graft was placed to either the iliac artery or the infrarenal aorta by the end to side technique. The distal anastomosis on popliteal artery was performed with miller patch in two cases and direct anastomosis to the previous femoropopliteal bypass graft in one case. After the completion of the distal anastomosis, the vascular clamps were released and the peritoneum was closed carefully. The abdominal and thigh incisions were closed, and dressings were applied.

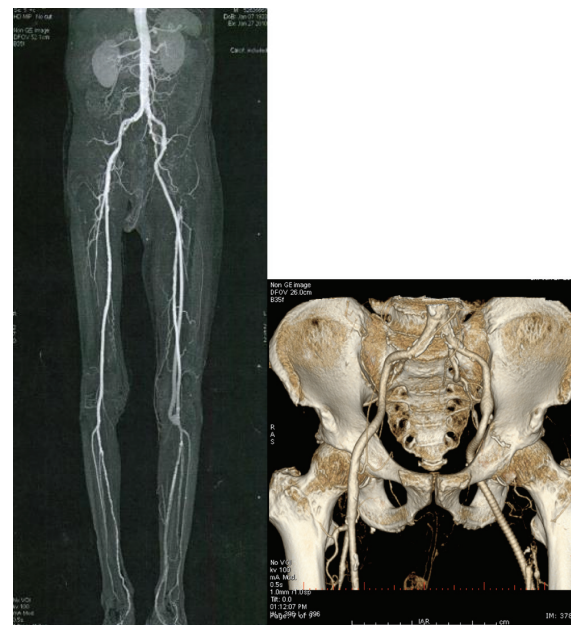
### Case 1

A 76-year-old male with diabetes mellitus, hypertension, and chronic obstructive lung disease presented with a three-week history of fever and swelling in the left groin. The examination at the affected groin showed a pulsatile mass with thrill and tenderness. He underwent CTA showing a 6-cm pseudoaneurysm with conceal rupture at the left common femoral artery (Fig. 1). The diagnosis of infected pseudoaneurysm was made. On admission, he was treated empirically with intravenous (IV) Ceftriazone and Vancomycin. He was taken to the operating room where a 7-mm PTFE ring graft was

placed between the left external iliac artery and the popliteal artery with distal Miller patch through the obturator foramen (Fig. 2). The aneurysm was excised following the ligation of the external iliac artery above the inguinal ligament and the superficial and deep femoral arteries through small incision beneath



**Fig. 1** CTA shows a 6-cm pseudoaneurysm at the left common femoral artery



**Fig. 2** CTA shows a 7-mm PTFE graft between the left external iliac artery and the left popliteal artery with Miller patch through the obturator foramen

the aneurysm. The tissue culture grew Salmonella group D. He had an uneventful postoperative course and was discharged on day 32 with oral ciprofloxacin. The graft was still good patency at the 12-month follow-up period.

### Case 2

A 69-year-old male smoker suffering from hypertension and diabetes mellitus, was admitted with a three-month history of swelling in the right groin. The examination showed a pulsatile mass with erythematous area and tenderness in the affected groin. The CTA showed a 5-cm pseudoaneurysm at the right common femoral artery, total occlusion of proximal the three-fourth of the right superficial artery and stenosis of the left external iliac artery (Fig. 3A). The diagnosis of infected pseudo aneurysm with the right femoropopliteal and the left iliofemoral occlusive disease was made. He was treated empirically with Ceftriazone and Cloxacillin. The patient was taken to the operating room where a Dacron bifurcated graft was placed between the aorta and left femoral artery and a 7-mm PTFE ring graft was anastomosed between the right limb of Dacron graft and the right popliteal artery with Miller patch through the obturator foramen (Fig. 3B). The pseudoaneurysm was excised following ligation of the right common, superficial, and deep femoral arteries. The tissue culture grew Burkholderia pseudomallei. His recovery was uneventful and he was discharged on the day 20. The graft was still good patency at the 25-month follow-up period.

### Case 3

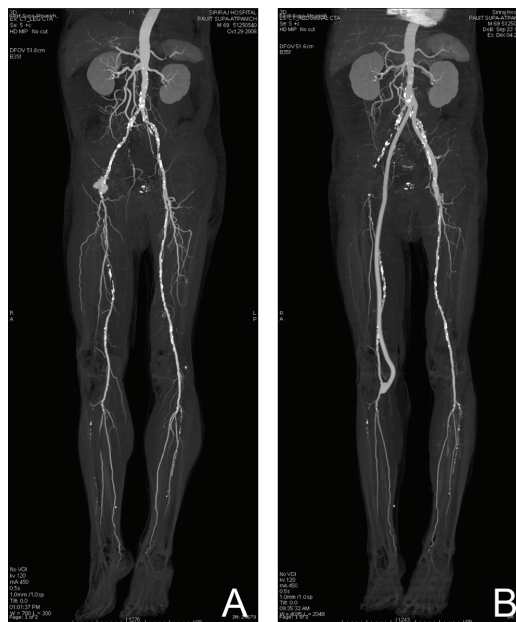
A 70-year-old female with hypertension and diabetes mellitus and ischemic heart disease, was admitted with a two-week history of swelling and pain in the left groin. She had a previous left femoropopliteal PTFE with composite vein graft 5 years ago. The examination showed a 10-cm tender mass in the left groin. On admission, she was treated with Amoxycillin and Sulbactam. The CTA showed a pseudoaneurysm at the proximal anastomosis of the previous occluded bypass graft. The patient was taken to the operating room where a 6-mm PTFE ring graft was placed between the left external iliac artery and the distal part of the previous graft through the obturator foramen. The aneurysm was excised following the ligation of the external iliac artery above the inguinal ligament and the superficial and deep femoral arteries through small incision beneath the aneurysm. The tissue had no growth. She was discharged 42 days after the

admission. The graft was still good patency at the 69-month follow-up period.

### Discussion

While the conventional management of infected femoral pseudoaneurysm is femoral arteries ligation, excision of pseudoaneurysm and local debridement, which relate to a high rate of post-operative intermittent claudication and major amputation<sup>(10,12,13)</sup>, the authors propose that obturator bypass reconstruction for this condition can provide immediate distal blood perfusion without evidence of graft infection and major amputation in our three cases.

In general practice, the infected femoral pseudoaneurysm is usually misdiagnosed as having a simple groin abscess<sup>(4)</sup>. These patients usually had the same clinical manifestations such as fever, leukocytosis, and purulent groin abscess. A correct diagnosis of this condition, however, can be made if the general practitioners know a clue for the highly suspicious information such as history of intravenous



**Fig 3** (A) CTA shows a 5-cm pseudoaneurysm at right common femoral artery, total occlusion of proximal the third-fourth of right superficial artery and stenosis of left external iliac artery. (B) CTA demonstrates a Dacron bifurcated graft between the aorta and left femoral artery and a 7-mm PTFE ring graft was placed between the right limb of Dacron graft and the right popliteal artery with Miller patch through the obturator foramen

**Table 1.** Literature review for demographic data and outcomes of obturator bypass reconstruction

First author	Year	Number patients	Mean age (years)	Indication(s)	Type(s) of operation	Graft infection	Graft patency (months)	Limb salvageability (months)	Mortality (months)
Rabbani <sup>(18)</sup>	2008	9	34	Infected Pseudoaneurysm	Ilio to femoral or popliteal bypass	0%	100% (1)	100% (1)	11% (1)
Matoussevitch <sup>(19)</sup>	2007	8	31	Severe vascular groin infection	Iliopopliteal bypass	0%	75% (1)	87.5% (NS)	0% (NS)
Engin <sup>(2)</sup>	2005	5	44	Severe vascular groin infection	Aorto or ilio to femoral or popliteal bypass	20%	100% (mean 53)	100% (mean 53)	0% (mean 53)
Patel <sup>(7)</sup>	2002	12	NS	Severe vascular groin infection	Aorto or ilio to femoral or popliteal bypass	0%	80% (mean 37)	60% (60)	17% (1)
Sautner <sup>(20)</sup>	1994	34	61	Radiation pelvis injury	popliteal bypass	NS	55% (60)	76.5% (60)	14.7% (60)
Patel <sup>(9)</sup>	1988	10	31	Infected vascular prosthesis	Ilio to femoral or tibial bypass	0%	NS	100% (2-43)	0% (2-43)
Siriraj	2010	3	71	Infected Pseudoaneurysm	Ilio to femoral	0%	100% (6-62)	100% (6-62)	0% (6-62)
				Infected Pseudoaneurysm	Aorto or ilio to popliteal bypass	0%	100% (6-62)	100% (6-62)	0% (6-62)

NS = non specified

drug abusers or previous groin procedure. In addition, the infected pseudoaneurysm is usually larger than simple groin abscess with expansile pulsation laterally<sup>(14)</sup>.

To date, there is still debate among surgeons on whether it is necessary to perform the bypass procedure in the infected groin pseudoaneurysm. Proximal and distal ligation with excision of the pseudoaneurysm, together with local debridement of all necrotic tissue without revascularization, remain performing by several surgeons to avoid the risk of vascular conduit infection<sup>(3-5,8,12,13)</sup>. Although, some authors proposed that this method did not have rest pain or major amputation after operation<sup>(3-5)</sup>, others mentioned it had the high rates of postoperative claudication (21 to 73%)<sup>(3-5,12)</sup>, rest pain (20 to 32%)<sup>(12,13)</sup>, and amputation (16 to 33%)<sup>(12,13,15)</sup>. The claudication, rest pain and amputation rates were higher after triple vessel ligation (common femoral artery, superficial femoral artery, and profunda femoral artery) than after single vessel ligation (only common femoral artery)<sup>(5,12,15)</sup>. In addition, several patients needed fasciotomy due to compartment syndrome a few days after ligation and excision alone<sup>(12)</sup>. The signal of Doppler ultrasound at least one pedal artery was recommended to assess limb viability after ligation and excision process or test clamping of the external iliac artery<sup>(3,16)</sup>. This method is a predictive of which patients require revascularization.

The obturator bypass, a rare extra-anatomic vascular reconstruction, is the most favorable route for revascularization in the infected femoral pseudoaneurysm due to avoidance of the infected groin area. The other types of extra-anatomic bypass are axillo and ilio lateral popliteal bypass; however, they are less favorable long-term patency than obturator bypass<sup>(2,17)</sup>. The authors' results showed that this procedure is safe and high effective for limb salvageability, no postoperative rest pain, and no graft infection. The authors performed obturator bypass before the ligation and excision of the pseudoaneurysm during a single operation to prevent postoperative irreversible ischemia<sup>(9,10)</sup>. Although several surgeons<sup>(14,18,19)</sup> endorsed delayed revascularization after the ligation, excision and debridement of pseudoaneurysm to avoid a graft infection, this method had the high rates of claudication (7 to 13%) and amputation (12%)<sup>(10)</sup>.

Infection is an important problem for revascularization of infected pseudoaneurysms. The presence of extended infection in the location of

pseudoaneurysm threatens the artificial graft used for revascularization, especially when the graft is located near the site of infection. In the authors technique, extra-anatomic aorto- or iliopopliteal bypass through the obturator foramen is deep and far from the infected site in the groin area. The graft infection rate after extra-anatomic bypass is varied from 0 to 20%<sup>(2,7,9,10,18,19)</sup>. The authors had no graft infection in the three presented patients among 12, 25, and 69 months of follow-up period.

The outcome of obturator bypass is the most important issue to consider in treatment of the infected femoral pseudoaneurysm. From the literature review<sup>(2,7,9,18-20)</sup> (Table 1), the outcomes of graft patency, limb salvageability, and mortality rate are varied on the duration of follow-up, between one month and 60 months. From table, the rates of graft patency and limb salvageability vary on 55% to 100% and 60% to 100%, respectively. In addition, the figures in the literature pertaining to the mortality rate vary between 0% and 17%. On comparing the authors' findings with those in the literature, the authors results showed the successful outcomes, of which all patients have 100% graft patency and limb salvageability; and none of the patients had mortality during 12 to 69 months of follow-up. The limitation of the obturator bypass is that it may not be feasible when deep layers of adductor muscle are involved with infection. In addition, the venous bleeding usually occurs during graft tunneling if an obturator vein is not sacrificed<sup>(2)</sup>.

In conclusion, the infected groin and expansile pulsation are the important clues for clinical diagnosis of infected femoral pseudoaneurysm. The obturator bypass reconstruction together with ligation, excision pseudoaneurysm, and debridement during the single operation may be a therapeutic option for improvement of the outcomes in this serious condition.

#### **Potential conflicts of interest**

None.

#### **References**

1. Bell CL, Ali AT, Brawley JG, D'Addio VJ, Modrall JG, Valentine RJ, et al. Arterial reconstruction of infected femoral artery pseudoaneurysms using superficial femoral-popliteal vein. *J Am Coll Surg* 2005; 200: 831-6.
2. Engin C, Posacioglu H, Ayik F, Apaydin AZ. Management of vascular infection in the groin. *Tex Heart Inst J* 2005; 32: 529-34.

3. Arora S, Weber MA, Fox CJ, Neville R, Lidor A, Sidawy AN. Common femoral artery ligation and local debridement: a safe treatment for infected femoral artery pseudoaneurysms. *J Vasc Surg* 2001; 33: 990-3.
4. Ting AC, Cheng SW. Femoral pseudoaneurysms in drug addicts. *World J Surg* 1997; 21: 783-6.
5. Cheng SW, Fok M, Wong J. Infected femoral pseudoaneurysm in intravenous drug abusers. *Br J Surg* 1992; 79: 510-2.
6. Peirce C, Coffey JC, O'Grady H, Aly S, O'Malley K, O'Donohoe M. The management of mycotic femoral pseudoaneurysms in intravenous drug abusers. *Ann Vasc Surg* 2009; 23: 345-9.
7. Patel A, Taylor SM, Langan EM 3rd, Snyder BA, Cull DL, Sullivan TM, et al. Obturator bypass: a classic approach for the treatment of contemporary groin infection. *Am Surg* 2002; 68: 653-8.
8. Levi N, Rordam P, Jensen LP, Schroeder TV. Femoral pseudoaneurysms in drug addicts. *Eur J Vasc Endovasc Surg* 1997; 13: 361-2.
9. Patel KR, Semel L, Clauss RH. Routine revascularization with resection of infection femoral pseudoaneurysms from substance abuse. *J Vasc Surg* 1988; 8: 321-8.
10. Georgiadis GS, Lazarides MK, Polychronidis A, Simopoulos C. Surgical treatment of femoral artery infected false aneurysms in drug abusers. *ANZ J Surg* 2005; 75: 1005-10.
11. Shaw RS, Baue AE. Management of sepsis complicating arterial reconstructive surgery. *Surgery* 1963; 53: 75-86.
12. Johnson JR, Ledgerwood AM, Lucas CE. Mycotic aneurysm. New concepts in therapy. *Arch Surg* 1983; 118: 577-82.
13. Feldman AJ, Berguer R. Management of an infected aneurysm of the groin secondary to drug abuse. *Surg Gynecol Obstet* 1983; 157: 519-22.
14. Fromm SH, Lucas CE. Obturator bypass for mycotic aneurysm in the drug addict. *Arch Surg* 1970; 100: 82-3.
15. Reddy DJ, Smith RF, Elliott JP Jr, Haddad GK, Wanek EA. Infected femoral artery false aneurysms in drug addicts: evolution of selective vascular reconstruction. *J Vasc Surg* 1986; 3: 718-24.
16. Behera A, Menakuru SR, Jindal R. Vascular complications of drug abuse: an Indian experience. *ANZ J Surg* 2003; 73: 1004-7.
17. Rutherford RB, Patt A, Pearce WH. Extra-anatomic bypass: a closer view. *J Vasc Surg* 1987; 6: 437-46.
18. Rabbani A, Moini M, Rasouli MR. Obturator bypass as an alternative technique for revascularization in patients with infected femoral pseudoaneurysms. *Arch Iran Med* 2008; 11: 50-3.
19. Matoussevitch V, Aleksic M, Gawenda M, Brunkwall J. Primary extraanatomical revascularization for groin infections in drug addicts. *Vasa* 2007; 36: 210-4.
20. Sautner T, Niederle B, Herbst F, Kretschmer G, Polterauer P, Rendl KH, et al. The value of obturator canal bypass. A review. *Arch Surg* 1994; 129: 718-22.

**ผลสำเร็จของการรักษาภาวะติดเชื้อของหลอดเลือดแดงฟีมอรัลโป่งพองโดยวิธีออปทูเรเตอร์บายพาส: รายงานผู้ป่วย 3 ราย**

เจนีเยน เรืองเศรษฐกิจ, คามิน ชินศักดิ์ชัย, สุทธิคณิต หักพรสวรรค์, ชุมพล ว่องวานิช, ณัฐวุฒิ เสริมสาธนสวัสดิ์, ประมุข มุทิตราภรณ์

รายงานผลสำเร็จของการรักษาผู้ป่วย 3 ราย ที่มีภาวะติดเชื้อของหลอดเลือดแดงฟีมอรัลที่โป่งพองด้วยวิธีออปทูเรเตอร์บายพาส การผ่าตัดเปลี่ยนทางเดินหลอดเลือดแดงโดยวิธีนี้เป็นการผ่าตัดที่พบไม่บ่อย เนื่องจากเป็นวิธีผ่าตัดที่ค่อนข้างยากและซับซ้อนซึ่งพบไม่บ่อยนัก ในรายงานนี้ ผู้นิพนธ์ได้ทบทวนวรรณกรรมระหว่างปี พ.ศ. 2531-2551 ประกอบด้วยผู้ป่วย 78 ราย ที่ผ่าตัดด้วยวิธีดังกล่าวในภาวะติดเชื้อของหลอดเลือดแดงฟีมอรัลที่โป่งพองเช่นเดียวกัน ซึ่งพบว่าภาวะติดเชื้อของหลอดเลือดแดงฟีมอรัลโป่งพองนี้ การผ่าตัดออปทูเรเตอร์บายพาสร่วมกับการรักษาโดยการตัดเนื้อตายที่ติดเชื้อและการกำจัดหลอดเลือดแดงฟีมอรัลที่ติดเชื้อออกไป อาจเป็นวิธีหนึ่งที่ช่วยลดการติดเชื้อของหลอดเลือดเทียมที่ทำบายพาส และลดอัตราการถูกตัดขาในผู้ป่วยเหล่านี้ได้