

Snake Scope Camera Assisted Endotracheal Intubation: A Procedural Skills Training in Cadaver to Prepare Preclinical Students for Their Clerkships

Tanvaa Tansatit MD*,
Prawit Apinuntrum BEd*, Thavorn Phetudom BSc*

* The Chula Soft Cadaver Surgical Training Center and Department of Anatomy, Faculty of Medicine,
Chulalongkorn University, Bangkok, Thailand

Objective: Preparing students to perform specific procedures on patients presents a challenge of student confidence in performing these tasks. This descriptive study determined the ability of the medical students to perform a basic clinical task after a short hands-on training workshop in cadavers. This basic procedural skills training was an attempt for developing conceptual understanding and increasing procedural skills in endotracheal intubation of the medical students.

Material and Method: The students were trained to perform two different endotracheal intubations, uncomplicated intubation, and a traumatic difficult airway scenario. The training session consisted of two methods of endotracheal intubation, oral intubations using direct laryngoscopy (DL) in two cadavers with uncomplicated airway and the Flexible Snake Scope camera (FSSC) assisted nasal intubation procedures in two cadavers simulated trauma victims with difficult airway. In the assessment session, the students performed one timed trial with each device. All four cadavers were changed but the scenarios were the same. The groups of the medical students were randomly assigned to perform the tasks in one of two cadavers of the two scenarios.

Results: Thirty-two medical students participated in this training and assessment. The training session and the assessment lasted five hours and three hours respectively. No student was asked to perform the second trial. The average time for successful intubation with DL was 32.7 seconds (SD, 13.8 seconds) and for FSSC was 127.0 seconds (SD, 32.6 seconds). The intubation failure rate was 0% for the entire study.

Conclusion: The medical students have the ability to accomplish a basic clinical task after a short hands-on training workshop.

Keywords: Intubation, Difficult airway, Snake scope camera, Medical students, Cadavers

J Med Assoc Thai 2012; 95 (2): 205-11

Full text. e-Journal: <http://www.jmat.mat.or.th>

Preparing students to perform specific procedures on patients presents a challenge of student anxiety and confidence in performing these tasks⁽¹⁾. Practicing specific procedures in medical education relies upon the opportunity to present a real patient in the ward requiring the procedure that cannot be prepared in advance for the medical students. In addition, there is a limited time of the instruction for a specific procedure to be performed on an actual patient. Previous studies have described attempts to mitigate the problems associated with teaching procedural

skills to students⁽²⁻⁷⁾. These attempts range from clinical skill elective courses that have introduced students to specific tasks prior to residency⁽²⁾ to courses designed to introduce preclinical students to procedural skills they will encounter once they begin their clerkships in the clinical years⁽³⁻⁵⁾. Activities focused on practicing a specific task had been arranged^(6,7). These reports described the utility of these approaches in early exposing medical students to the procedures they will encounter in their clerkships to improve confidence in performing clinical procedures and to increase the competence in procedural performance. Few studies have investigated the procedural skills of the medical students, however, introduction to some skills early in the preclinical courses was described previously⁽³⁻⁵⁾. Prior work held the course just prior to the beginning of the clerkships⁽⁴⁾. Those are the works that the present

Correspondence to:

Tansatit T, The Chula Soft Cadaver Surgical Training Center and Department of Anatomy, Faculty of Medicine, Chulalongkorn University, Bangkok 10330, Thailand.
Phone: 081-809-4414
E-mail aprawit@yahoo.com

study is modeled after. Real life simulations may stimulate learners' attention and facilitate retention of the concepts learned in the course and the practicality of the actual application of the skills on patients. Herein, the authors describe one of their initial attempts to introduce basic procedural skills in a selective course to medical students during the end of the preclinical years in a small group setting using cadaver simulations to prepare them for performing procedures in the hospital.

This descriptive study determined the ability of the medical students to perform a basic clinical task after a short hands-on training workshop. This basic procedural skills training was an attempt for developing conceptual understanding and increasing procedural skills in endotracheal intubation of the medical students. They were prepared for their clerkships in the clinical years and for their assignments after graduation as physicians in urban emergency medical service during hospital-based rotations.

Material and Method

The present pilot study conformed to the informed consent for cadaver donation of the King Chulalongkorn Memorial Hospital. The endotracheal intubation training involved 32 third-year medical students and eight soft-embalmed cadavers in a 4-credit selective course of the Clinical Anatomy. The present study was also one of the main objectives of the Chula Soft Cadaver Surgical Training Center. The medical students had no experience with endotracheal intubation. To develop conceptual understanding in endotracheal intubation, the students were trained to perform two different endotracheal intubations, uncomplicated intubation, and a traumatic difficult airway scenario.

The basic procedural skills training session: The training session consisted of two methods of endotracheal intubation, oral intubations using direct laryngoscopy (DL) in two cadavers with uncomplicated airway and the Flexible Snake Scope camera (FSSC) (Fig. 1) assisted nasal intubation procedures in two cadavers simulated trauma victims with difficult airway. The authors chose the FSSC to introduce the medical students to be familiar with the video-assisted procedures. The FSSC is commonly used in the fields of security and engineering. It has a long flexible neck, with a color 640 x 480 p camera and two adjustable-brightness white LED's on the end. They can shoot stills and VGA video, which is output directly to a laptop computer. The FSSC takes its power directly

from USB port. It has a waterproof head and an autofocus system. The FSSC retails for \$US150 (Maplin Electronics, Rotherham, UK). Two cadavers had a soft cervical collar for cervical spine immobilization to simulate difficult airway intubations during traumatic emergency rescue for the FSSC assisted nasal intubations. The normal airways allowed alignment of the operators' eyes, mouth, oropharynx and laryngeal orifice using a pillow under the cadavers' head. The cadavers of maxillofacial trauma scenario with difficult airway limited the alignment to only slight extension of the atlanto-occipital joint, no flexion of the cervical spine was allowed and had a limited mouth opening to 2.5 cm. In these cadavers, only the epiglottis was seen and could only be lifted up and away from the posterior pharyngeal wall as a Cormack-Lehane grade IIIA view. During nasal intubation, the head of the FSSC was inserted in the oral cavity instead of the endotracheal tube until the head reached the oropharynx to visualize the laryngeal orifice during the intubation. The students were paired and divided into 16 groups of two. The two students in each group took their turn as operator and assistant. They all received standardized didactic instruction as one class and then had small group hands-on training with DL and FSSC on four cadavers for one hour, approximately 15 minutes per cadaver in each group, and then practiced intubating until they felt comfortable and confident with the techniques under supervision of the course instructors.

Endotracheal intubation: The cadaver was in supine position with a pillow under the head. The student adjusted the cadaver head to flex the neck and



Fig. 1 The flexible snake scope camera (FSSC)

extend the atlanto-occipital joint. The depth of endotracheal insertion between the mouth and the trachea was measured and the marker on the tube was recognized. The student opened the mouth and inserted the laryngoscope with the blade directed to reach the right tonsil and swept the blade to the midline keeping the tongue on the left to bring the epiglottis into view. Then the student advanced the laryngoscope blade until it reached the angle between the base of the tongue and the epiglottis and then lifted the laryngoscope upwards and away towards the chest to bring the vocal cords into view. An assistant pressed on the edge of the cricoid cartilage to improve the view. The students kept the concavity of the endotracheal tube facing up and inserted the tube mounted onto a stylet through the cords while watching the tube entering the larynx. The student inflated the cuff and squeezed the Ambu bag after removal of the stylet. In cadaver simulated trauma victim with difficult airway, nasal intubation was performed under FSSC guidance (Fig. 2). Suction nozzles, endotracheal tubes, and laryngoscopes were cleaned and washed during the procedure of each student.

The assessment session: On the afternoon in the assessment session after the training, the students performed only one timed trial with each device. All four cadavers were changed but the scenarios were the same. The groups of the medical students were randomly assigned to perform the tasks in one of two cadavers of the two scenarios. A

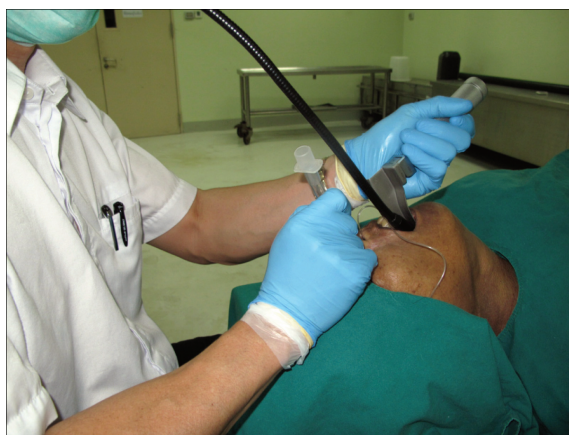

Fig. 2 During nasal intubation, the head of the FSSC is inserted into the oral cavity instead of the endotracheal tube until the head reaches the oropharynx to visualize the laryngeal orifice during the intubation

successful intubation was tracheal intubation with lung inflation. An unsuccessful intubation was intubation requiring longer than three minutes or inability to intubate. If one minute elapsed, the students were required to withdraw the intubating device, give two rescue breaths with the bag valve mask, and then resume their intubation attempt. After the cuff was inflated, the investigator inspected the result and asked the student to perform the second trial if the tube was not correctly placed in the trachea. The assistant could advise the operator as in the real situation. The investigator observed the procedures from the DL held by the operator student and from the laptop monitor of the FSSC and recorded the grading of the Cormack-Lehane Laryngoscope view, but they did not interfere with the assessment process. The intubation time was recorded. They assessed the intubations and observed the tube withdrawal from the larynx to verify and to confirm the correct placement of the tube. A secondary outcome measured the laryngeal orifice visualization time and the intubation time after laryngeal orifice visualization using both devices. After the assessment, the students received the immediate feedback of the results. Before the training and after the assessment, the students were asked to rate on a 10-point likert scale their confidence to perform the endotracheal intubation task on a patient.

Results

Thirty-two medical students participated in this training and assessment. The training session and the assessment lasted five hours and three hours respectively. No student was asked to perform the second trial. Conclusions of the assessment were described as follows. The average time for successful intubation with DL was 32.7 seconds (SD, 13.8 seconds), and for FSSC was 127.0 seconds (SD, 32.6 seconds). The intubation failure rate was 0% for the entire study. In uncomplicated intubation, the students recognized laryngoscopic view as Cormack-Lehane grade I in 16 timed trials and grade II in 16 trials before they decided to insert the endotracheal tube. Five trials (16%) required second attempt to accomplish. No third attempt was done (Table 1).

For difficult airway cadavers, the FSSC could convert the direct laryngoscopic view from Cormack-Lehane grade III view to Cormack-Lehane grade II view of the indirect laryngoscopic view under FSSC monitoring in 24 timed trials (75%) and grade I view in eight trials (25%). Of 24 timed trials, 20 Cormack-Lehane

grade II view could be subsequently changed into grade I view (83%) by pressing the interarytenoid notch with the tip of the tube reinforced by the stylet while elevated the laryngoscopic blade. Five (16%) of the difficult intubation with FSSC were accomplished in the second attempt. Secondary outcomes measured the laryngeal orifice visualization time and the intubation time after laryngeal orifice visualization using both devices. For DL, mean laryngeal orifice visualization time after DL insertion was 21.7 seconds (SD, 8.6 seconds) and mean intubation time after laryngeal orifice visualization was 11.0 seconds (SD, 5.7 seconds). For FSSC, mean laryngeal orifice visualization time after DL insertion was 86.8 seconds (SD, 23.1 seconds) and mean intubation time after laryngeal orifice visualization was 40.2 seconds (SD, 16.1 seconds) (Table 1). The students rated their confidence to perform the endotracheal intubation on a real patient after the assessment at 8.2 (SD, 0.7) from 10-point Likert scale compared to 1.7 (SD, 0.7, $p=0.000$) before the training session.

Discussion

During the training process, the authors observed a chance of failed intubation under the FSSC monitoring. Firstly, the authors recognized that the normal laryngeal orifice faced dorsally, not superiorly, because the epiglottis lay against the posterior pharyngeal wall. Beside, the posterior part of the tongue almost occupied the entire oropharynx. Not only did the authors have to elevate the tongue anteriorly at the velliculae using the laryngoscope blade to open the oropharynx and the laryngeal orifice but also had to press the cricotracheal junction posteriorly to rotate the laryngeal orifice into the oropharyngeal view. The authors also found that the only chance that the tube stuck at the glottic level occurred when the tube was forced toward the piriform recesses. The tube engaged the recess and could not reach the laryngeal orifice. On the other

hand, forcing the tube against the arytenoid cartilages or the epiglottis, the force deviated or distorted the cartilages and the tube entered the larynx or the esophagus depending on the direction of force. This finding suggests that if the blind intubation is attempted and the tube cannot reach the glottis, the tube should be withdrawn and reinsertion should be done under direct visual guidance. No specific suggestion to perform the procedure successfully could be made without soft tissue trauma. If the situation forces to continue blinded intubation, at least the epiglottis have to be seen and the tube mounted onto a curve stylet have to be inserted between of the epiglottis and the pharyngeal wall in the midline and then pushed anteriorly aiming the tip to slide down along the epiglottis through the glottis. This is the only chance to enter the larynx and avoid engaging the piriform recesses. If the stylet does not have a proper curve, the tube may slip out the interarytenoid notch to the esophagus.

The intubation time of both DL and the FSSC assisted intubation techniques were acceptable (range, 17 to 174 seconds) in a cadaver model. The authors reminded all the students that in the real critical situations with the constrained time in the trauma service more difficult airways and mark difficult intubation could be encountered. Intubation with DL was faster than with the FSSC assisted intubation. However, without the FSSC for visual aid, success intubation may not be accomplished. The clinical significance of the overall time difference between the two techniques (94.3 seconds) is obvious and the time to intubation should be important in critically ill patients with minimal oxygen reserves. However, a previous study determined 19 seconds to be clinically significant for endotracheal intubation with various devices or techniques⁽⁸⁾. Finally, all intubation attempts were successful but difficult airway scenarios significantly required more times to accomplish even the assisting of the additional suitable device were

Table 1. Conclusions of the assessment in this training of 32 medical students participated

Intubation training	Mean laryngeal orifice visualization time after DL insertion in second mean (SD)	Mean intubation time after laryngeal orifice visualization in second mean (SD)	Time for intubation in second mean (SD)	Cormack-Lehane grading grade I:II:III	Numbers of second attempt (percentage)
Oral intubation with DL	21.7 (8.6)	11.0 (5.7)	32.7 (13.8)	16:16:0	5 (16%)
FSSC assisted nasal intubation	86.8 (23.1)	40.2 (16.1)	127.0 (32.6)	8:24:0	5 (16%)

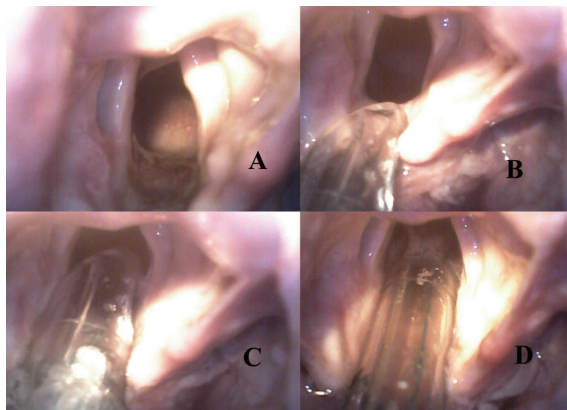


Fig. 3 A, B, C and D) The DL retracted the epiglottis and elevated the larynx off the pharyngeal wall, while the endotracheal tube pressed the interarytenoid notch, and then passed through the vocal cords under visual monitoring of the FSSC

performed. Three devices (DL, FSSC and Endotracheal tube) had to be synchronized: the DL retracted the epiglottis and elevated the larynx off the pharyngeal wall, while the endotracheal tube pressed the interarytenoid notch and then passed through the vocal cords under visual monitoring of the FSSC (Fig. 3). The students had to work as a team to complete the task in time and they did it quite well.

The video screen of the video assisted device offers an advantage in difficult airways because it allows visualization of the vocal cords, and thus enables manipulation of the endotracheal tube in a specific direction. Other video-assisted laryngoscopes, such as the GlideScope video laryngoscope (Verathon Inc, Bothell, Washington, USA), are designed to provide a view of the glottis without alignment of the oral, pharyngeal, and tracheal axes. Such devices have yielded results superior to standard DL in difficult airways in terms of laryngeal view, ease of operation, and faster time to intubation⁽⁹⁻¹²⁾. Another video assisted device, the Airtraq (Prodol, Noblesville, IN, USA), also performed superiorly to DL in difficult airways⁽¹⁸⁾. The FSSC is superior to some other video assisted devices having built-in screen in that the laptop monitor displays the procedure for all personal, it is not confined to the operator. The FSSC not only can assist the DL to cope with difficult airways but also can be utilized as confirmation method for correct intubation. After intubation, the FSSC can be used to recognize the aryepiglottic folds surrounding the tube and to confirm the tube position in the larynx. Like

other video assisted devices that are commercially available, the FSSC is practical for assisting difficult intubation when laryngoscopic view is inadequate. The authors hope that the authors can develop conceptual understanding and increasing procedural skills in endotracheal intubation of the medical students. The advantage of the video assisted device is mostly logistical and practical and lies in its compact size, durability, and ability to view the video screen from any direction. No single airway device is superior to others in all airway scenarios, but video assisted devices may offer an advantage in the difficult airway where oropharyngo-tracheal axis alignment is not possible.

Since the authors have launched this campaign for increasing procedural skills in endotracheal intubation and other procedures for the undergraduate students, they have realized that the procedural trainings in cadavers is the crucial step for medical education that facilitates learning processes for gaining physician's competency not an option that could be omitted or selected. The authors have realized that the cadavers provide excellent real life clinical situations better than manikins even in cardiopulmonary resuscitation training. Not only the anatomy of the human cadavers is real but the consistency of the tissues is also real too. Moreover, the muscular tone is flaccid and the cadaver lies still, so every procedure can be trained slowly and steadily with full confidence. The process can be repeated until the participants gain specific hands-eyes coordination of the procedure and the procedural steps flow automatically. The authors have also realized that the medical students can almost gain complicated procedural skills as good as the emergency residents. Many procedural skills training such as the intubation training is not a destructive procedure. All the cadavers are still in good condition after the training session. The authors found only a mucosal tear of the right anterior tonsillar pillar. On the other hand, all the surgical training procedures that the authors have arranged were very destructive. Therefore, that part of the body and sometimes other nearby parts and structures cannot be utilized for a second time after the workshops.

The airways that emergency physicians manage in the ED tend not to be as difficult as those that paramedics encounter in out-of-hospital settings. Some obstacles include suboptimal patient positioning, inadequate lighting, limited space, or extreme ambient temperatures. The authors plan to

arrange hands-on cadaver intubation workshops for paramedics all over the country, both in private sectors and in the government hospitals. The authors hope that this move may increase survival rates of the victims and enhance our health care facilities. Finally, the present study was performed under simulated conditions and may not represent the out-of-hospital setting with cervical spine concerns, adverse environment, poor lighting, or patient-positioning problems. However, these simulations may be suitable for the beginners to develop the basic clinical procedural skills.

Conclusion

The medical students have the ability to accomplish a basic clinical task after a short hands-on training workshop.

Potential conflicts of interest

None.

References

1. Moss F, McManus IC. The anxieties of new clinical students. *Med Educ* 1992; 26: 17-20.
2. Peyre SE, Peyre CG, Sullivan ME, Towfigh S. A surgical skills elective can improve student confidence prior to internship. *J Surg Res* 2006; 133: 11-5.
3. Sammann A, Tendick F, Ward D, Zaid H, O'Sullivan P, Ascher N. A surgical skills elective to expose preclinical medical students to surgery. *J Surg Res* 2007; 142: 287-94.
4. Stewart RA, Hauge LS, Stewart RD, Rosen RL, Charnot-Katsikas A, Prinz RA. A CRASH course in procedural skills improves medical students' self-assessment of proficiency, confidence, and anxiety. *Am J Surg* 2007; 193: 771-3.
5. Zaid H, Ward D, Sammann A, Tendick F, Topp KS, Maa J. Integrating surgical skills education into the anatomy laboratory. *J Surg Res* 2010; 158: 36-42.
6. Barrett SV, Zapka JG, Mazor KM, Luckmann RS. Assessing third-year medical students' breast cancer screening skills. *Acad Med* 2002; 77: 905-10.
7. Ault GT, Sullivan M, Chalabian J, Skinner KA. A focused breast skills workshop improves the clinical skills of medical students. *J Surg Res* 2002; 106: 303-7.
8. Practice guidelines for management of the difficult airway: an updated report by the American Society of Anesthesiologists Task Force on Management of the Difficult Airway. *Anesthesiology* 2003; 98: 1269-77.
9. Lim Y, Yeo SW. A comparison of the GlideScope with the Macintosh laryngoscope for tracheal intubation in patients with simulated difficult airway. *Anaesth Intensive Care* 2005; 33: 243-7.
10. Cooper RM, Pacey JA, Bishop MJ, McCluskey SA. Early clinical experience with a new videolaryngoscope (GlideScope) in 728 patients. *Can J Anaesth* 2005; 52: 191-8.
11. Kaplan MB, Hagberg CA, Ward DS, Brambrink A, Chhibber AK, Heidegger T, et al. Comparison of direct and video-assisted views of the larynx during routine intubation. *J Clin Anesth* 2006; 18: 357-62.
12. Xue FS, Zhang GH, Liu J, Li XY, Yang QY, Xu YC, et al. The clinical assessment of Glidescope in orotracheal intubation under general anaesthesia. *Minerva Anestesiol* 2007; 73: 451-7.

การใส่ท่อช่วยหายใจด้วยกลองลักษณะคล้ายงูในการฝึกหัดการในอาจารย์ใหญ่สำหรับนิสิตแพทย์ระดับปริคินิกเพื่อเตรียมความพร้อมในการปฏิบัติงานบนหอผู้ป่วย

ธันวา ตันสถิตย์, ประวิทย์ อภินันท์ธรรม, ถาวร เพชรอุดม

วัตถุประสงค์: การเตรียมนิสิตแพทย์ให้พร้อมสำหรับการทำหัตถการเฉพาะในผู้ป่วยที่มีความท้าทายในด้านความมั่นใจของนิสิตในการทำหัตถการเหล่านั้น การศึกษาเชิงบรรยายนี้ทำเพื่อประเมินความสามารถของนิสิตที่จะทำหัตถการให้สำเร็จหลังจากผ่านการฝึกหัตถการนั้นในระยะสั้นกับอาจารย์ใหญ่ การฝึกอบรมหัตถการพื้นฐานนี้เป็นความตั้งใจที่จะพัฒนาความเข้าใจแก่นแท้และเพิ่มทักษะของหัตถการการใส่ท่อช่วยหายใจของนิสิตแพทย์

วัสดุและวิธีการ: นิสิตได้รับการฝึกให้ทำหัตถการการใส่ท่อช่วยหายใจ 2 แบบที่แตกต่างกัน คือ การใส่ท่อช่วยหายใจแบบปกติ และการใส่ท่อช่วยหายใจแบบยากในสถานะการณของผู้ป่วยบาดเจ็บ คาบของการฝึกอบรมประกอบด้วย การใส่ท่อช่วยหายใจทางปากในผู้ป่วยปกติด้วยเครื่องส่องกล้องเสียงแบบตรงในอาจารย์ใหญ่ 2 ร่าง และการใส่ท่อช่วยหายใจทางจมูกด้วยกลองลักษณะคล้ายงูในอาจารย์ใหญ่ 2 ร่าง ที่จำลองสถานะการณผู้ป่วยบาดเจ็บมีทางเดินหายใจที่ใส่ท่อช่วยหายใจได้ยาก ในคาบการประเมินผลการฝึกอบรมนิสิตแสดงการใส่ท่อช่วยหายใจทั้งสองแบบแบบละ 1 ครั้ง โดยทำในร่างอาจารย์ใหญ่ที่เปลี่ยนทั้งหมด กลุ่มของนิสิตแพทย์ถูกสุ่มให้ทำในอาจารย์ใหญ่ท่านหนึ่งในสองท่านในแต่ละแบบ

ผลการศึกษา: นิสิตจำนวน 32 คน ได้เข้าร่วมการฝึกอบรมและการประเมินผลการอบรม คาบการฝึกอบรมใช้เวลา 5 ชั่วโมง และการประเมินกินเวลา 3 ชั่วโมง ไม่มีนิสิตที่ถูกให้ทำการใส่ท่อช่วยหายใจเป็นครั้งที่สอง ผลของการประเมินได้บรรยายสรุปไว้ เวลาเฉลี่ยของการใส่ท่อช่วยหายใจทางปากด้วยเครื่องส่องกล้องเสียงแบบตรงสำเร็จ คือ 32.7 วินาที ค่าเบี่ยงเบนมาตรฐาน 13.8 วินาทีและเวลาเฉลี่ยของการใส่ท่อช่วยหายใจทางจมูก โดยกลองลักษณะคล้ายงูเท่ากับ 127.0 วินาที ค่าเบี่ยงเบนมาตรฐาน 32.6 วินาทีในการทดลองครั้งนี้ ไม่มีความล้มเหลวของการใส่ท่อช่วยหายใจ

สรุป: นิสิตแพทย์ระดับปริคินิกมีความสามารถในการทำหัตถการพื้นฐานด้านคลินิกภายหลังจากการฝึกอบรมเชิงปฏิบัติการระยะสั้น
