

Case Report

Painless Thyroiditis Complicating with Hypercalcemic Encephalopathy

Yotsapon Thewjitcharoen MD*,
Nuttha Lumlertgul MD*

* Department of Medicine, Faculty of Medicine, Chulalongkorn University, Bangkok, Thailand

Background: Severe hypercalcemia has rarely been reported in patients with hyperthyroidism. Although the pathogenesis is not clear, it is believed to be due to activation of osteoclasts resulting in excessive bone resorption.

Objective: To recognize the unusual cause of hypercalcemia from painless thyroiditis, which could manifest with transient hyperthyroidism in the early stage.

Case Report: A 70-year-old woman presented with watery diarrhea, nausea and vomiting and significant weight loss for two months. Initially, she was misdiagnosed as having Graves' disease from her clinical presentation and thyroid function tests. Oral propylthiouracil was given to treat hyperthyroidism. However, two weeks after discharge, she developed altered consciousness due to severe hypercalcemia. After combined treatment of hypercalcemia and severe hyperthyroidism, her symptoms resolved quickly. Later on, her thyroid function tests switched to subclinical hypothyroid at two months after initial presentation. No concurrent pathological conditions could be found to explain the other causes of hypercalcemia. Therefore, painless thyroiditis complicated with severe hypercalcemia was subsequently diagnosed based on her clinical course.

Conclusion: Hypercalcemic encephalopathy is an uncommon manifestation of hyperthyroidism that should be kept in mind in patients who demonstrated clinical pictures of hyperthyroidism and alteration of consciousness. Moreover, the present case emphasizes the consideration of painless thyroiditis as a differential diagnosis of hyperthyroidism because anti-thyroid medications were not indicated in this condition.

Keywords: Painless thyroiditis, Hypercalcemic Encephalopathy, Hyperthyroidism, Hypercalcemia

J Med Assoc Thai 2012; 95 (1): 119-23

Full text. e-Journal: <http://www.jmat.mat.or.th>

Hyperthyroidism is associated with laboratory hypercalcemia in about 11 to 52% of patients^(1,2). Although the pathogenesis is not clear, it is believed to be due to activation of osteoclasts resulting in excessive bone resorption and blunting of intestinal calcium absorption from suppression of PTH and 1, 25-dihydroxy vitamin D⁽³⁾. Severe hypercalcemia has rarely been reported in patients with hyperthyroidism⁽⁴⁻⁹⁾. The authors report a 70-year-old female who presented with life-threatening hypercalcemia after initial treatment of severe hyperthyroidism for two weeks. Hypercalcemia was proved to be caused by hyperthyroidism alone and she was successfully treated with combination treatment of severe hyperthyroidism and hypercalcemia. The authors also discuss the etiology of her

hyperthyroid and the possible mechanism of this unusual manifestation.

The present case report was approved by the Institutional Review Board of Faculty of Medicine, Chulalongkorn University.

Case Report

A previously healthy 70-year-old woman presented with watery diarrhea, nausea and vomiting, low-graded fever and 14-kilogram weight loss for two months. In March 2010, she was first admitted in Chulalongkorn Hospital to work up for the cause of chronic diarrhea and recurrent vomiting. Her physical examination showed only temporalis muscle wasting and coarse hair, while others including thyroid gland were unremarkable. Her initial pulse rate was 110 per min with regular rhythm. There was no family history of thyroid disorder. Biochemical tests, however, revealed severe hypokalemia (plasma potassium 2.4 mmol/L) and the presence of very high concentrations of thyroid hormones (TSH < 0.005 mU/mL [normal range, 0.3-4.1],

Correspondence to:

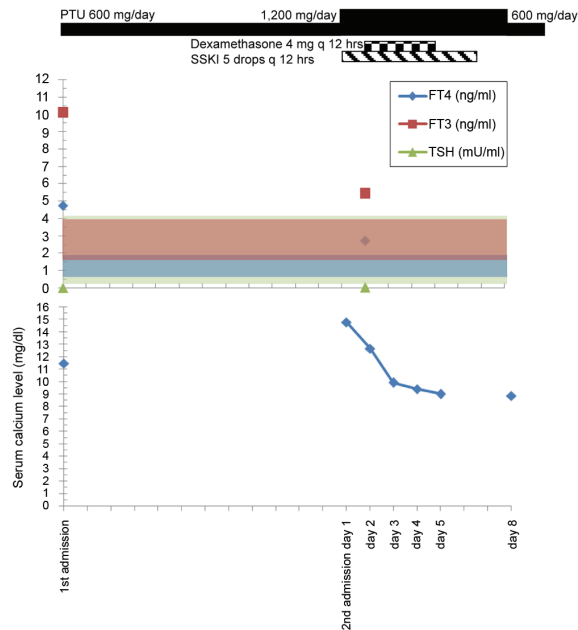
Thewjitcharoen Y, Department of Internal Medicine, Faculty of Medicine Chulalongkorn University, Rama IV Rd, Bangkok 10330, Thailand.

Phone: 0-2256-4246

E-mail: kamijoa@hotmail.com

FT3 10.08 pg/mL [1.6-4], FT4 4.73 ng/dL [0.8-1.8]). Her initial corrected serum calcium was 11.4 mg/dL [8.6-10.3 mg/dL] (Table 1). Hyperthyroidism was diagnosed based on her clinical presentation and thyroid function tests. No thyroid antibodies, ESR, serum thyroglobulin were measured in this admission. Neither ultrasound of thyroid gland nor radio-iodine uptake was done. She was presumably diagnosed with Graves' disease. Oral propylthiouracyl 200 mg/day and propranolol 20 mg/day were given to control her hyperthyroid. Symptoms of nausea, vomiting, and diarrhea disappeared completely within a few days after treatment.

Two weeks later after the discharge from Chulalongkorn Hospital, her daughter started to notice her gradual confusion and hallucination. She also complained of diffuse headache and recurrent vomiting again after completely remission from the last admission. On the day of the second admission (April 12, 2010), she was drowsy and barely talked. She developed sudden high-grade fever, diarrhea and vomiting. On this admission, she was drowsy and markedly dehydrated. Her body temperature was 39.6°C, pulse rate 100/min and regular, respiratory rate 24/min and blood pressure 114/66 mmHg. Her other physical findings were within normal limits. The initial laboratory tests revealed severe hypercalcemia (corrected serum calcium was 14.7 mg/dL, serum album 3.2 g/dL) and mild hyperthyroid (TSH 0.015 mU/mL, FT3 5.41 pg/mL, FT4 2.72 ng/dL). The results of laboratory investigations are summarized in Table 1 and Fig. 1 respectively. Random serum cortisol, which was measured before the initiation of steroid treatment, was 32 µg/dL. Computer Tomography of brain was normal and CSF analysis revealed no cell with normal levels of protein and sugar. She was then diagnosed with hypercalcemic encephalopathy. She was treated with vigorous intravenous hydration. Due to her history of hyperthyroidism and symptoms that suggested thyroid crisis, she was also treated



- FT4 (ng/dL)[normal range: 0.8-1.8], FT3 (pg/mL) [normal range: 1.6-4.0], and TSH (mU/mL) [normal range: 0.3-4.1
 - SSKI and PTU indicate saturated solution of potassium iodide and propylthiouracil, respectively

Fig. 1 Clinical course of this patient with the demonstration of serum calcium levels (mg/dL) in relation with FT4 (ng/dL), FT3 (pg/mL) and TSH (mU/mL)

as thyroid crisis although there was no obvious precipitating cause. Oral propylthiouracyl (1,200 mg/day), potassium iodide solution, and intravenous dexamethasone (8 mg/day) were started in the first day of this admission. She regained consciousness after two days of treatment. Her serum calcium gradually fell down to the normal level within four days after treatment. No steroid was given after complete four days of intravenous dexamethasone.

Subsequently, her intact parathyroid hormone level by electrochemiluminescence immunoassay

Table 1. Laboratory data on first and second admission

Day of admission	First admission	Second admission					Six-month follow-up	Normal range
		1	2	3	4	5		
Corrected Ca (mg/dL)	11.44	14.74	12.64	9.90	9.40	9.00	9.50	8.6-10.3
FT4 (ng/dL)	4.73	2.72	-	-	-	-	1.00	0.8-1.8
FT3 (pg/mL)	10.08	5.41	-	-	-	-	2.43	1.6-4.0
TSH (mU/mL)	<0.005	0.015	-	-	-	-	12.98	0.3-4.1

revealed the level of 7.3 pg/mL (15-65), which was appropriately suppressed. Anti-thyroperoxidase and anti-thyroglobulin were 12.55 IU/mL (< 5.61) and 102.42 IU/mL (< 4.11), respectively. Anti-TSH receptor antibody by electrochemiluminescence immunoassay (second generation assays using coated plate, Cobas®) was negative. She was discharged on propylthiouracyl 600 mg/day, which was tapered off rapidly within two months during her subsequent visits because of development of subclinical hypothyroidism in June 2010 (TSH 10.12 mU/mL, FT3 2.15 pg/mL, FT4 0.91 ng/dL). Control of the patient's hyperthyroidism led to a complete relief of symptoms and restoration of her normal weight. The symptoms did not recur and her plasma calcium has remained normal during follow-up for the past 6 months. Her recent thyroid function tests revealed subclinical hypothyroidism without taking any medication. Possible diagnosis of painless thyroiditis or silent thyroiditis was suspected based on her subsequent clinical course and slightly elevated of anti-thyroid antibodies. Unfortunately, radio-iodine uptake was not done in the present patient to confirm the nature of thyroiditis.

Discussion

In hyperthyroidism the rate of bone formation and resorption are both accelerated but the bone resorption usually predominates over bone formation. As a result, significantly higher serum calcium level could be found in some hyperthyroid patients, but usually mild (< 10.8 mg/dL)^(1,2,7). Rarely, the calcium level may be severe enough to cause symptomatic hypercalcemia. In the case presented here, her initial presentation was mainly gastrointestinal symptoms, which came from the direct effect of thyroid hormone⁽¹⁰⁾. In elderly patients, severe hyperthyroidism may occasionally present with few classical symptoms. Her serum calcium in the first admission was mildly elevated (serum calcium 11.4 mg/dL), which could be found up to 25% of uncontrolled hyperthyroid patients⁽¹⁾. She was misdiagnosed as Graves' disease and oral propylthiouracil was given inappropriately to control her hyperthyroidism. Among patients with hyperthyroidism, less common causes such as painless thyroiditis accounts for only about 1 to 10%. They should be considered in patients who had symptoms for less than two months and no thyroid enlargement was found on physical examination^(11,12). Furthermore, serum FT3 concentration is not dominantly high when compared with serum FT4 concentration, reflecting the release of preformed

thyroid hormone from the damaged thyroid gland rather than hypersecretion of active thyroid hormone as seen in Graves' disease. Her gastrointestinal symptoms disappeared rapidly after discharge from the first admission might be explained from symptomatic treatment with beta-blocker rather than the effect of anti-thyroid medication.

However, after two weeks the patient came back with altered consciousness, which the nature of fluctuation suggested metabolic causes. Severe hypercalcemia was found unexpectedly even though her thyroid function tests were much improved when compared with the first admission. When a raised plasma calcium is found in a case of hyperthyroidism, hyperparathyroidism must be considered and excluded before attributing that cause of hypercalcemia solely from hyperthyroidism⁽¹³⁾. The presented patient's serum intact parathyroid hormone was below normal and there were no other signs of malignancy. No history of bone or renal disease could account for hypercalcemia in the presented patient. The possibility of hypercalcemia from adrenal insufficiency was also excluded based on the level of random serum cortisol in the presented patient. After initiating treatment with vigorous hydration and control of hyperthyroidism, her conditions quickly recovered and the serum calcium level rapidly decreased. This might help conclude that hypercalcemia is solely from hyperthyroidism, not from concurrent pathological conditions. Due to the severity of her second admission, thyroid storm was also suspected from unexplained fever, sinus tachycardia, central nervous symptoms and gastrointestinal disturbances. These cumulated to 65 points in Burch and Wartofsky scoring system⁽¹⁴⁾, which prompts urgent management as thyroid crisis. Retrospectively, this patient might not have the true thyroid crisis because hypercalcemia alone can cause altered consciousness. Therefore, anti-thyroid medications should not be given to control her hyperthyroidism. The cause of paradoxical worsening of symptoms after initial improvement of her symptoms and thyroid function tests remained to be determined. Even though dehydration could be the potentiated factor in severity of hypercalcemia, this factor alone is unlikely to explain the level of serum calcium in the second admission. Corticosteroid and beta-blocker was suspected to be the responsible factors in relieving symptoms of this patient rapidly on the second admission.

Severe hypercalcemia was rarely reported in patients with hyperthyroidism with the highest level of 15.8 mg/dL in the previous literature⁽³⁾. The

excessively high level of calcium may be further explained by the patient's marked dehydration from recurrent vomiting. To the best of the authors' knowledge, there has been no previous case report of painless thyroiditis complicated with hypercalcemic encephalopathy as the authors described in the presented case. The authors also considered the possibility of Encephalopathy Associated with Autoimmune Thyroid Disease (EAATD), formerly named Hashimoto's encephalopathy⁽¹⁵⁾, as a cause for the patient's altered mental status. Because Hashitoxicosis and painless thyroiditis with transient hyperthyroidism share many similar characteristics including autoimmune in basis, and pathological basis, it would be difficult to determine the etiology of hyperthyroidism when the patient was encountered for the first time⁽¹⁶⁾. The main clinical features of Hashimoto's encephalopathy are altered consciousness, seizures, psychiatric symptoms, high proteins level in CSF fluid and often associated with the high titer of anti-thyroid antibodies. Patients with Hashimoto's encephalopathy dramatically respond with steroid treatment in a few days of therapy, however, relapse rates are high and most patients require careful dose tapering to withdraw from steroid treatment in the duration of 1 to 2 years. However, the presented patient's CSF protein did not increase as in 78% of these patients⁽¹⁷⁾ and she responded quickly after treatment of hypercalcemia and which is in contrast with the majority of EAATD patients who have dramatic responses to steroids with high rates of relapses after steroids withdrawal. Therefore, the presented patient's encephalopathy seemed to fit with hypercalcemic crisis from hyperthyroidism rather than Hashimoto's encephalopathy.

In conclusion, the authors report an unusual case of severe hypercalcemia associated with transient hyperthyroidism from severe painless thyroiditis, which developed encephalopathy after treatment of hyperthyroidism for two weeks. Serum calcium returned to normal level after a euthyroid state had been achieved. Hypercalcemic encephalopathy is an uncommon manifestation of hyperthyroidism from any cause that should be kept in mind in patients who demonstrate clinical pictures of hyperthyroidism and alteration of consciousness. Moreover, the presented case also emphasizes the consideration of painless thyroiditis as a differential diagnosis of hyperthyroidism because patients might receive inappropriate treatment from anti-thyroid medications.

Acknowledgement

The authors gratefully thank the patient and her daughter who permitted us to publish this case. A written informed consent was obtained for publication of this case report.

Potential conflicts of interest

None.

References

1. Mosekilde L, Eriksen EF, Charles P. Effects of thyroid hormones on bone and mineral metabolism. *Endocrinol Metab Clin North Am* 1990; 19: 35-63.
2. Iqbal AA, Burgess EH, Gallina DL, Nanes MS, Cook CB. Hypercalcemia in hyperthyroidism: patterns of serum calcium, parathyroid hormone, and 1,25-dihydroxyvitamin D3 levels during management of thyrotoxicosis. *Endocr Pract* 2003; 9: 517-21.
3. Harper PS, Hughes RO. Severe hypercalcaemia from hyperthyroidism with unusual features. *Br Med J* 1970; 1: 213-4.
4. Bauman A, Rosen K. Recurrent hypercalcemia associated with recurrent hyperthyroidism with and without symptoms. *N Y State J Med* 1964; 64: 1938-44.
5. Twycross RG, Marks V. Symptomatic hypercalcaemia in thyrotoxicosis. *Br Med J* 1970; 2: 701-3.
6. Woodhouse NJ, Hoare A, Mohamedally SM, Marsden P. Thyrotoxicosis and hypercalcaemia: response to antithyroid drugs and salmon calcitonin. *Horm Res* 1976; 7: 238-46.
7. Hedman I, Tisell LE. Life-threatening hypercalcemia in a case of thyrotoxicosis: clinical features and management. A case report. *Acta Chir Scand* 1985; 151: 487-9.
8. Alikhan Z, Singh A. Hyperthyroidism manifested as hypercalcemia. *South Med J* 1996; 89: 997-8.
9. Chow KM, Szeto CC. An unusual cause of hypercalcemia. *South Med J* 2004; 97: 588-9.
10. Ghose RR, Palmer DJ, Yaqoob M, Haboubi N, Ratcliffe WA. Abdominal symptoms, hypercalcaemia and apathetic hyperthyroidism: treatment with pamidronate. *Br J Clin Pract* 1994; 48: 163-4.
11. Gordon M. "Silent" thyroiditis with symptomatic hyperthyroidism in an elderly patient. *J Am Geriatr Soc* 1978; 26: 375-7.
12. Pearce EN, Farwell AP, Braverman LE. Thyroiditis. *N Engl J Med* 2003; 348: 2646-55.
13. Richards AJ. Hypercalcaemia in thyrotoxicosis

- with and without hyperparathyroidism. Postgrad Med J 1970; 46: 440-6.
14. Burch HB, Wartofsky L. Life-threatening thyrotoxicosis. Thyroid storm. Endocrinol Metab Clin North Am 1993; 22: 263-77.
 15. Canton A, de Fabregas O, Tintore M, Mesa J, Codina A, Simo R. Encephalopathy associated to autoimmune thyroid disease: a more appropriate term for an underestimated condition? J Neurol Sci 2000; 176: 65-9.
 16. Woolf PD. Transient painless thyroiditis with hyperthyroidism: a variant of lymphocytic thyroiditis? Endocr Rev 1980; 1: 411-20.
 17. Tamagno G, Celik Y, Simo R, Dihne M, Kimura K, Gelosa G, et al. Encephalopathy associated with autoimmune thyroid disease in patients with Graves' disease: clinical manifestations, follow-up, and outcomes. BMC Neurol 2010; 27: 1-8.

รายงานผู้ป่วยต่อมไทรอยด์อักเสบชนิดไม่มีอาการปวดที่มีภาวะซึมจากระดับแคลเซียมในเลือดสูง

ยศพล เตียวจิตต์เจริญ, ภัฏฐา ล้ำเลิศกุล

ภูมิหลัง: ระดับแคลเซียมในเลือดสูงอย่างรุนแรงในภาวะต่อมไทรอยด์เป็นพิษมีรายงานน้อยมากสาเหตุยังไม่ทราบแน่ชัด แต่เชื่อว่าในภาวะต่อมไทรอยด์เป็นพิษอาจมีการกระตุ้นของเซลล์ osteoclast ทำให้มีการสลายแคลเซียมออกจากกระดูกมากขึ้นกว่าปกติ

วัตถุประสงค์: เพื่อรายงานผู้ป่วยที่น่าสนใจรายหนึ่งที่มีอาการซึมจากระดับแคลเซียมในเลือดสูงที่มีสาเหตุมาจากต่อมไทรอยด์อักเสบชนิดไม่มีอาการปวด ซึ่งอาการซึมจากระดับแคลเซียมในเลือดสูง จากต่อมไทรอยด์เป็นพิษเป็นสาเหตุที่พบบได้น้อยมาก โดยเฉพาะสาเหตุของต่อมไทรอยด์เป็นพิษชั่วคราวที่มาจากต่อมไทรอยด์อักเสบชนิดไม่มีอาการปวด

รายงานผู้ป่วย: ผู้ป่วยหญิงอายุ 70 ปี มาด้วยอาการถ่ายเหลวเป็นน้ำ คลื่นไส้ อาเจียน และน้ำหนักลดอย่างมากในช่วง 2 เดือน ช่วงแรกผู้ป่วยได้รับการวินิจฉัยผิดเป็นโรค Graves' disease จากผลการตรวจระดับฮอร์โมนไทรอยด์ และผู้ป่วยได้รับยาต้านฮอร์โมนไทรอยด์เพื่อรักษาอาการไทรอยด์เป็นพิษ แต่ผู้ป่วยมีอาการซึมลงหลังจากออกจากโรงพยาบาลครั้งแรกไป 2 สัปดาห์ ผลตรวจทางห้องปฏิบัติการเบื้องต้นพบว่าผู้ป่วยมีอาการซึมจากระดับแคลเซียมในเลือดสูงมาก หลังจากให้การรักษาเรื่องระดับแคลเซียมในเลือดสูง และภาวะต่อมไทรอยด์เป็นพิษอย่างรุนแรง อาการผู้ป่วยดีขึ้นอย่างรวดเร็ว และผลตรวจฮอร์โมนไทรอยด์เปลี่ยนกลับมาเป็นภาวะ subclinical hypothyroid หลังรักษาได้ 2 เดือนโดยตรวจไม่พบสาเหตุอื่นที่อธิบายระดับแคลเซียมในเลือดสูง จากการดำเนินโรคทางคลินิกทำให้สงสัยว่าผู้ป่วยน่าจะมีสาเหตุของระดับแคลเซียมในเลือดสูงจากโรคต่อมไทรอยด์อักเสบชนิดไม่มีอาการปวด

สรุป: ภาวะระดับแคลเซียมในเลือดสูงอย่างรุนแรงจนมีอาการทางสมอง เป็นภาวะที่พบบได้ไม่บ่อยในผู้ป่วยที่มีต่อมไทรอยด์เป็นพิษ ดังนั้นแพทย์ทั่วไปจึงควรคิดถึงภาวะนี้ด้วยในผู้ป่วยต่อมไทรอยด์เป็นพิษที่มาด้วยซึมลง นอกจากนี้ ในผู้ป่วยรายนี้ยังแสดงให้เห็นถึงความสำคัญในการพิจารณาแยกโรคของต่อมไทรอยด์เป็นพิษซึ่งอาจมาจากต่อมไทรอยด์อักเสบชนิดที่ไม่มีอาการปวด เนื่องจากภาวะนี้ไม่มีความจำเป็นในการให้ยาต้านไทรอยด์