

Case Report

Metastatic Neuroendocrine Carcinoma of the Breast Identified by Tc-99m-HYNIC-TOC SPECT/CT: A Rare Case Report

Apichaya Claimon MD*, Suebwong Chuthapisith MD**,
Norasate Samarthai MD***, Pawana Pusuwan MD*

* Department of Radiology, Faculty of Medicine Siriraj Hospital, Mahidol University, Bangkok, Thailand

** Department of Surgery, Faculty of Medicine Siriraj Hospital, Mahidol University, Bangkok, Thailand

*** Department of Pathology, Faculty of Medicine Siriraj Hospital, Mahidol University, Bangkok, Thailand

The authors reported an uncommon presentation of metastatic neuroendocrine carcinoma to the breast detected by Tc-99m-HYNIC-TOC SPECT/CT in a 49 years old woman who, previously, had carcinoid tumor of left main bronchus and invasive ductal carcinoma of the right breast. Later, the patient developed left breast mass. Core needle biopsy of the mass revealed poorly differentiated invasive ductal carcinoma. The disease remained stable for 12 years without any treatment on that left breast (due to patient's rejection). On the later investigation using Tc-99m-HYNIC-TOC scintigraphy examination, rather than invasive ductal carcinoma, metastatic neuroendocrine cancer was suggested. The final diagnosis was confirmed by pathological examination after surgical excision. Multiple metastatic lesions of neuroendocrine carcinoma at lung, liver, ovaries, and bones were also depicted. Due to the good behavior of the disease, patient had been doing well for eight months, without specific treatment. This report confirmed the advantage and the accuracy of Tc-99m-HYNIC-TOC scintigraphy in detection of neuroendocrine carcinoma. Furthermore, metastatic neuroendocrine tumor should be in differential diagnosis for patient with breast mass together with history of neuroendocrine tumor.

Keywords: Neuroendocrine, Breast metastasis, SPECT/CT, Technetium-99m-HYNIC-TOC

J Med Assoc Thai 2015; 98 (8): 828-32

Full text. e-Journal: <http://www.jmatonline.com>

Neuroendocrine carcinoma (NEC) occurs in the breast and is defined by the diffuse expression of neuroendocrine (NE) markers. Those could be either primary NEC of breast (comprising 0.5 to 2% of breast carcinoma⁽¹⁾) or neuroendocrine cancer of other organs that spread to the breast. However, this is extremely rare, accounting for 0.1% of breast carcinoma⁽²⁾. When NEC of the breast is diagnosed, 40% is secondary as primary NEC is from other sites⁽³⁾.

In differentiation between primary NEC and metastatic NEC to the breast, tissue pathology and NE marker staining with synaptophysin and/or chromogranin are limited. Further investigation is essential. Conventional anatomical imaging with computed tomography (CT) or magnetic resonance imaging (MRI) may be used. However, functional imaging technology, namely somatostatin receptor scintigraphy (SRS) such as Tc-99m-HYNIC-TOC scintigraphy shows better results⁽⁴⁾. The technique was

recommended for detection, evaluation the extension of the disease, follow-up, determination of distribution and level of somatostatin-receptors (SSTRs) expression, and planning of peptide receptor radionuclide therapy (PRRT) for neuroendocrine tumors⁽⁵⁾.

The authors reported a rare case of metastatic NEC to breast with multiple lung, liver, ovaries, and osseous metastases detected by Tc-99m-HYNIC-TOC scintigraphy and reviewed literature.

Case Report

A 49-year-old woman with history of carcinoid tumor of left main bronchus (treated by sleeve resection of left upper lobe) 19 years ago, and history of invasive ductal carcinoma of the right breast (treated by modified radical mastectomy and adjuvant chemotherapy) 15 years ago, presented with a palpable breast mass on her left breast 12 years ago. The mass was 1.8 cm in size and was biopsied. The pathological examination revealed poorly differentiated invasive ductal carcinoma (IDC). Liver ultrasonography and bone scan suggested liver and osseous metastases. The patient refused treatment and was lost to follow-up after one course of chemotherapy due to intolerance

Correspondence to:

Claimon A, Division of Nuclear Medicine, Department of Radiology, Faculty of Medicine Siriraj Hospital, Mahidol University, 2 Prannok Road, Bangkok Noi, Bangkok 10700, Thailand.
Phone: +66-2-4196234, Fax: +66-2-4127165
E-mail: apich214@gmail.com

of toxicity. One year ago, she had significant weight loss, thyrotoxicosis, and acromegaly. Further investigation with MRI revealed infiltrative mass lesion along infundibulum and left side of pituitary, suggestive of pituitary macroadenoma. Her hormonal tests showed increased growth hormone (GH), prolactin (PRL), and adrenocorticotrophic hormone (ACTH) levels. She underwent transphenoidal approach with tumor removal and gross pathology revealed three pieces of soft dark brown and gray white tissues, of about 0.5 cm each. Histopathology and immunohistochemistry diagnosed pituitary adenoma with positive GH of most tumor cells, positive PRL of some tumor cells, and scattering positive ACTH.

Subsequently, Tc-99m-HYNIC-TOC scintigraphy was ordered to evaluate evidence of either other ACTH-producing carcinoid tumor or multiple endocrine neoplasia. The study showed a 1.8 cm intense radiotracer uptake at left breast mass with calcification (Fig. 1). Other abnormal increased uptake areas were seen at posterior basal segment of lower lobe of the right lung, segment 4 of liver, bilateral enlarged ovaries and multiple bone lesions that showed mixed osteolytic-blastic lesions on CT images (Fig. 2). All findings were compatible with metastatic malignant neuroendocrine carcinoma.

Since the breast mass was the most accessible site for tissue confirmation compared to the other areas of Tc-99m HYNIC-TOC avidity, excisional biopsy of the left breast mass was performed. Pathological finding of the mass revealed a 1.8 cm well-circumscribed tumor with NE morphology. The tumor cells showed uniform cytologic features with finely granular cytoplasm and nuclei with finely granular chromatin. Mitotic count was 0-1 per 10 high power fields. There was no tumor necrosis. By immunostaining, the tumor cells showed diffusely and strongly cytoplasmic positive for chromogranin and synaptophysin. It was neither associated with in situ carcinoma nor other types of invasive breast carcinoma. Based on these findings, the tumor was consistent with well-differentiated NEC (Fig. 3). Additional immunostainings for estrogen receptor (ER) and gross cystic disease fluid protein-15 (GCDPF-15) were negative. The section from core needle biopsy (CNB) of this breast mass, which was previously done 12 years ago, was reviewed and the diagnosis was altered from IDC to well-differentiated NEC.

Change of diagnosis from poorly differentiated invasive ductal carcinoma to metastatic NEC lead to change of treatment. Patient was treated by close

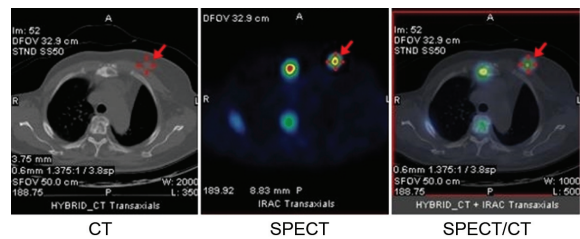


Fig. 1 CT, SPECT, and SPECT/CT fusion images showed increased Tc-99m-HYNIC-TOC at left breast mass at upper inner quadrant (arrow). Other increased uptake foci were seen at sternum, rib and vertebral body, suggestive of osseous metastasis.

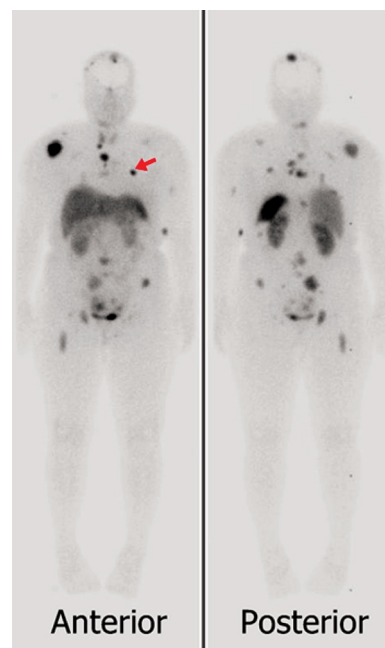


Fig. 2 Anterior and posterior whole-body planar images showed multiple areas of Tc-99m-HYNIC-TOC avidity. A focal increased uptake at anterior left chest located at left breast mass was noted (arrow). Multiple metastases were seen at lung, liver, ovaries and bones.

observation and did not receive any specific treatment because the tumor was well-differentiated. After 8 months of follow-up, there was no evidence of disease progression and she had been doing well.

Discussion

Palpable breast mass is one of the most common presentation of breast cancer. To evaluate breast mass, various techniques of morphological (anatomical) imaging are used, e.g., ultrasonography,

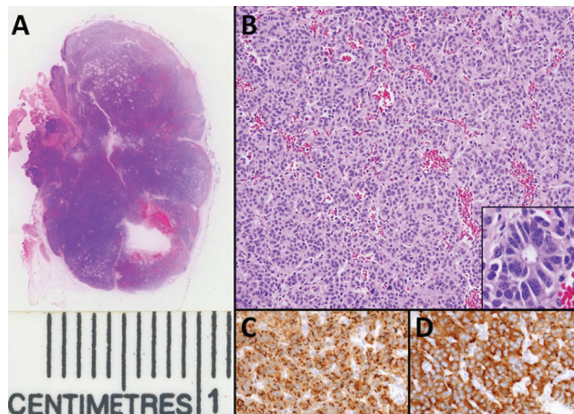


Fig. 3 Whole-mount section of carcinoid tumor excised from left breast showed a 1.8 cm well-demarcated mass (A). Tumor cells grew in an organoid nesting arrangement with a fine vascular stroma; no necrosis was present (H&E stained, original magnification x100). Inset displayed rosette formation of tumor cells (H&E stained, original magnification x400) (B). By immunostaining, the tumor cells showed diffuse and strong cytoplasmic chromogranin (C) and synaptophysin (D) staining (original magnification x200).

mammography, or MRI. Functional (molecular) imaging such as somatostatin receptor scintigraphy (SRS) is not often used, unless NEC is suspected.

Pathological diagnosis of breast NE tumor is somewhat difficult, especially in patient with small tissue sample e.g., from CNB. Perry et al described that 44% of metastatic NEC to the breast was initially misdiagnosed as primary breast cancer⁽⁶⁾. The reasons for misinterpretation include relative rarity of the disease and morphological similarity of primary and secondary tumors⁽⁶⁾. Practically, the mammary carcinomas with NE morphology should be confirmed by immunohistochemical study for definite diagnosis. At present, positive reactivity for one NE marker e.g., chromogranin, synaptophysin in at least 50% of the tumor cells is required for the diagnosis of invasive NE breast carcinoma⁽⁷⁾ as our reported case. By definition, the mammary NECs appear morphologically similar to NE tumors of the lung and gastrointestinal tract. Thus, primary and metastatic mammary NEC are not easy to differentiate. Microscopically, in situ carcinoma and other types of breast cancer are not identified in concert with negative results of immunostains for ER and GCDFP-15. These histomorphologic and immunophenotypic expression findings suggest a metastatic NEC. Moreover,

metastatic NEC should be considered if architectural or cytological feature is suspicious of other primary or there is imaging evidence of primary tumor in other organ. The most common organ of primary NEC was gastrointestinal tract, followed by lung⁽⁶⁾.

SRS plays a pivotal role for this issue as part of diagnosis and management plan, according to its high specificity to SSTRs. Positive SRS correlates with presence of SSTRs overexpression, thus this modality is useful for detection of neuroendocrine tumor and their metastases with high sensitivity^(2,8). Tc-99m-HYNIC-TOC proves its promising role over conventional imaging modalities such as CT, and more preferable over In-111-pentetreotide (Octreoscan) due to its better image quality, lower price, lower radiation dose for patient and daily availability^(9,10). Positive study from planar imaging is determined by an area of increased uptake compares to the surroundings⁽¹¹⁾. Single photon emission tomography with CT (SPECT/CT) is a hybrid imaging technique providing more sensitivity (according to better spatial resolution), accurate localization and anatomical details than planar image. SRS can differentiate between primary and secondary breast NE tumor by exclusion of other primary site. Primary breast NE tumors are treated mainly with a surgical approach. Conversely, for metastatic NECs, nothing further needs to be done⁽³⁾.

Interpretation of SRS for a breast tumor is difficult and has potential for false positive result. About 75% of conventional breast cancers have neuroendocrine differentiation and positive for SRS⁽¹²⁾. False positive SRS is also found in benign breast lesions such as fibroadenoma⁽¹¹⁾. False negative is from a small lesion that is below the system resolution or the tumor has low expression of SSTRs. Some patients present physiologic diffuse SRS uptake in bilateral breasts that can obscure a lesion. Other physiologic uptake can be also visualized at pituitary gland, thyroid gland, liver, spleen, and kidneys and excreted into bowel and urinary bladder. Metastatic lesions may also be masked by these physiologic uptakes.

In conclusion, the authors reported a rare case of metastatic NEC to breast and multiple organs. As SRS SPECT/CT is a whole body imaging technique, it has benefit for evaluation of breast mass and distant metastasis with high sensitivity. Furthermore, SRS has impact in correct diagnosis and proper treatment.

What is already known on this topic?

Metastatic neuroendocrine carcinoma (NEC) to breast is an extremely rare condition and is difficult

to diagnose. Without special immunostaining, tissue biopsy from NEC can be falsely interpreted. Somatostatin receptor scintigraphy (SRS, such as Tc-99m-HYNIC-TOC) has advantage over standard investigations, because of its high specificity to somatostatin receptor that overexpress on neuroendocrine tumor cell membrane. SRS is also helpful for discrimination between primary NEC of breast and metastatic NEC to breast.

Recommendation of SRS is well established for neuroendocrine tumor. However, various causes of false positive are known. Sensitivity may be decreased from low expression of somatostatin receptor, small tumor size, and physiological breast uptake. So far, there was no large study about sensitivity and specificity for detection of metastatic NEC to breast by Tc-99m-HYNIC-TOC.

What this study adds?

This report confirmed the high sensitivity, specificity, usefulness, and impact of Tc-99m-HYNIC-TOC scintigraphy in diagnosis of metastatic neuroendocrine carcinoma of the breast. Moreover, other metastatic sites were correctly identified by this modality. Additional SPECT/CT imaging should be done in the same setting for better sensitivity and correct anatomical localization.

For patients with breast mass along with history of neuroendocrine tumor, further investigation with Tc-99m-HYNIC-TOC is recommended.

Acknowledgement

The present study had been financially supported by the “Chalermphrakiat Grant”, Faculty of Medicine Siriraj Hospital, Mahidol University

Potential conflicts of interest

None.

References

1. Eisemann N, Waldmann A, Katalinic A. Epidemiology of breast cancer - current figures and trends. *Geburtshilfe Frauenheilkd* 2013; 73: 130-5.
2. Glazebrook KN, Jones KN, Dilaveri CA, Perry K, Reynolds C. Imaging features of carcinoid tumors metastatic to the breast. *Cancer Imaging* 2011; 11: 109-15.
3. Navrozoglou I, Vrekoussis T, Zervoudis S, Doukas M, Zinovieva I, Fotopoulos A, et al. Primary atypical carcinoid of the breast: a case report and brief overview of evidence. *World J Surg Oncol* 2011; 9: 52.
4. van Essen M, Sundin A, Krenning EP, Kwekkeboom DJ. Neuroendocrine tumours: the role of imaging for diagnosis and therapy. *Nat Rev Endocrinol* 2014; 10: 102-14.
5. Balon HR, Brown TL, Goldsmith SJ, Silberstein EB, Krenning EP, Lang O, et al. The SNM practice guideline for somatostatin receptor scintigraphy 2.0. *J Nucl Med Technol* 2011; 39: 317-24.
6. Perry KD, Reynolds C, Rosen DG, Edgerton ME, Albarracin T, Gilcrease MZ, et al. Metastatic neuroendocrine tumour in the breast: a potential mimic of in-situ and invasive mammary carcinoma. *Histopathology* 2011; 59: 619-30.
7. Brogi E. Mammary carcinomas with endocrine features. In: Hoda SA, Brogi E, Koerner FC, Rosen PP, editors. *Rosen's breast pathology*. 4th ed. Philadelphia, PA: Lippincott Williams & Wilkins; 2014: 667-78.
8. Suchak AA, Millo N, MacEwan R, McEwan AJ. Neuroendocrine differentiated breast carcinoma with pleural metastases using indium-111 octreotide. *Clin Nucl Med* 2009; 34: 74-5.
9. Pusuwan P, Tocharoenchai C, Sriussadaporn S, Muangsomboon K, Poramatikul N, Tiparoj R. Somatostatin receptor scintigraphy in localization of pancreatic neuroendocrine tumors: a preliminary study. *Siriraj Med J* 2011; 62: 53-6.
10. Guggenberg EV, Mikolajczak R, Janota B, Riccabona G, Decristoforo C. Radiopharmaceutical development of a freeze-dried kit formulation for the preparation of [99mTc-EDDA-HYNIC-D-Phe1, Tyr3]-octreotide, a somatostatin analog for tumor diagnosis. *J Pharm Sci* 2004; 93: 2497-506.
11. Wang F, Wang Z, Wu J, Qu W, Yao W, Zhao J, et al. The role of technetium-99m-labeled octreotide acetate scintigraphy in suspected breast cancer and correlates with expression of SSTR. *Nucl Med Biol* 2008; 35: 665-71.
12. van Eijck CH, Krenning EP, Bootsma A, Oei HY, van Pel R, Lindemans J, et al. Somatostatin-receptor scintigraphy in primary breast cancer. *Lancet* 1994; 343: 640-3.

การแพร่กระจายของมะเร็งระบบประสาทต่อมไร้ท่อไปยังเต้านมซึ่งตรวจพบโดยการสแกนด้วยสารเทคนิคเนียม-99 เอ็ม-ไอซนิก-ทอค: รายงานผู้ป่วย

อภิขญา กล้ายมนต์, สืบวงศ์ จุฑาทิสสิทธิ์, นรเศรษฐ์ สมานไทย, ภาวนา ภูสุวรรณ

ผู้พิมพ์ได้รายงานโรคที่พบได้น้อย คือการแพร่กระจายของมะเร็งระบบประสาทต่อมไร้ท่อไปยังเต้านมซึ่งตรวจพบโดยการสแกนด้วยสารเทคนิคเนียม-99 เอ็ม-ไอซนิก-ทอค SPECT/CT ในผู้ป่วยหญิงอายุ 49 ปี ซึ่งมีประวัติเนื้องอกคาร์ซินอยด์ที่หลอดลมใหญ่ด้านซ้าย และ *invasive ductal carcinoma* ของเต้านมขวา ต่อมาผู้ป่วยมีก้อนที่เต้านมด้านซ้าย การตรวจ *core needle biopsy* ให้ผลเป็น *poorly differentiated invasive ductal carcinoma* ซึ่งโรคลังคงไม่เปลี่ยนแปลงภายหลัง 12 ปี ที่ผู้ป่วยไม่ได้รับการรักษาที่จำเพาะต่อก้อนเนื้อเต้านมซ้าย (เนื่องจากผู้ป่วยปฏิเสธการรักษา) การสแกนด้วยสารเทคนิคเนียม-99 เอ็ม-ไอซนิก-ทอค ที่ตรวจในเวลาต่อมาทำให้นักถึงการแพร่กระจายของมะเร็งระบบประสาทต่อมไร้ท่อมากกว่า *invasive ductal carcinoma* และได้ยืนยันการวินิจฉัยจากผลชิ้นเนื้อที่ได้จากการผ่าตัด *excision* นอกจากนี้ภาพสแกนยังพบการแพร่กระจายของมะเร็งระบบประสาทต่อมไร้ท่อไปอวัยวะอื่นด้วย คือ ปอด ตับ รังไข่ และกระดูก เนื่องจากมีการพยากรณ์โรคที่ผู้ป่วยจึงมีอาการปกติจากการติดตามอาการนาน 8 เดือน โดยที่ไม่ได้รับการรักษาที่จำเพาะ รายงานนี้ยืนยันข้อได้เปรียบและความแม่นยำของการตรวจสแกนด้วยสารเทคนิคเนียม-99 เอ็ม-ไอซนิก-ทอค เพื่อตรวจโรคมะเร็งระบบประสาทต่อมไร้ท่อ นอกจากนี้การแพร่กระจายของเนื้องอกระบบประสาทต่อมไร้ท่อควรอยู่ในการวินิจฉัยแยกโรคในผู้ป่วยที่มีก้อนที่เต้านมและมีประวัติเนื้องอกระบบประสาทต่อมไร้ท่อร่วมด้วย
