

# Computerized Tomographic Angiography for Detection of Cerebral Vasospasm after Ruptured Intracranial Aneurysm

Jiranan Namyong MD\*, Thaweesak Aurboonyawat MD\*, Ekawut Chankaew MD\*,  
Orasa Chawalparit MD\*\*, Sirion Tritrakam MD\*\*, Prajak Srirabheebhat MD\*,  
Varisa Wongbhanuwich MD\*, Dittapong Songsaeng MD\*\*, Julalak Boonma BSc\*\*

\* Division of Neurosurgery, Department of Surgery, Siriraj Hospital, Bangkok, Thailand

\*\* Department of Radiology, Siriraj Hospital, Bangkok, Thailand

**Objective:** Digital subtraction angiography (DSA) is the gold standard to diagnose cerebral vasospasm but it is usually not available due to lack of expertise and proper equipment. The present study aimed to compare the diagnostic accuracy of brain computerized tomographic angiography (CTA) in detecting cerebral vasospasm after intracranial aneurysmal rupture.

**Material and Method:** Between January 2011 and October 2014, 20 patients who were suspected of cerebral vasospasm after aneurysmal subarachnoid hemorrhage (SAH) were prospectively enrolled. All patients underwent brain CTA and DSA within 24 hours after clinical onset of vasospasm. Separate reviewers independently reviewed the CTA and DSA.

**Results:** Twenty patients were enrolled, including 7 males and 13 females. The patient characteristics did not have any relationship to the incidence of cerebral vasospasm. The CTA finding of vasospasm was well correlated to the DSA finding (Kappa 0.793). Diagnostic accuracy and false negative of the CTA were 90% and 5%, respectively. Sensitivity of the CTA was 94% and specificity was 100%. Positive predictive value of the CTA was 100% and negative predictive value was 66%. The vessels that showed the most correlation between the CTA and DSA findings were left A1 (Kappa 0.684) and left A2 (Kappa 0.663) segments of anterior cerebral artery, and left M1 (Kappa 0.503) segment of middle cerebral artery. Both CTA and DSA can detect mild vasospasm (<50% luminal stenosis) located proximal to the circle of Willis.

**Conclusion:** Compared to the DSA, the CTA can be used for detecting cerebral vasospasm in patients with ruptured intracranial aneurysms with high sensitivity, specificity, and diagnostic accuracy.

**Keywords:** Computerized tomographic angiography (CTA), Cerebral vasospasm, Intracranial aneurysmal rupture, Digital subtraction angiography (DSA)

*J Med Assoc Thai 2015; 98 (8): 804-11*

**Full text. e-Journal:** <http://www.jmatonline.com>

The incidence of subarachnoid hemorrhage (SAH), which caused by ruptured intracranial aneurysm, is six to nine persons/100,000 population/year<sup>(1,2)</sup>. Almost half of the patients expire and 50 to 60% are disabled<sup>(3,4)</sup>. The most common causes of the disability are aneurysmal rebleeding and/or cerebral vasospasm<sup>(5)</sup>. The incidence of angiographic vasospasm is found in 50 to 60% of the patients<sup>(4-6)</sup>. Half of the patients had disability because of the brain ischemia (symptomatic vasospasm)<sup>(3,4)</sup>. Prevention and treatment of cerebral vasospasm including medication and intervention to increase blood flow to the brain showed benefits<sup>(7,8)</sup>.

Diagnostic procedures for detecting cerebral vasospasm have been developed. Transcranial Doppler

ultrasonography (TCD) is used for initial screening. The advantages of this procedure are that it is inexpensive and can be performed daily at the bedside, but it has low sensitivity to detect cerebral vasospasm (sensitivity 45%, specificity 96%)<sup>(9)</sup>. The advantages of the digital subtraction angiography (DSA) are its high accuracy for detecting cerebral vasospasm and capability to perform further interventions such as intra-arterial medication infusion or balloon angioplasty at the same time, but the DSA has to be performed by expert and the patients are at risk of iatrogenic thromboembolism. Computerized tomography angiography (CTA) has been used instead of DSA because of its low cost and availability compared to DSA. Its sensitivity and specificity for detecting cerebral vasospasm are higher than those of TCD (Sensitivity 70 to 90%, specificity 85 to 95%)<sup>(10,11)</sup>. CTA can be done after non-contrast CT and has no risks from arterial catheterization. However, the CTA could not provide further treatment if cerebral vasospasm was detected.

## Correspondence to:

Aurboonyawat T, Division of Neurosurgery, Department of Surgery, Faculty of Medicine Siriraj Hospital, Mahidol University, 2 Prannok Road, Bangkoknoi, Bangkok 10700, Thailand.  
Phone: +66-2-4198003, Fax: +66-2-4113006  
E-mail: [aurboonyawat@gmail.com](mailto:aurboonyawat@gmail.com)

Although the DSA is a gold standard method for detecting cerebral vasospasm, most of the provincial hospitals in Thailand lack the equipment and expertise. Therefore, it is necessary to find another method to replace DSA in the detection of cerebral vasospasm to assist in planning of the treatment and prevention of disabilities for the patients. The authors aim to compare the findings of the CTA to those of the DSA for detecting cerebral vasospasm in the different levels of severity of arterial narrowing.

## **Material and Method**

### ***Population and setting***

A prospective study, all patients who were suspected of cerebral vasospasm after ruptured intracranial aneurysm were enrolled. The data was collected between January 2011 and October 2014. Twenty patients were enrolled. Those included patients who had been treated ruptured intracranial aneurysms within 72 hours after SAH, who never been treated cerebral vasospasm, whose symptoms and/or signs evoked cerebral vasospasm, and who initially presented unconscious, which could not be assessed the apparent signs/symptoms (World Federation of Neurosurgical Societies or WFNS grade 4, 5). All patients' relatives had been informed about the research project by the team of medical and/or nursing care and got the consent protocols. Patients with a history of severe contrast or seafood allergy, patients with renal dysfunction (serum creatinine >1.7), patients with coagulopathy and/or platelets dysfunction that could not be corrected, patients with worsening of symptoms due to hydrocephalus and/or intracranial aneurysm rebleeding that had not been treated, and patients whose the DSA was done after the CTA more than 24 hours, were excluded. The withdrawal or termination criteria were patients whose legal representatives/care givers expressed his/her wish to leave the study, patients with serious symptomatic contrast media allergies, and patients in a state of emergency and/or unstable vital signs.

### ***Intervention***

All included patients underwent brain computer tomographic angiography (CTA: Siemens) with 5-mm-slice-thickness non-contrast imaging and 1.5-mm-slice-thickness of 60-mL-contrast-injected imaging. All images were adjusted to be in an 8-mm-maximum intensity projection (MIP), in multi-planar reconstruction (MPR) view mode, and three dimensions (3D) vascular reconstruction to detect

cerebral vasospasm. The CTA was performed prior to the DSA, which was done within 24 hours.

### ***Images review***

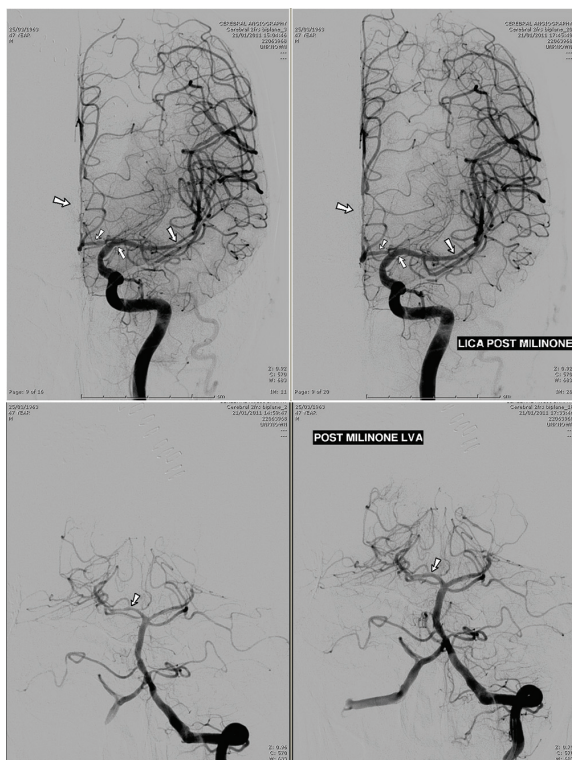
Two neuroradiologists retrospectively analyzed the brain CTA images independently. Fifteen intracranial arterial segments including right and left A1 and A2 segments of anterior cerebral artery (ACA), M1 and M2 segments of middle cerebral artery (MCA), P1 segment of posterior cerebral artery (PCA), supraclinoid part of internal carotid artery (ICA), V4 segment of vertebral artery (VA) and basilar artery (BA) were used to compare with the results from the DSA, which were analyzed by two neuro-interventionists independently. Definition of arterial vasospasm were asymmetrical size of right and left intradural artery at the identical location except ACA, PCA, and VA (for example, both M1 segment should be at the same size), an artery that was not in the usual diameter (usual size of the ICA is usually bigger than the MCA and ACA, respectively, and the size of the BA being bigger than the VA), artery that had delayed parenchymal territories staining in arterial phase (on the DSA), cerebral artery dilatated after intra-arterial vasodilator infusion (Fig. 1), or artery that had obviously difference in diameter after followed-up DSA. The severity of vasospasm from both CTA and DSA was graded according to the diameter of affected vessels, no vasospasm, <50% luminal narrowing, >50% luminal narrowing, and undetermined (arterial hypoplasia, metallic-scatter artifact obscured the border of cerebral vessels, and the artery that was not performed on DSA).

### ***Primary outcome***

To compare the results of brain CTA in detecting cerebral vasospasm and its accuracy to the DSA.

### ***Statistics***

The statistical method used to compare the diagnostic accuracy and correlation between brain CTA and DSA was Kappa (from SPSS version 11.5.0; measure of agreement). The correlation of the arterial segments that were affected vasospasm on the CTA and the DSA was Weighted Kappa (from MedCalc program version 7; linear weight with asymmetrical measure of inter-rater agreement). The strong correlation that depended on the Kappa or Weight Kappa value was near 1.0 (Fisher's exact test is of statistical significance;  $p$ -value <0.05).



**Fig. 1** Illustration of the DSA showed vasospasm at left M2, A1, A2, P1, supraclinoid ICA (white arrows). The vasospasm was confirmed after injection of Milinone 0.1 mg/mL with infusion rate 2.5 mL/min because of re-dilatation of the vessels.

### Ethics

The present study was approved by the Siriraj Institutional Review Board (SIRB), Faculty of Medicine Siriraj Hospital, Mahidol University (Si618/2010).

### Results

Twenty patients were enrolled. Thirteen patients were female (65%). The demographic characteristics of these patients were presented in Table 1. There was no correlation between demographic characteristics and the incidence of vasospasm ( $p$ -value  $>0.05$ ).

The mean age of patients was  $55.4 \pm 11.3$  years. Considering the Glasgow coma score (GCS) on admission, 15 patients (75%) were conscious (GCS 13-15) as shown in Table 2. The patient's level of consciousness (scored by both the GCS and the WFNS score) was found to be in agreement between the scores.

Eight of 20 patients (40%) had no co-morbidity while the other 10 patients (50%) had hypertension, and the remaining two patients (10%) had transient

ischemic attack (TIA) and psoriasis, respectively. Fourteen patients (70%) presented with headache.

Symptoms of cerebral vasospasm developed after post-rupture day 3. Most patients had symptoms during the first week (18/20 patients; 90%) while the other two patients (10%) experienced symptoms after the first week. The symptoms of cerebral vasospasm occurred mostly on post-rupture day 4 and day 7 (Table 3).

Physical examination was performed and confirmed neurological abnormalities before starting the treatment of cerebral vasospasm in a half of the patients. The most common symptom was hemiparesis (8/10 patients; 80%) (Table 4).

To compare the results from the CTA and the DSA, the location of intracranial arteries were analyzed in 15 arterial segments (right and left A1, A2, M1, M2, P1, V4, and supraclinoid ICA, and BA) (300 locations coming from 15 arterial segments multiply by 20 patients). Eighty-seven out of 300 locations were found vasospasm on the CTA, meanwhile the DSA detected vasospasm on 99 locations. When considering the DSA as a gold standard method for detecting vasospasm, corresponding locations of vasospasm in the CTA and the DSA were found on 53 locations. The left A1 and A2 segments of the ACA, and left M1 segment of MCA were the vessels found to be significant in agreement between both methods (Table 5). Both CTA and DSA showed mild degree of vasospasm ( $<50\%$  luminal narrowing) in 48 out of 53 locations (90.6%), whereas severe vasospasm ( $>50\%$  luminal narrowing) was found only in five out of 53 locations (9.4%). The location of vasospasm was often found on the arterial portion proximal to the circle of Willis.

The diagnosis of cerebral vasospasm by the CTA was statistically correlated to the result of the DSA (Kappa 0.793,  $p$ -value 0.001). Among patients (19/20 patients: 95%) with cerebral vasospasm, the results showed good correlation between the CTA and the DSA. This represents a diagnostic accuracy of 90%. Only one patient (1/20 patients: 5%) was diagnosed a normal vascular caliber by the CTA, while the DSA could clearly demonstrate vasospasm (false negative analysis 5%). Positive predictive value (PPV) of the CTA was 100%, whereas negative predictive value (NPV) of the CTA was 66%. Sensitivity of the CTA was 94% in the detection of vasospasm while specificity of the CTA was 100%.

Sixteen patients were treated with craniotomy and clipping aneurysms. Four patients were treated

**Table 1.** Relationship between patient characteristics and cerebral vasospasm

Patient characteristics	Mean/%	Kappa correlation with vasospasm	p-value of the correlation with vasospasm
Age (years)	55.40	0.330	0.528
Weight (kg)	62.35	0.256	0.286
Gender (male:female)	1:1.85	-0.245	0.435
Underlying disease, n (%)		0.111	0.675
HT	10 (50)		
Other	2 (10)		
None	8 (40)		
Present of headache, n (%)		0.145	0.635
Yes	14 (70)		
No	6 (30)		
GCS on admission date, n (%)		-0.063	0.224
GCS 15	8 (40)		
GCS 13-14	7 (35)		
GCS 7-12	5 (25)		
WFNS on admission date, n (%)		-0.089	0.320
Grade 1	7 (35)		
Grade 2	3 (15)		
Grade 3	4 (20)		
Grade 4	5 (25)		
Grade 5	1 (5)		
Platelet count	291,400	0.045	0.906
Creatinine	0.708	0.259	0.568
PT	12.84	-0.259	0.594
PTT	25.42	0.048	0.769

HT = hypertension; GCS = Glasgow coma score; WFNS = World Federation of Neurosurgical Societies; PT = prothrombin time; PTT = partial thromboplastin time

**Table 2.** Glasgow coma score (GCS) on admission

GCS	Number of patients	Percent (%)
<8	2	10
9-12	3	15
13-14	8	40
15	7	35
Total	20	100

with endovascular intervention. Fifteen patients (75%) developed complications during admission. The common complications were infections (13/15 patients: 86.7%), especially pneumonia (7/13 patients: 53.8%), and CNS infection (4/13 patients: 30.8%) (Table 6). However, the incidence of vasospasm was not associated with the incidence of post-operative complications (*p*-value 0.416).

### Discussion

Mortality rate of patients with SAH that is caused by ruptured intracranial aneurysms is high up to 40 to 50%<sup>(3,4)</sup>. Even though proper treatment was

**Table 3.** Post-rupture day and number of the patients

Date of decrease in GCS (post-rupture)	Number of patients	Percent (%)
Day 3	1	5
Day 4	6	30
Day 5	2	10
Day 6	3	15
Day 7	6	30
Day 8	0	0
Day 9	1	5
Day 10	1	5
Total	20	100

**Table 4.** Neurological deficits in patients with cerebral vasospasm

Specific neurological deficit	Number of patients	Percent (%)
Absence	10	50
Presence		
Hemiparesis	8	40
Paraparesis	1	5
Cranial neuropathy	1	5
Total	20	100

**Table 5.** Correlation of the detected vasospasm between the CTA and the DSA

Spastic cerebral arteries from both CTA and DSA	Number of segments (vasospasm)	Weight Kappa correlation	p-value
Right A1	8	0.204	0.388
Left A1	6	0.684	0.001
Right A2	3	0.158	0.506
Left A2	5	0.663	0.001
Right M1	6	0.385	0.094
Left M1	8	0.503	0.024
Right M2	1	-0.105	0.660
Left M2	2	0.157	0.508
Right P1	0	0.225	0.341
Left P1	2	0.145	0.541
Right ICA	3	-0.078	0.744
Left ICA	4	-0.094	0.694
Right VA	0	0.397	0.083
Left VA	2	-0.020	0.932
BA	3	-0.089	0.709
Total	53		

CTA = computerized tomographic angiography; DSA = digital subtraction angiography; ICA = internal carotid artery; VA = vertebral artery; BA = basilar artery

**Table 6.** Complications after treatment of intracranial aneurysms and cerebral vasospasm

Post-operative complications	Number of patients	Percent (%)
Absence	5	25
Presence		
Infection	13	65 (100)
Pneumonia	7/13	35 (53.8)
CNS infection	4/13	20 (30.8)
UTI	2/13	10 (15.4)
Other	2	10
Total	20	100

performed, half of the survivors will suffer from disabilities and burden to care givers<sup>(3,4)</sup>. The most common causes of poor outcome are intracranial aneurysmal rebleeding and/or cerebral vasospasm<sup>(5)</sup>. The incidence of angiographic vasospasm was found in more than half of the patients<sup>(4-6)</sup>. Half of these patients have impaired neurological status from sequelae of brain ischemia<sup>(3,4)</sup>. DSA has high diagnostic accuracy and is considered as the gold standard for vasospasm detection. Limited equipment and expertise, a prolonged procedure, and patients are at risk of thromboembolic complications from arterial catheterization are disadvantages of the DSA. Therefore, alternative investigations are needed to

compete or even replace the DSA in the diagnosis of cerebral vasospasm.

The present study used CTA for diagnosis of vasospasm after rupture of intracranial aneurysms. The results showed that CTA could detect cerebral vasospasm with a relatively high diagnostic accuracy (90%) relevant to the other studies<sup>(6,12)</sup> in which the diagnostic accuracy was 90 to 100%. These results were also consistent with the results obtained from the DSA (correlation 0.793)<sup>(13)</sup>.

The demographic characteristics of patients were analyzed to find the correlation with the incidence of vasospasm; these included age, gender, weight, date of onset of SAH, GCS and WFNS on admission date, headache at presentation, co-morbidities, and results of blood test. None of these factors was correlated to the incidence of cerebral vasospasm. This was in contrast to the study of Charpentier et al (1999)<sup>(14)</sup> in which their results showed patients older than 50 years, high grade WFNS on admission date, and hyperglycemic state, were associated with an increased risk of cerebral vasospasm.

The PPV of the CTA was 100%, and the NPV of the CTA was 66%. Those differed from results of the study of Wintermark et al (2006)<sup>(15)</sup> in which the PPV and NPV of the CTA were 60.4% and 95.1%, respectively. Sensitivity of the CTA was 94% and

specificity of the CTA was 100% for detecting vasospasm. These results were similar to the other studies<sup>(16,17)</sup> in which the sensitivity of the CTA was 79.6 to 86.8% and the specificity of the CTA was 93.1 to 96.8%.

The cerebral vasospasm detected by both CTA and DSA was found obviously on proximal arterial portions (A1 and M1 segments, ICA, VA, BA) more than on distal portions (A2 and M2 segments). This finding was similar to the study of Anderson et al (2000)<sup>(13)</sup>. The vessels that showed the most correlation between two methods was left A1, A2 segments of anterior cerebral arteries and left M1 segment of middle cerebral arteries.

The severity of vasospasm could be analyzed from the CTA (less or more than 50% luminal narrowing). Mild vasospasm (<50% luminal narrowing) was found up to 90%, while severe vasospasm was found on only 10%. The results differed from the other studies<sup>(13,18)</sup> in which reported that severe vasospasm was more commonly detected than mild vasospasm. The differences may be in part due to different population, techniques of the CTA reconstruction, difference in experience and techniques of the interpreters used to identify and define the affected arterial segments, and patient's own factors, such as brain swelling or intraparenchymal hemorrhage. These factors could affect the results of the CTA.

The present study had limitations. There is not a large enough sample size to get a significant result. An aneurysm clip artifact can obscure significant vasospasm findings on the CTA images.

## Conclusion

Compared to the digital subtraction angiography, computerized tomographic angiography can be used for detecting cerebral vasospasm in patients with ruptured intracranial aneurysms with high sensitivity, specificity, and diagnostic accuracy.

## What is already known on this topic?

Several international studies showed that CTA rendered the sensitivity and specificity higher than those of TCD; however, those of the CTA were lower than those of the DSA in detection of cerebral vasospasm. The diagnostic accuracy of the CTA in these studies was high in detecting cerebral vasospasm and the result of the CTA were well correlated with that of the DSA, particularly the proximal portion of the cerebral artery.

Therefore, the authors need to know the tendency of value of the diagnostic accuracy rendered

by the CTA and the correlation of results between the CTA and the DSA in detection of cerebral vasospasm in Thai. Owing to lack of expertise and equipment of the DSA in Thailand, we often use the CTA to substitute the DSA in detecting cerebral vasospasm for planning of management in patients with ruptured intracranial aneurysms.

## What this study adds?

The present study is the first report in Thailand in terms of comparison of the diagnostic accuracy and correlation between the CTA and the DSA in detection of cerebral vasospasm performed and interpreted by Thai neuroradiologists and neuro-interventionists. Our results revealed that the CTA yielded a relatively high diagnostic accuracy and its result was well correlated to that of the DSA, in agreement with the previous studies. We found that detection of cerebral vasospasm in the proximal arterial portion was well correlated between the CTA and the DSA. In the same manner, this correlation was similar to the results of previous studies.

In conclusion, the CTA is valuable and may substitute the DSA in detection of cerebral vasospasm.

## Acknowledgements

The authors would like to acknowledge the neuro-interventionists' team and neuroradiologists' team at Siriraj Hospital in the cooperation for performing the CTA and DSA in the present study.

## Potential conflicts of interest

None.

## References

1. de Rooij NK, Linn FH, van der Plas JA, Algra A, Rinkel GJ. Incidence of subarachnoid haemorrhage: a systematic review with emphasis on region, age, gender and time trends. *J Neurol Neurosurg Psychiatry* 2007; 78: 1365-72.
2. Linn FH, Rinkel GJ, Algra A, van Gijn J. Incidence of subarachnoid hemorrhage: role of region, year, and rate of computed tomography: a meta-analysis. *Stroke* 1996; 27: 625-9.
3. Dorsch N. A clinical review of cerebral vasospasm and delayed ischaemia following aneurysm rupture. *Acta Neurochir Suppl* 2011; 110: 5-6.
4. Dorsch NW, King MT. A review of cerebral vasospasm in aneurysmal subarachnoid haemorrhage Part I: Incidence and effects. *J Clin Neurosci* 1994; 1: 19-26.

5. Morgan M, Halcrow S, Sorby W, Grinnell V. Outcome of aneurysmal subarachnoid haemorrhage following the introduction of papaverine angioplasty. *J Clin Neurosci* 1996; 3: 139-42.
6. Khan N, Ashraf N, Hameed A, Muhammed A. Diagnostic accuracy of CT angiography and surgical outcome of cerebral aneurysms. *Pak J Neurological Sci* 2009; 4: 8-11.
7. Velat GJ, Kimball MM, Mocco JD, Hoh BL. Vasospasm after aneurysmal subarachnoid hemorrhage: review of randomized controlled trials and meta-analyses in the literature. *World Neurosurg* 2011; 76: 446-54.
8. Kimball MM, Velat GJ, Hoh BL. Critical care guidelines on the endovascular management of cerebral vasospasm. *Neurocrit Care* 2011; 15: 336-41.
9. Lennihan L, Petty GW, Fink ME, Solomon RA, Mohr JP. Transcranial Doppler detection of anterior cerebral artery vasospasm. *J Neurol Neurosurg Psychiatry* 1993; 56: 906-9.
10. Suwanwela NC, Phanthumchinda K, Suwanwela N. Transcranial doppler sonography and CT angiography in patients with atherothrombotic middle cerebral artery stroke. *AJNR Am J Neuroradiol* 2002; 23: 1352-5.
11. Shankar JJ, Tan IY, Krings T, Terbrugge K, Agid R. CT angiography for evaluation of cerebral vasospasm following acute subarachnoid haemorrhage. *Neuroradiology* 2012; 54: 197-203.
12. Otawara Y, Ogasawara K, Ogawa A, Sasaki M, Takahashi K. Evaluation of vasospasm after subarachnoid hemorrhage by use of multislice computed tomographic angiography. *Neurosurgery* 2002; 51: 939-42.
13. Anderson GB, Ashforth R, Steinke DE, Findlay JM. CT angiography for the detection of cerebral vasospasm in patients with acute subarachnoid hemorrhage. *AJNR Am J Neuroradiol* 2000; 21: 1011-5.
14. Charpentier C, Audibert G, Guillemin F, Civit T, Ducrocq X, Bracard S, et al. Multivariate analysis of predictors of cerebral vasospasm occurrence after aneurysmal subarachnoid hemorrhage. *Stroke* 1999; 30: 1402-8.
15. Wintermark M, Ko NU, Smith WS, Liu S, Higashida RT, Dillon WP. Vasospasm after subarachnoid hemorrhage: utility of perfusion CT and CT angiography on diagnosis and management. *AJNR Am J Neuroradiol* 2006; 27: 26-34.
16. Binaghi S, Colleoni ML, Maeder P, Uske A, Regli L, Dehdashti AR, et al. CT angiography and perfusion CT in cerebral vasospasm after subarachnoid hemorrhage. *AJNR Am J Neuroradiol* 2007; 28: 750-8.
17. Greenberg ED, Gold R, Reichman M, John M, Ivanidze J, Edwards AM, et al. Diagnostic accuracy of CT angiography and CT perfusion for cerebral vasospasm: a meta-analysis. *AJNR Am J Neuroradiol* 2010; 31: 1853-60.
18. Joo SP, Kim TS, Kim YS, Moon KS, Lee JK, Kim JH, et al. Clinical utility of multislice computed tomographic angiography for detection of cerebral vasospasm in acute subarachnoid hemorrhage. *Minim Invasive Neurosurg* 2006; 49: 286-90.

---

การใช้เอกซเรย์คอมพิวเตอร์สำหรับศึกษาหลอดเลือดสมองในการตรวจหาภาวะหลอดเลือดสมองตีบซึ่งเกิด  
ภายหลังหลอดเลือดโป่งพองในสมองแตก

จิรพันธ์ นามหย่อง, ทวีศักดิ์ เลื้อยบุญญาวัฒน์, เอกวุฒิ จันแก้ว, ประจักษ์ ศรีรพีพัฒน์, วริสา วงศ์ภาณุวิชญ์, อรสา ขวาลภาฤทธิ์,  
สิริอร ตรีตระการ, ชิตพงษ์ ส่งแสง, จุฬาลักษณ์ บุญมา

**วัตถุประสงค์:** การฉีดสารทึบรังสีเข้าหลอดเลือดสมองผ่านทางวิธีการใส่สายสวนหลอดเลือด (digital subtraction angiography, DSA) เป็นวิธีการตรวจมาตรฐานสำหรับการวินิจฉัยภาวะหลอดเลือดสมองตีบ แต่การตรวจวิธีนี้ไม่ได้มีพร้อมทั้งด้านบุคลากรและเครื่องมือการตรวจในทุกโรงพยาบาล การศึกษานี้จึงมีวัตถุประสงค์เพื่อเปรียบเทียบค่าความถูกต้องในการวินิจฉัย (diagnostic accuracy) ของเอกซเรย์คอมพิวเตอร์สำหรับการศึกษาหลอดเลือดสมอง (computerized tomographic angiography, CTA) เพื่อตรวจหาภาวะหลอดเลือดสมองตีบซึ่งเกิดภายหลังหลอดเลือดโป่งพองในสมองแตก โดยเทียบกับวิธีการตรวจมาตรฐาน

**วัสดุและวิธีการ:** จัดเก็บข้อมูลตั้งแต่เดือนมกราคม พ.ศ. 2554 จนถึง ตุลาคม พ.ศ. 2557 มีผู้ป่วยที่สงสัยภาวะหลอดเลือดสมองตีบซึ่งเกิดภายหลังหลอดเลือดโป่งพองในสมองแตกเข้าร่วมการศึกษานี้ทั้งสิ้น 20 ราย โดยผู้ป่วยทั้งหมดได้รับการตรวจทั้งเอกซเรย์คอมพิวเตอร์หลอดเลือดสมอง (CTA) และการฉีดสารทึบรังสีเข้าหลอดเลือดสมองผ่านทางวิธีการใส่สายสวนหลอดเลือด (DSA) ภายใน 24 ชั่วโมง หลังตรวจพบอาการที่เข้าได้กับภาวะหลอดเลือดสมองตีบ ซึ่งแต่ละวิธีการตรวจแปลผลอ่านโดยรังสีแพทย์วินิจฉัย 2 คน อย่างเป็นอิสระต่อกัน

**ผลการศึกษา:** ผู้ป่วยที่เข้าร่วมการศึกษานี้ทั้งสิ้น 20 ราย เป็นเพศชาย 7 ราย เพศหญิง 13 ราย ลักษณะทั่วไปของผู้ป่วยไม่มีความสัมพันธ์ทางสถิติกับอุบัติการณ์การเกิดภาวะหลอดเลือดสมองตีบ ผลการตรวจหาภาวะหลอดเลือดสมองตีบใน CTA สอดคล้องกับ DSA (Kappa 0.793) ค่าความถูกต้องในการวินิจฉัย (diagnostic accuracy) คำนวณได้ร้อยละ 90 ซึ่ง CTA มีค่าความไว (sensitivity) ร้อยละ 94 และค่าความจำเพาะ (specificity) ร้อยละ 100 ค่าผลลบตวง (false negative) เท่ากับร้อยละ 5 ค่าพยากรณ์ผลบวก (positive predictive value) เท่ากับร้อยละ 100 และค่าพยากรณ์ผลลบ (negative predictive value) เท่ากับร้อยละ 66 โดยหลอดเลือดสมองที่ตรวจพบความสอดคล้องกันมากที่สุด คือ left A1 (Kappa 0.684) และ left A2 (Kappa 0.663) segments ของ anterior cerebral artery และ left M1 (Kappa 0.503) segment ของ middle cerebral artery ซึ่งทั้ง CTA และ DSA สามารถตรวจพบภาวะหลอดเลือดสมองตีบกลุ่มไม่รุนแรง (mild vasospasm <50% luminal stenosis) มากกว่ากลุ่มรุนแรง (severe vasospasm >50% luminal stenosis) และตรวจพบภาวะหลอดเลือดสมองตีบส่วนต้น (proximal portions) มากกว่าส่วนปลาย (distal portions)

**สรุป:** สามารถใช้เอกซเรย์คอมพิวเตอร์สำหรับการศึกษาหลอดเลือดสมอง ในการตรวจสอบภาวะหลอดเลือดสมองตีบ ซึ่งเกิดภายหลังหลอดเลือดโป่งพองในสมองแตก ซึ่งมีความไว ความจำเพาะ และค่าความถูกต้องในการวินิจฉัยสูง สัมพันธ์กับการตรวจด้วยการฉีดสารทึบรังสีเข้าหลอดเลือดสมองผ่านทางวิธีการใส่สายสวนหลอดเลือด

---