

The Short Stem THA Provides Promising Results in Patients with Osteonecrosis of the Femoral Head

Yingyong Suksathien MD*,
Jithayut Sueajui MD*

* Department of Orthopedic Surgery, Maharat Hospital, Nakhon Ratchasima, Thailand

Background: The short stem prosthesis showed good results in patients with primary osteoarthritis. However, there were a few studies about the short stem total hip arthroplasty (THA) in patients with osteonecrosis of the femoral head (ONFH).

Objective: To evaluate the clinical and radiographic results of the short stem THA in patients with ONFH. The authors hypothesized that the short stem THA would be a promising procedure for patients with ONFH.

Material and Method: The authors reviewed 120 osteonecrotic hips in 93 patients who underwent THA with Metha® short stem between November 2010 and February 2013. The appearance of bone trabeculae development and radiolucent line was reviewed using Gruen's classification. The Harris hip score (HHS) was recorded at 6, 12, 24, and 36 months postoperative for evaluating the clinical results.

Results: The mean age of patients was 44.4 years (18-68) with the mean BMI of 22.7 (15.1-32.5, SD 3.5). The average follow-up period was 29.2 months (20-47). The mean HHS was significantly improved from 43.9 (22.7-74, SD 7.7) preoperatively to 97.7 (85.9-100, SD 2.7) at 6-month postoperatively ($p < 0.01$). The radiographic change around the stems showed bone trabeculae development at zone 1 (77 cases, 64.2%), 2 (27 cases, 22.5%), 3 (106 cases, 88.3%), 6 (120 cases, 100%), and 7 (115 cases, 95.8%). There was one case (0.8%) of 5 mm subsidence and the radiolucent line was observed in zone 1. There were six cases (5%) of intraoperative femoral fractures and were treated with cerclage wires with no further subsidence observed. There was one case (0.8%) of distal stem perforation that had stable bone ingrowth. No revision was required.

Conclusion: The clinical and radiographic results of the short stem THA in patients with ONFH are generally satisfactory. Its design enables preservation of the bone stock and the bone trabeculae appear to confirm the assumption of proximal force transmission. The authors believe that the short stem THA is a promising procedure for patients with ONFH.

Keywords: Osteonecrosis of the femoral head (ONFH), Total hip arthroplasty (THA), Short stem arthroplasty, Methaphyseal anchorage

J Med Assoc Thai 2015; 98 (8): 768-74

Full text. e-Journal: <http://www.jmatonline.com>

Osteonecrosis of the femoral head (ONFH) is a devastating disease with numerous risk factors and poorly understood pathogenesis and most commonly affects the hip joints of young patients. If left untreated, the majority of patients will become symptomatic and progress to a collapse of the femoral head and rapidly develop end-stage degenerative hip disease.

At present, the treatment of end-stage ONFH remains a challenging problem in orthopedics practice. Common treatments include hemiarthroplasty, total hip resurfacing, conventional total hip arthroplasty (THA), and short stem THA. Conventional THA showed satisfactory results in ONFH from many

previous studies⁽¹⁻⁶⁾. Due to the young age of patients with ONFH, the THA would ideally also preserve bone mass in order to allow future options as a revision might become necessary when the patients get older.

The short stem prosthesis showed good results in patients with primary osteoarthritis from many previous studies⁽⁷⁻¹⁰⁾. Its design enables preservation of the bone stock and the bone trabeculae appear to confirm the assumption of proximal force transmission. There were few studies about the short stem THA in patients with ONFH. Three characteristics of ONFH which are not like primary osteoarthritis, occur in relatively young and active patients and mostly involve bilateral hips, and bony ingrowth of cementless prosthesis tends to be compromised by poor bone quality.

The purpose of the present study was to evaluate the clinical and radiographic outcomes of the short stem THA in patients with ONFH. The authors

Correspondence to:

Suksathien Y, Department of Orthopedic Surgery, Maharat Nakhon Ratchasima Hospital, Chang Phueak Road, Mueang District, Nakhon Ratchasima 30000, Thailand.

Phone: +66-44-235529, Fax: +66-44-259677

E-mail: ysuksathien@yahoo.com

hypothesized that the short stem THA would be a promising procedure for patients with ONFH.

Material and Method

The present study was approved by the Ethics Committee of Maharat Nakhon Ratchasima Hospital. The present study included all advanced osteonecrosis patients who underwent THA with the short stem in our department between November 2010 and February 2013. The inclusion criteria were patients with aged over 15 with advanced osteonecrosis (stage III or IV of Ficat and Arlet staging system⁽¹¹⁾) and good bone quality (Dorr type A or type B⁽¹²⁾). The exclusion criteria were patients with aged below 15, poor bone quality or anatomical variants that complicate implantation of the short stem THA.

All cases in the present study were performed with Metha[®] short stem (B. Braun Aesculap AG, Tuttlingen, Germany) (Fig. 1) THA by a single surgeon (Suksathien Y). The Metha[®] short stem is a cementless, collarless, and tapered short stem prosthesis. For osseointegration, the Metha[®] short stem is round coated with Plasmapore, Calcium-phosphate layer. This layer is supposed to have an osteoconductive effect and accelerates contact between the bone and the prosthesis.

Before January 2012, all cases were performed in lateral decubitus position with manual technique. After January 2012, all cases were performed with navigation in semilateral decubitus position using OrthoPilot THA plus 3.2 (cup only) software (Aesculap AG). The cementless acetabular cup (Plasmacup SC; B. Braun Aesculap AG, Tuttlingen, Germany) was used in all hips. Any intraoperative femoral fractures were treated with cerclage wires.

Patients without intraoperative femoral fractures were allowed to walk using crutches full weight-bearing on the third postoperative day. Patients with intraoperative femoral fractures were allowed to walk under partial weight-bearing using crutches within six weeks, and then full weight-bearing.

Patients were routinely contacted every three months in the first postoperative year and then, every six months thereafter. An anteroposterior of both hips with both legs in 15 degrees internal rotation and lateral radiographs were taken. The appearance of bone trabeculae development and radiolucent line were reviewed in all hips using Gruen's classification⁽¹³⁾ (Fig. 2). Two authors (Suksathien Y and Sueajui J) reviewed all radiographs with interpretation reported by consensus. Stem subsidence more than 2 mm was defined as positive subsidence by comparison with

the radiographs taken after surgery. The Harris Hip Score (HHS) was recorded at 6, 12, 24, and 36 months postoperative for evaluating the clinical results.

Statistical analysis

Wilcoxon's signed-rank test was used to compare the preoperative and postoperative HHS.

Results

One hundred thirty one cases of Metha[®] short stem THA were performed in our department in this period. Two cases deceased from conditions unrelated to the arthroplasty and nine cases were lost before the minimum one-year follow-up, leaving 120 cases to study. There were 66 patients with unilateral and 27 patients with bilateral procedures. Eighty-eight cases were men and 32 cases were women. The mean age of patient was 44.4 years (18-68), with the mean body

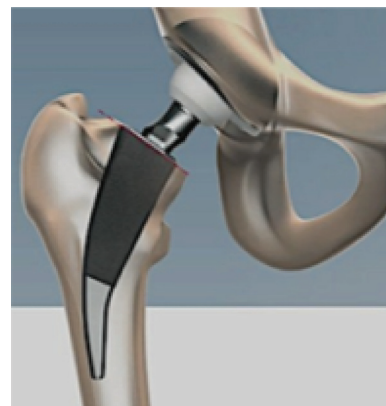

Fig. 1 Photograph of Metha[®] short stem prosthesis (B. Braun, Aesculap, Tuttlingen, Germany).

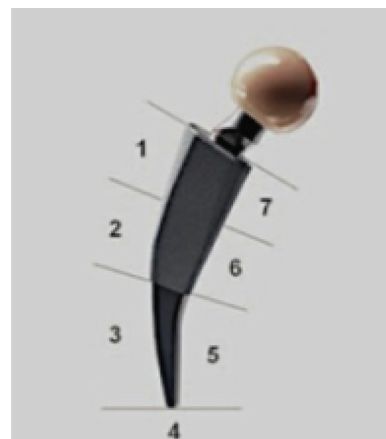


Fig. 2 Photograph of Metha[®] short stem prosthesis and definition of Gruen's periprosthetic zones.

mass index (BMI) of 22.7 (15.1-32.5, SD 3.5). The average follow-up period was 29.2 months (20-47). The etiologies of osteonecrosis that were identified included alcoholic induced (74 hips, 61.7%), corticosteroid induced (27 hips, 22.5%), posttraumatic (8 hips, 6.6%), and systemic lupus erythematosus (SLE) (5 hips, 4.2%). No underlying condition was identified in six hips (5%). Stem size 0 were used in 68 cases (56.7%), size 1 in 35 cases (29.1%), size 2 in 13 cases (10.8%), size 3 in two cases (1.7%), and size 4 in two cases (1.7%) (Table 1).

Postoperatively, full follow-up data were available for 120 cases at 6- and 12-month, 85 cases at 24-month and 27 cases at 36-month. The mean HHS was significantly improved from 43.9 (22.7-74, SD 7.7) preoperatively to 97.7 (85.9-100, SD 2.7) at 6-month ($p<0.01$), 99.5 (90-100, SD 1.5) at 12-month

($p<0.01$), 99.4 (93-100, SD 1.7) at 24-month and 99.9 (99.9-100, SD 0.05) at 36-month postoperatively ($p<0.01$). There were six cases (5%) of intraoperative femoral fractures and these were treated with cerclage wires, no further subsidence was observed. There was one case (0.8%) of distal stem perforation that had stable bone ingrowth. There was no revision and no dislocation in the present study.

The radiographic change around the stems based on Gruen's classification⁽¹³⁾ showed bone trabeculae development at zone 1 (77 cases, 64%), 2 (27 cases, 22.5%), 3 (106 cases, 88.3%), 6 (120 cases, 100%), and 7 (115 cases, 95.8%) (Fig. 3). There was one case (0.8%) of 5 mm subsidence and the radiolucent line was observed in zone 1. Secondary osteointegration was developed in the other zone and no further subsidence was observed in this case (Fig. 4 and Table 2).

Table 1. Details of patients with Metha[®] short stem prosthesis

| Parameters | Values |
|---|-----------------------|
| No. of hips | 120 |
| Gender (male/female) | 88/32 |
| Mean age (years) (range) | 44.4 (18-68) |
| Mean BMI (range, SD) | 22.7 (15.1-32.5, 3.5) |
| Average follow-up (months) (range) | 24.9 (16-43) |
| Etiology of ONFH (cases) (%) | |
| Alcoholic induced | 74 (61.7) |
| Corticosteroid induced | 27 (22.5) |
| Posttraumatic | 8 (6.6) |
| SLE | 5 (4.2) |
| No underlying condition | 6 (5.0) |
| Stem size (cases) (%) | |
| 0 | 68 (56.7) |
| 1 | 35 (29.1) |
| 2 | 13 (10.8) |
| 3 | 2 (1.7) |
| 4 | 2 (1.7) |
| Mean Harris Hip Score (points) (range, SD) | |
| Preoperative | 43.9 (22.7-74, 7.7) |
| Postoperative 6 months | 97.7 (85.9-100, 2.7) |
| Postoperative 12 months | 99.5 (90-100, 1.5) |
| Postoperative 24 months | 99.4 (93-100, 1.7) |
| Postoperative 36 months | 99.9 (99.9-100, 0.05) |
| Complications | |
| Intraoperative femoral fracture (cases) (%) | 6 (5.0) |
| Distal stem perforation (case) (%) | 1 (0.8) |
| Subsidence (case) (%) (mm) | 1 (0.8) (5) |

BMI = body mass index; ONFH = osteonecrosis of the femoral head; SLE = systemic lupus erythematosus

Discussion

There is uncertainty in the literature about the arthroplasty method that provides the best outcome

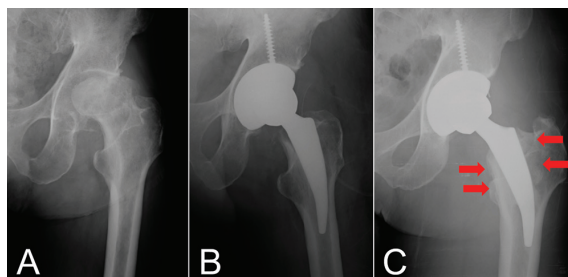


Fig. 3 Anteroposterior radiograph of Metha[®] short stem prosthesis showed bone trabeculae development at 24 months postoperatively (C) compared to initial postoperative (B) and preoperative (A).

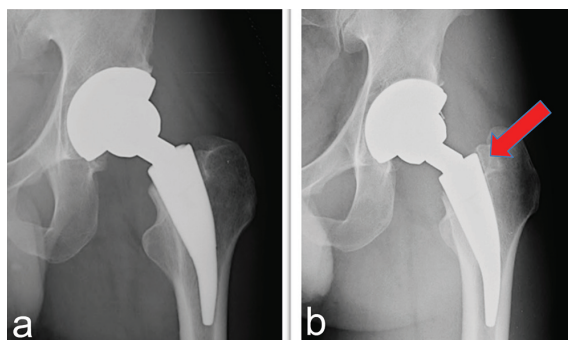


Fig. 4 Anteroposterior radiographs of subsiding Metha[®] short stem prosthesis at 12 months postoperatively (b) with radiolucent line at zone 1 compared to initial postoperative (a).

Table 2. Radiographic change around the stems

| Zone (Gruen's classification) | Development of bone trabeculae | Radiolucent line |
|----------------------------------|-----------------------------------|---------------------|
| | No. (%) | No. (%) |
| 1 | 77 (64.2) | 1 (0.8) |
| 2 | 27 (22.5) | - |
| 3 | 106 (88.3) | - |
| 4 | - | - |
| 5 | - | - |
| 6 | 120 (100) | - |
| 7 | 115 (95.8) | - |

for patients with progressive ONFH. Many surgeons are concerned about the poor quality of the femoral bone in ONFH and possibly persistent defects in bone mineral metabolism, which may be resulting in poor osseointegration and possibly in loosening of the stems. Tingart et al⁽¹⁴⁾ analyzed the bone matrix composition and trabecular microarchitecture of the femoral metaphysis in patients with ONFH. They concluded that these alterations in bone metabolism and architecture might contribute to the higher rates of stem loosening after total hip replacement in patients with ONFH. Calder et al⁽¹⁵⁾ showed that osteonecrotic hips have a decrease in osteogenic stem cells in the femoral head beneath the sequestrum and in the intertrochanteric region. This was confirmed by the extent of osteocyte death in the proximal femur observed in patients having THA for ONFH.

Despite these concerns, conventional THA showed satisfactory results in ONFH from many previous studies. Kim et al⁽¹⁾ reported the outcome of cementless THA with a modular femoral component in patients younger than fifty years with ONFH. They demonstrated that the survivorship with and end point of stem revision for any reason was 93.8% and for aseptic loosening was 100% at 16.8-year. Han et al⁽²⁾ studied in 95 hips with cementless wedge-shaped tapered CLS stem. With revision for stem loosening as the end point, the survivorship showed 98.9% (95% CI, range 96.9%-100%) at 13-year. Bedard et al⁽³⁾ showed the results of cementless THA for ONFH, the survivorship with reoperation for any reasons was 93±11.7% and for aseptic loosening was 100% at 10-year follow-up. They concluded that loosening and revision for loosening were significantly lower in the cementless group compared to the cemented historical control. Kim et al⁽⁴⁾ reported results at a mean of 17.3-year follow-up of 148 primary total hip arthroplasties in 98 patients with ONFH. They showed

that the survival rate for both cemented and cementless femoral stems was equally at 98%. Johansson et al⁽⁵⁾ reviewed sixty-seven reports in the literature, representing 3,277 hips (2,593 patients) with total hip arthroplasty for ONFH. They concluded that osteonecrosis patients who had total hip arthroplasty after 1990s had clinical outcomes and implant survivorships similar to those for all hips in publicly reported national Joint Registries. This systematic literature review provides evidence that osteonecrosis itself is not associated with poor outcomes in total hip arthroplasty. Johnson et al⁽⁶⁾ studied about the treatment of ONFH in United States found that in 1992, 75% (n = 2,678) of the procedures were THA, which increased to 88% (n = 5,632) in 2008. They concluded that the survivorship of THA in ONFH improved since 1993.

There were a few studies about the short stem THA in osteonecrosis patients. Wang et al⁽¹⁶⁾ reported the results of CFP[®] short stem prosthesis in nine hips of advance stage ONFH. The mean HHS improved from preoperatively 42.8 to postoperatively 92.8 after 18.1 months follow-up. Neither loosening nor osteolysis was found. Zeh et al⁽¹⁷⁾ analyzed the midterm results of 26 Mayo[®] short stem THAs in 21 patients with ONFH; longitudinal stem migration and varus-valgus femoral stem alignment were examined. The authors demonstrated that there was no increased migration or tilt for Mayo[®] short stem THA. Based on their results they concluded that the Mayo[®] conservative hip as an alternative for operative treatment of patients with ONFH. Floerkemeier et al⁽¹⁸⁾ evaluated the clinical and radiological short to midterm results of Metha[®] short stem in 73 hips (64 patients) with progressive ONFH. The pain scale improved from preoperatively 7.8 to postoperatively 1.7 and HHS improved from 41.4 to 90.6 points, at 34-month post-surgery. The radiological assessment showed good bone ingrowth in all patients. In conclusion, they confirmed encouraging results as well as good bone ingrowth of Metha[®] short stem even in patients with ONFH.

Consistent with the present study, the authors found that the HHS were significantly improved postoperatively at 6-, 12-, 24-, and 36-month ($p < 0.01$) from preoperatively. There were six cases (5%) of intraoperative femoral fractures that were treated with cerclage wires; no further subsidence was observed. There was one case (0.8%) of distal stem perforation that had stable bone ingrowth and no revision was required. The authors believed that it was because of

a technical error. There was one case (0.8%) of 5 mm subsidence and the secondary osteointegration was developed; no further subsidence was observed. The authors believed that it was due to the undersized stem.

In the present study, similar to previous studies^(7,8) from Asian populations, the authors found more incidences of fractures with short stem prosthesis when compared to other studies^(9,10,19) from Caucasian populations. Kamada et al⁽⁷⁾ reported 11.3% of femoral fractures in 106 hips of Mayo[®] stem but all cases were stable after wiring. Three other cases (2.8%) showed subsidence from femoral stem malalignment. In our previous study⁽⁸⁾, the authors found 6% of intraoperative femoral fractures and only 2% of subsidence in 50 hips. The authors believed that it was because of the relatively narrow neck diameter of Thai patients. This is reflected in the most common size of the femoral stem in the present study, which was the smallest size (size 0) (56.67%). Furthermore, in all cases of intraoperative femoral fractures (5%), the used stems were size 0. Compared to other studies from Caucasian populations with fewer incidences of fractures, Simank et al⁽⁹⁾ reported two cases (1.67%) of intraoperative femoral fractures in 120 hips of Metha[®] stem. Wittenberg et al⁽¹⁰⁾ reported three cases (1.47%) of intraoperative femoral fractures in 204 cases of Metha[®] short stem. Morrey et al⁽¹⁹⁾ demonstrated 6.2% of intraoperative femoral fractures and 7% of subsidence with Mayo[®] stem.

Lerch et al⁽²⁰⁾ studied bone remodeling around the Metha[®] stem and reported that increase of bone mineral density (BMD) was shown in zone 6 and 7, both of which on the medial side. Consistent with the present study, the authors could observe bone trabeculae development mainly on the medial side of Metha[®] stem in both zones 6 (100%) and 7 (95.8%); it revealed a concentrated load distribution on the calcar area which is an important region to guarantee long-term implant survival.

There were some limitations of the present study. The present study was not based on dual-energy radiograph absorptiometry, so we were unable to objectively evaluate the changes in bone density. Additionally, the present study is focusing only on short-term results, paying special attention to early problems. However, the authors await the results of a longer-term follow-up.

In conclusion, the clinical and radiographic results of the short stem THA in patients with ONFH are generally satisfactory. Its design enables preservation of the bone stock and the bone trabeculae

appear to confirm the assumption of proximal force transmission. The authors believe that the short stem THA is a promising procedure for patients with ONFH.

What is already known on this topic?

The conventional THA showed satisfactory results in ONFH from many previous studies. The short stem prosthesis showed good results in patients with primary osteoarthritis from many previous studies, however, there were a few studies about the short stem THA in patients with ONFH.

What this study adds?

The clinical and radiographic results of the short stem THA in patients with ONFH are generally satisfactory with low complication rate. The authors believe that the short stem THA is a promising procedure for patients with ONFH.

Acknowledgement

The authors wish to acknowledge Dr. Urawit Piyapromdee MD, for assisting the statistical analysis.

Potentials conflicts of interest

None.

References

1. Kim SM, Lim SJ, Moon YW, Kim YT, Ko KR, Park YS. Cementless modular total hip arthroplasty in patients younger than fifty with femoral head osteonecrosis: minimum fifteen-year follow-up. *J Arthroplasty* 2013; 28: 504-9.
2. Han SI, Lee JH, Kim JW, Oh CW, Kim SY. Long-term durability of the CLS femoral prosthesis in patients with osteonecrosis of the femoral head. *J Arthroplasty* 2013; 28: 828-31.
3. Bedard NA, Callaghan JJ, Liu SS, Greiner JJ, Klaassen AL, Johnston RC. Cementless THA for the treatment of osteonecrosis at 10-year follow-up: have we improved compared to cemented THA? *J Arthroplasty* 2013; 28: 1192-9.
4. Kim YH, Kim JS, Park JW, Joo JH. Contemporary total hip arthroplasty with and without cement in patients with osteonecrosis of the femoral head: a concise follow-up, at an average of seventeen years, of a previous report. *J Bone Joint Surg Am* 2011; 93: 1806-10.
5. Johansson HR, Zywił MG, Marker DR, Jones LC, McGrath MS, Mont MA. Osteonecrosis is not a predictor of poor outcomes in primary total hip arthroplasty: a systematic literature review.

- Int Orthop 2011; 35: 465-73.
6. Johnson AJ, Mont MA, Tsao AK, Jones LC. Treatment of femoral head osteonecrosis in the United States: 16-year analysis of the Nationwide Inpatient Sample. *Clin Orthop Relat Res* 2014; 472: 617-23.
 7. Kamada S, Naito M, Nakamura Y, Shitama T. Total hip arthroplasty using a short stem, stem design, position and size influence the development of bone trabeculae and appearance of radiolucent lines around the stem. *Curr Orthop Pract* 2011; 22: 52-8.
 8. Suksathien Y, Narkbunnam R, Sueajui J. Initial clinical and radiographic results with the short stem THA. *J Med Assoc Thai* 2012; 95 (Suppl 10): S26-31.
 9. Simank HG, Greiner R. Clinical and radiographic short to midterm results with the short hip stem prosthesis "Metha" in 120 cases. *J Orthopaedics* 2010; 7: 4-8.
 10. Wittenberg RH, Steffen R, Windhagen H, Bucking P, Wilcke A. Five-year results of a cementless short-hip-stem prosthesis. *Orthop Rev (Pavia)* 2013; 5: e4.
 11. Ficat RP. Idiopathic bone necrosis of the femoral head. Early diagnosis and treatment. *J Bone Joint Surg Br* 1985; 67: 3-9.
 12. Dorr LD, Faugere MC, Mackel AM, Gruen TA, Bognar B, Malluche HH. Structural and cellular assessment of bone quality of proximal femur. *Bone* 1993; 14: 231-42.
 13. Gruen TA, McNeice GM, Amstutz HC. "Modes of failure" of cemented stem-type femoral components: a radiographic analysis of loosening. *Clin Orthop Relat Res* 1979; (141): 17-27.
 14. Tingart M, Beckmann J, Opolka A, Matsuura M, Schaumburger J, Grifka J, et al. Analysis of bone matrix composition and trabecular microarchitecture of the femoral metaphysis in patients with osteonecrosis of the femoral head. *J Orthop Res* 2009; 27: 1175-81.
 15. Calder JD, Pearse MF, Revell PA. The extent of osteocyte death in the proximal femur of patients with osteonecrosis of the femoral head. *J Bone Joint Surg Br* 2001; 83: 419-22.
 16. Wang YS, Liu M, Li JW, Hao YJ, Li JF, Yang J, et al. Application of CFP short-stem prosthesis in the treatment of osteonecrosis of the femoral head. *Zhonghua Yi Xue Za Zhi* 2011; 91: 3320-3.
 17. Zeh A, Weise A, Vasarhelyi A, Bach AG, Wohlrab D. Medium-term results of the Mayo short-stem hip prosthesis after avascular necrosis of the femoral head. *Z Orthop Unfall* 2011; 149: 200-5.
 18. Floerkemeier T, Tscheuschner N, Calliess T, Ezechieli M, Floerkemeier S, Budde S, et al. Cementless short stem hip arthroplasty METHA(R) as an encouraging option in adults with osteonecrosis of the femoral head. *Arch Orthop Trauma Surg* 2012; 132: 1125-31.
 19. Morrey BF, Adams RA, Kessler M. A conservative femoral replacement for total hip arthroplasty. A prospective study. *J Bone Joint Surg Br* 2000; 82: 952-8.
 20. Lerch M, der Haar-Tran A, Windhagen H, Behrens BA, Wefstaedt P, Stukenborg-Colsman CM. Bone remodelling around the Metha short stem in total hip arthroplasty: a prospective dual-energy X-ray absorptiometry study. *Int Orthop* 2012; 36: 533-8.

การศึกษาผลทางคลินิกของการผ่าตัดเปลี่ยนข้อสะโพกเทียมชนิดก้านสั้นในผู้ป่วยกระดูกหัวสะโพกขาดเลือด

ยิ่งยง สุขเสถียร, จิรายุทธ เสือจัญ

ภูมิหลัง: ผลทางคลินิกของการผ่าตัดเปลี่ยนข้อสะโพกเทียมชนิดก้านสั้นในผู้ป่วยข้อสะโพกเสื่อมได้ผลดี แต่ยังมีการศึกษาน้อยในผู้ป่วยกระดูกหัวสะโพกขาดเลือด

วัตถุประสงค์: ศึกษาผลทางคลินิกของการผ่าตัดเปลี่ยนข้อสะโพกเทียมชนิดก้านสั้นในผู้ป่วยกระดูกหัวสะโพกขาดเลือด

วัสดุและวิธีการ: ศึกษาในผู้ป่วยผ่าตัดเปลี่ยนข้อสะโพกเทียมชนิดก้านสั้น 120 ราย เก็บข้อมูล Harris hip score ที่ 6, 12, 24 และ 36 เดือน

ผลการศึกษา: ผู้ป่วยมีอายุเฉลี่ย 44.4 ปี (18-68 ปี) ค่าเฉลี่ย BMI 22.7 (15.1-32.5) ระยะติดตามการรักษาเฉลี่ย 29.2 เดือน (20-47 เดือน) ค่าเฉลี่ย Harris hip score ที่ 6 เดือน เพิ่มขึ้นอย่างมีนัยสำคัญ พบ bone trabeculae เกิดที่โซน 1 (64.2%) โซน 2 (22.5%) โซน 3 (88.3%) โซน 6 (100%) และโซน 7 (95.8%) พบ 1 ราย ที่ข้อเทียมจมลง 5 ม.ม. และพบ radiolucent line ที่โซน 1 (0.8%) พบกระดูกแตกระหว่างผ่าตัด 6 ราย (5%)

สรุป: ผลการผ่าตัดเปลี่ยนข้อสะโพกเทียมชนิดก้านสั้นในผู้ป่วยกระดูกหัวสะโพกขาดเลือดได้ผลดี พบภาวะแทรกซ้อนน้อย
