

An Investigation of Antimicrobial and Wound Healing Potential of *Allium ascalonicum* Linn.

Suphaket Saenthaweesuk MSc*, Rungrat Jitvaropas PhD*,
Nuntiya Somparn PhD*, Amornnat Thuppia MSc*

* Department of Preclinical Science, Faculty of Medicine, Thammasat University, Rangsit Campus,
Pathumthani, Thailand

Background: The pharmacological properties of *Allium ascalonicum* Linn., commonly called shallot, have been reported as including those that are antibacterial and antioxidant.

Objective: The present study aimed to evaluate the antimicrobial effect and wound-healing activity of the ethanolic extracts of *Allium ascalonicum* Linn. (AAE).

Material and Method: The antimicrobial activity of AAE was tested in vitro against using the disc diffusion method and a broth micro-dilution technique to determine the minimal inhibition concentrations (MIC) and the minimal microbicidal concentrations (MMC). Wound-healing activity of the extract was performed on rat test subjects.

Results: The AAE showed potential antimicrobial activity by inhibiting gram-positive bacteria *Staphylococcus epidermidis* and *Bacillus subtilis* ATCC 6633. MIC and MMC varied from 25-50 mg/ml and 25-200 mg/ml, respectively. After surgery 14 days, wound contractions of treated groups and standard group were $78.61 \pm 1.20\%$, $78.55 \pm 1.93\%$ and 100% , respectively; but, in the control group, wound contraction was $64.90 \pm 3.55\%$. Histological studies showed the complete epidermis and found the collagen fibers and fibroblasts as similar appearance as standard group in dermis. The results of histological evaluation have confirmed remarkable wound-healing activities of AAE.

Conclusion: Taken together, the present study provides evidence that AAE extract processes antimicrobial and wound-healing activities.

Keywords: *Allium ascalonicum* Linn., Antimicrobial activity, Wound-healing

J Med Assoc Thai 2015; 98 (Suppl. 2): S22-S27

Full text. e-Journal: <http://www.jmatonline.com>

Wounds are physical injuries that may be produced by physical, chemical, thermal, microbial or immunological assault to the tissues that results in an opening or breaking of the skin. Proper healing of wounds is essential for the restoration of disrupted anatomical continuity and disturbed functional status of the skin. Wound healing is a complex multi-factorial process involving the contraction and closure of the wound, restoration of a functional barrier, platelet aggregation, blood clotting, formation of fibrin, inflammatory response to injury, alteration in the ground substances, angiogenesis and re-epithelialization⁽¹⁾.

In developing countries, infections in wounds are most commonly caused by poor hygienic conditions. The pathology of the infection usually

involves *Staphylococcus aureus*, *Streptococcus pyogenes*, *Escherichia coli*, *Pseudomonas aeruginosa*, *Streptococcus pneumoniae* or *Klebsiella pneumoniae*⁽²⁾. In this case, a wide range of antibiotics is being used for treating wound infections, but they are now proved to have adverse effects in the human body; also, these pathogens developed resistance to the antibiotics targeted against them. Thus, natural products, which do not have any serious side effects, are now considered.

Allium ascalonicum Linn. (AAE), commonly called shallot, is an annual herbaceous plant of the family Liliaceae that grows in many parts of the world. AAE contains several photochemicals including mannose-specific lectin⁽³⁾, antifungal peptide⁽⁴⁾, saponins⁽⁵⁾ and various flavonol glucosides⁽⁶⁾. Furthermore, the pharmacological properties of AAE have been reported, including antibacterial and antifungal properties^(7,8), antioxidant properties⁽⁹⁾ and anti-*Helicobacter pylori*⁽¹⁰⁾. Therefore, the authors' interest is to investigate antimicrobial and wound-healing effects of AAE ethanolic extract in rats.

Correspondence to:

Saenthaweesuk S, Division of Anatomy, Department of Preclinical Science, Faculty of Medicine, Thammasat University, Rangsit Campus, Khlongluang, Pathumthani 12120, Thailand.
Phone: +66-2-9269729, Fax: +66-2-9269711
E-mail: suphaket18_s@hotmail.com

Material and Method

Plant material

Dry bulbs of shallot were purchased from a Thai market in Pathumthani, Thailand, during July-August 2011. The collected plant material was washed thoroughly in water, cut into small pieces and soaked in 95% ethanol at a ratio of 1:1 for one night at room temperature. The filtrates were concentrated by rotary vacuum evaporation and then lyophilized with a freeze dryer. The extract was kept at -80°C for analysis. A light brown solid extract with a yield of 1.68% was obtained.

Phytochemical analysis

The ethanolic extract was screened for the presence of any phyto constituents according to the methods described by Harborne⁽¹¹⁾. The authors found that AAE contained flavonoids, alkaloids and phenolic compounds, but lacked any tannins and saponins.

Test microorganisms

The test microorganisms used for the antimicrobial activity screening were 6 bacteria and 2 fungi: (gram-positive and gram-negative) *Staphylococcus aureus* ATCC (25923), *Staphylococcus epidermidis*, *Bacillus subtilis* ATCC (6633), *Escherichia coli* ATCC (2592), *Klebsiella pneumoniae* and *Pseudomonas aeruginosa*, and the 2 fungi *Candida albicans* ATCC (10231) and *Saccharomyces cerevisiae*.

Antimicrobial activity

The turbidity of bacterial suspensions was adjusted to 0.5 McFarland turbidity. The basic 0.5 McFarland standard contains approximately 1x10⁸ cfu/mL. Bacteria were cultured in Mueller-Hinton broth (MHB; Difco, Becton Dickinson), whereas fungi were cultured in Sabouraud Dextrose Broth (SDB; Difco, Becton Dickinson). Fungal suspensions consisted of evenly swab-inoculated surfaces of Mueller-Hinton agar (MHA; Difco, Becton Dickinson) and Sabouraud Dextrose Agar (SDA), respectively. Each sterile blank disc (Difco, Becton Dickinson) (6 mm in diameter) was impregnated with 20 µL (6 mg/disc) of the extract and dried at 25°C aseptically. After complete drying, the discs (in triplicate) were placed on the surfaces of agar plates that were pre-inoculated with test bacterial cultures and incubated at 37°C for 18-24 h. Dimethyl sulfoxide (DMSO) was used as the negative control. Gentamycin 10 µg/disc for bacteria and amphotericin B 30 µg/disc for fungi were used as standard antibiotic for comparison with the extracts. The size of the zones of inhibition was measured using a Pakimeter, and the

antimicrobial activity was expressed in terms of the average diameter in mm of the zone of inhibition. The absence of a zone of inhibition (≤ 6 mm) was interpreted as the absence of activity.

Determination of minimum inhibitory concentration (MIC)

For MIC determination, 0.5 McFarland turbidity of bacterial culture, diluted 200 times, was added to a 96-well culture plate. Different concentrations of crude extract were added. For the negative control, 2% DMSO was used. The plate was shaken at 130 rpm at 37°C overnight, and then 20 µL of 1 mg/ml resazurin was added to each well. The color change was then assessed visually. Any color changes from violet to pink or colorless were recorded as positive.

Determination of minimum microbicidal concentration (MMC)

MMC was determined by sub-culturing the test dilution on to a fresh drug-free solid medium and incubating further for 18-48 h. The highest dilution that yielded no single bacterial or yeast colony on a solid medium was taken as the MMC. Three independent experiments were performed for all data.

Experimental animals

Twenty-four male Sprague Dawley rats were selected for the experiment. The animals were obtained from the National Laboratory Animal Center, Salaya, Mahidol University. The animals were housed under specific standard laboratory conditions for 1 week prior to experimentation. The conditions were kept under standard environmental control with a temperature of 25±1°C, a humidity of 60% and a 12 h light and 12 h dark cycle. All animals were fed with free standard rat chow (CP feed product) and water ad libitum. For the purpose of the study, the animals were divided into four groups (n = 6): group I was the negative control group which received pure petroleum gel; groups II and III were the treated groups receiving the AAE, which was mixed with pure petroleum gel to a final concentration of 10% (w/w) and 20% (w/w), respectively; and group IV was the positive control group treated with Terramycin ointment. All animals were topically applied once a day for 2 weeks. The animals were kept individually in separate cages.

Excision wound model

All animals were anesthetized with anesthetic ether before being shaved and subject to wound

creation. The excision wound was inflicted by use of a punch biopsy instrument. A 4-cm² area of a full thickness of skin was excised in the dorsal inter-scapular region. Rat wounds were left undressed and exposed to the open environment. The area of wound was measured in mm by vernier caliper on days 4, 8, 12 and 14 post-surgery. Wound contraction was expressed as percentage reduction of original wound size. Experimental protocols were approved by the Ethics Review Committee of the Faculty of Medicine, Thammasat University, Thailand under the number AE 004/2553.

Histological examination

At the end of the experiment, the animals were sacrificed and the wound areas were dissected, collected and fixed in 10% Neutral Buffered Formalin (NBF). The samples were processed in graded series of alcohol and embedded in paraffin wax, sectioned at 5 µm, stained with hematoxylin and eosin (H&E) for histological examination.

Statistical analysis

All values are reported at a mean ± SD and the statistical significance of differences among groups were assessed using one-way ANOVA. A value of $p < 0.05$ was considered significant.

Results

Antimicrobial activity of AAE

The antimicrobial activity of AAE was explored by the disc diffusion method. Inhibition diameter zones (IDZ) were produced on gram-positive bacteria *Staphylococcus epidermidis* and *Bacillus subtilis* (10.20±0.36 and 8.27±0.23 mm, respectively), and the MIC and MMC varied from 25-50 mg/ml and 25-200 mg/ml, respectively. Good activity was observed against the gram-positive bacteria, but the extracts were inactive against the gram-negative bacteria and fungal suspensions (Table 1).

Effect of AAE on wound-healing activity

Wound-healing activity of AAE was carried out on rats using excision-wound models to verify the claimed traditional use of the extract on a scientific basis. Treatment with 10% and 20% AAE showed significant wound-healing activity (% wound contraction) on days 8, 12 and 14 when compared with the control group. On day 14 of post-surgery, percentages of wound contraction in the 10% AAE, 20% AAE and positive control groups were

Table 1. Antimicrobial of activity of AAE and the MIC and the MMC values of the extracts against the microorganism

Microorganism	Inhibition diameter zone (mm)			MIC		MMC	
	AAE (mg/ml)	Standard (10 µg/disc)	AAE (mg/ml)	AAE (mg/ml)	Standard (µg/ml)	AAE (mg/ml)	Standard (µg/ml)
Bacteria strains Gram positive bacteria	<i>Staphylococcus aureus</i>	No	26.53±0.33	25	0.625	200	5.000
	<i>Staphylococcus epidermidis</i>	10.20±0.36	29.18±0.11	50	1.250	100	1.250
	<i>Bacillus subtilis</i>	8.27±0.23	23.62±0.25	25	1.250	25	1.250
Gram negative bacteria	<i>Escherichia coli</i>	No	19.58±0.31	No	No	No	No
	<i>Klebsiella pneumoniae</i>	No	18.33±0.45	No	No	No	No
	<i>Pseudomonas aeruginosa</i>	No	19.15±0.40	No	No	No	No
Fungal strains	<i>Candida albican</i>	No	13.40±0.10	No	0.625	No	1.250
	<i>Saccharomyces cerevisiae</i>	No	13.13±0.12	No	0.312	No	0.312

Values are mean ± SD of triplicates experiments Gentamycin and Amphotericin B are standards for bacteria and fungus, respectively

78.61±1.20%, 78.55±1.93% and 100%, respectively; but, in the normal control group, wound contraction was 64.90±3.55%. Results indicated that wound-healing activity of AAE was comparable to that of positive control (Fig. 1).

Histological examination of skin wounds

The skin area surrounding the wound was removed for histological examination. Interestingly, treatment with 10% AAE, 20% AAE and Terramycin ointment showed fully recovered epidermis on day 8, whereas a fully recovered epidermis in the normal control group was found on day 12. Besides a fully recovered epidermis, active fibroblasts, blood vessels and collagen fiber were also found in the dermis on day 8. Moreover, promoting fibroblast migration and collagen deposition were more apparent in the AAE-treated group as compared to other groups. The microanatomy of the wounds had a similar appearance in all groups on day 14 (Fig. 2). Thus, the results indicated that treatment with AAE accelerated the wound-healing process.

Discussion

A wound is the disruption of the cellular and anatomic continuity of tissue. All wounds interrupt the local environment and homeostasis within the tissue and result in bleeding, contraction of vessels, coagulation, activation of tissue complement and other inflammatory responses⁽¹²⁾. Normally, the mechanism of tissue response to injury depends on the healing

process that helped sustain the restoration of the anatomical structure of the cells and functional integrity of that tissue. However, wound repair is not a simple process and can be complicated by processes such as cell-cell and cell-matrix interactions mediated by humoral messengers and function⁽¹³⁾. When a wound is exposed to the environment, it is most likely to be invaded by various microorganisms, which attack through the skin and delay the natural wound-healing process⁽¹⁴⁾. There has been reported that the water extract of shallot inhibits activity of *Bacillus subtilis*⁽¹⁵⁾. Surprisingly, our results demonstrated that AAE also has an antibacterial activity by inhibition of gram-positive bacteria (*Staphylococcus epidermidis* and *Bacillus*

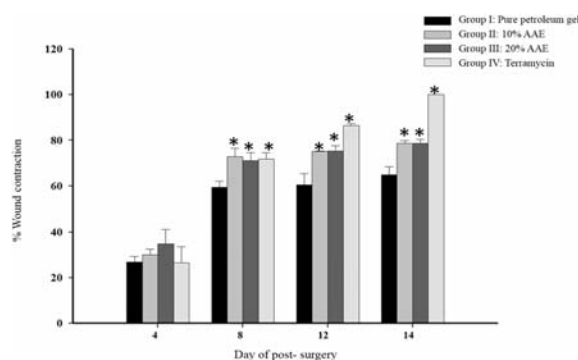


Fig. 1 Effect of AAE on healing of wound excision. Values are mean ± SD for six rats; * statistically significant difference in comparison with control group. $p < 0.05$.

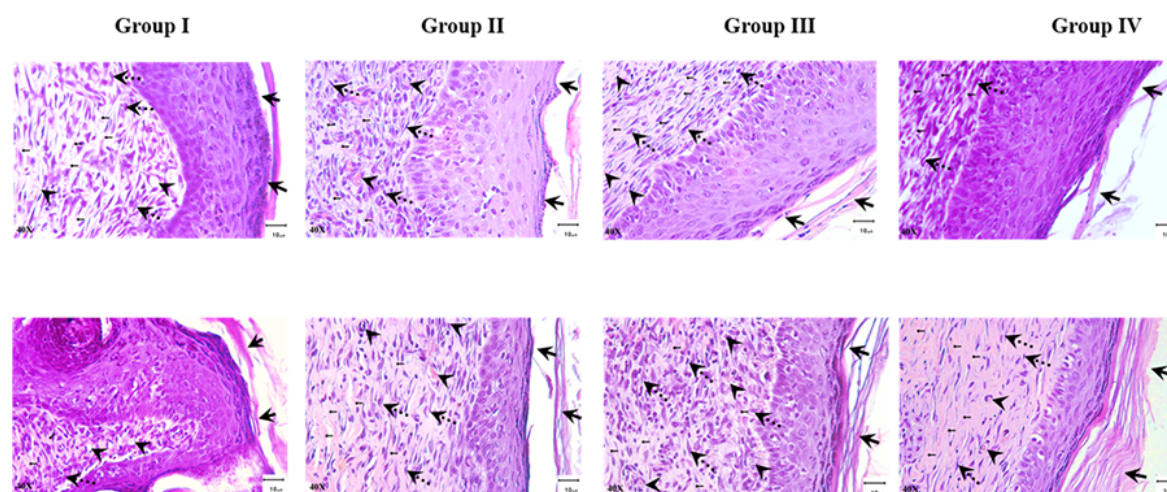


Fig. 2 Microscopic view of excision wound healing and epidermal/dermal re-modeling in the pure petroleum gel (Group I), 10% AAE (Group II), 20% AAE (Group III) and Terramycin (Group IV) administered animals on days 8 and 14. The results showed 40X magnification. ← = collagen fiber; ← = epidermis; ← = fibroblast; ← = blood vessel.

subtilis). The external application of the extract on wound prevents the microbes to invade through the wound, resulting protection of wound against the infection of the various organisms. This effect of AAE is probably due to its compounds in the crude extract, showing the possibility of antimicrobial activity. Therefore, its antimicrobial action is the important effect in protection the accelerated wound infection.

Allium ascalonicum extract components, especially flavonoids, alkaloids and phenolic compounds, possess the free radical scavenging effect, showing the possibility of antioxidant activity as compared to several onion varieties and some garlic preparations is more noticeable^(9,16). The AAE has been also reported to exhibit anti-oxidative and free radical scavenging capacities. These properties appear to be related to the high contents of flavone, sulfur-containing compounds and polyphenolic derivatives in the bulb of this plant. Anti-oxidant properties help prevent cells from being destroyed and increasing the ability of the growth of collagen fibril^(17,18). Suntar et al⁽¹⁹⁾ reported that the effect of antioxidants, especially flavonoids, contribute to the healing of wounds. The repairs of wounds involve different phases including contraction, formation of epithelialization and fibrosis. The present study showed that the AAE-treated groups possess fully recovered epidermis, fibroblast migration and collagen fiber depositions in dermis.

Conclusion

The present study provides evidence that the AAE has antimicrobial activity in vitro and processes the wound-healing effect by accelerating the wound-healing process in excision-wound model rats.

Acknowledgement

This work was supported by a grant from the Faculty of Medicine, Thammasat University, Thailand under grant number: MTU-AT-3-112/52.

Potential conflicts of interest

None.

References

1. Chattopadhyay D, Arunachalam G, Mandal AB, Sur TK, Mandal SC, Bhattacharya SK. Antimicrobial and anti-inflammatory activity of folklore: *Mallotus peltatus* leaf extract. *J Ethnopharmacol* 2002; 82: 229-37.
2. Mertz PM, Ovington LG. Wound healing microbiology. *Dermatol Clin* 1993; 11: 739-47.
3. Mo H, Van Damme EJ, Peumans WJ, Goldstein IJ. Purification and characterization of a mannose-specific lectin from Shallot (*Allium ascalonicum*) bulbs. *Arch Biochem Biophys* 1993; 306: 431-8.
4. Wang HX, Ng TB. Ascalin, a new anti-fungal peptide with human immunodeficiency virus type 1 reverse transcriptase-inhibiting activity from shallot bulbs. *Peptides* 2002; 23: 1025-9.
5. Fattorusso E, Iorizzi M, Lanzotti V, Tagliatalata-Scafati O. Chemical composition of shallot (*Allium ascalonicum* Hort.). *J Agric Food Chem* 2002; 50: 5686-90.
6. Bonaccorsi P, Caristi C, Gargiulli C, Leuzzi U. Flavonol glucosides in *Allium* species: A comparative study by means of HPLC-DAD-ESI-MS-MS. *Food Chemistry* 2008; 107: 1668-73.
7. Yin MC, Tsao SM. Inhibitory effect of seven *Allium* plants upon three *Aspergillus* species. *Int J Food Microbiol* 1999; 49: 49-56.
8. Amin M, Kapadnis BP. Heat stable antimicrobial activity of *Allium ascalonicum* against bacteria and fungi. *Indian J Exp Biol* 2005; 43: 751-4.
9. Leelarungrayub N, Rattanapanone V, Chanarat N, Gebicki JM. Quantitative evaluation of the antioxidant properties of garlic and shallot preparations. *Nutrition* 2006; 22: 266-74.
10. Adeniyi BA, Anyiam FM. In vitro anti-Helicobacter pylori potential of methanol extract of *Allium ascalonicum* Linn. (Liliaceae) leaf: susceptibility and effect on urease activity. *Phytother Res* 2004; 18: 358-61.
11. Harborn AJ. *Phytochemical methods: a guide to modern techniques of plant analysis*. 2nd ed. London: Chapman and Hall; 1998.
12. Isenberg JS, Ridnour LA, Espey MG, Wink DA, Roberts DD. Nitric oxide in wound-healing. *Microsurgery* 2005; 25: 442-51.
13. Smith R. Recovery and tissue repair. *Br Med Bull* 1985; 41: 295-301.
14. Church D, Elsayed S, Reid O, Winston B, Lindsay R. Burn wound infections. *Clin Microbiol Rev* 2006; 19: 403-34.
15. Amin M, Montazeri EA, Mashhadizadeh MA, Sheikh AF. Characterization of shallot, an antimicrobial extract of *Allium ascalonicum*. *Pak J Med Sci* 2009; 25: 948-52.
16. Yang J, Meyers KJ, van der Heide J, Liu RH. Varietal differences in phenolic content and antioxidant and antiproliferative activities of onions. *J Agric Food Chem* 2004; 52: 6787-93.
17. Getie M, Gebre-Mariam T, Rietz R, Neubert RH.

- Evaluation of the release profiles of flavonoids from topical formulations of the crude extract of the leaves of *Dodonea viscosa* (Sapindaceae). *Pharmazie* 2002; 57: 320-2.
18. Shetty S, Udupa S, Udupa L. Evaluation of Antioxidant and Wound Healing Effects of Alcoholic and Aqueous Extract of *Ocimum sanctum* Linn in Rats. *Evid Based Complement Alternat Med* 2008; 5: 95-101.
19. Suntar I, Tail II, Akkol EK, Keles H, Kahraman C, Akdemir Z. An ethnopharmacological study on *Verbascum species*: from conventional wound healing use to scientific verification. *J Ethnopharmacol* 2010; 132: 408-13.

การศึกษาความสามารถในการต้านเชื้อจุลินทรีย์และการรักษาแผลของสารสกัดหอมแดง

ศุภกฤต แสตนทวีสุข, รุ่งรัตน์ จิตวิโรภาส, นันทิยา สมภาร, อมรณัฐ ทับเปี้ย

ภูมิหลัง: มีการกล่าวถึงสรรพคุณทางยาของหอมแดงว่ามีฤทธิ์ต้านเชื้อจุลินทรีย์และเป็นสารต้านอนุมูลอิสระ

วัตถุประสงค์: เพื่อศึกษาฤทธิ์การต้านเชื้อจุลินทรีย์และฤทธิ์ในการสมานแผลของสารสกัดหอมแดงที่สกัดด้วยเอทานอล

วัสดุและวิธีการ: การศึกษาความสามารถในการต้านเชื้อจุลินทรีย์ ด้วยวิธีการศึกษาการยับยั้งการเจริญเติบโตบนอาหารรูนแข็ง หาค่าความเข้มข้นที่น้อยที่สุดของสารสกัดที่สามารถยับยั้งการเจริญเติบโตของเชื้อจุลินทรีย์ (MIC) และค่าความเข้มข้นที่น้อยที่สุดของสารสกัดที่สามารถฆ่าเชื้อจุลินทรีย์ (MMC) และการศึกษาฤทธิ์ของสารสกัดในการสมานแผลทำในหนูทดลอง

ผลการศึกษา: สารสกัดหอมแดงที่สกัดด้วยเอทานอลมีฤทธิ์ต้านเชื้อจุลินทรีย์ โดยยับยั้งการเจริญเติบโตของเชื้อจุลินทรีย์แกรมบวก 2 สายพันธุ์คือ *Staphylococcus epidermidis* และ *Bacillus subtilis* ATCC 6633 โดยมีค่า MIC และ MMC อยู่ในช่วง 25-50 มิลลิกรัม/มิลลิลิตร และ 25-200 มิลลิกรัม/มิลลิลิตร ตามลำดับ หลังจากผ่าตัด 14 วัน พบว่ากลุ่มที่ได้รับสารสกัดทั้ง 2 ขนาด และกลุ่มที่ได้รับยามาตรฐาน มีร้อยละการหดตัวของบาดแผลเป็น 78.61±1.20, 78.55±1.93 และ 100 ตามลำดับ แต่พบว่าในกลุ่มควบคุมมีร้อยละการหดตัวของบาดแผลเป็น 64.90±3.55 การศึกษาลักษณะทางจุลกายวิภาคของบาดแผลพบว่า หนึ่งกำพร้ามีการสร้างอย่างสมบูรณ์ ในชั้นหนังแท้พบเส้นใยคอลลาเจนและไฟโบรบลาสมีลักษณะคล้ายคลึงกับกลุ่มควบคุม ซึ่งลักษณะดังกล่าวยืนยันได้ว่าสารสกัดหอมแดงมีฤทธิ์ในการสมานแผล

สรุป: สารสกัดหอมแดงที่สกัดด้วยเอทานอลมีทั้งฤทธิ์ต้านเชื้อจุลินทรีย์และฤทธิ์ในการสมานแผล
