

Management of Fibular Hemimelia Using the Ilizarov Method at Siriraj Hospital in Thailand

Prangthong Unprasert MD*, Kamolporn Kaewpornasawan MD*,
Chatupon Chotigavanichaya MD*, Perajit Eamsobhana MD*

* Department of Orthopedic Surgery, Faculty of Medicine Siriraj Hospital, Mahidol University, Bangkok, Thailand

Background: Fibular hemimelia is one of the most common congenital longitudinal bone deficiencies. Previous treatment protocols called for amputation of the deficient limb; while others made attempts to save the limb. The objective of treatment is to restore function and achieve patient satisfaction. The authors evaluated the outcomes of the Ilizarov technique for the treatment of leg-length discrepancy and bone associated deformities in patients with fibular hemimelia. The present study also evaluated and assessed complications, knee and ankle function, and patient satisfaction with the treatment.

Material and Method: Nine patients with fibular hemimelia who underwent tibial lengthening using the Ilizarov method were reviewed in the present study. Initial condition data, including age, gender, type of fibular hemimelia, initial limb-length discrepancy, predicted limb-length discrepancy, and the data were collected and analyzed. Activity level, patient satisfaction, complications, and residual leg-length discrepancy were assessed at the end of treatment.

Results: According to Achterman and Kalamchi classification, there were 4 patients with Type IA, 3 patients with Type IB, and 2 patients with Type II. In Type IA, the affected leg-length discrepancy and mean age at the initial treatment were 3.25 cm and 7.75 years, respectively. In type IB, the affected leg-length discrepancy and mean age at the initial treatment were 5.83 cm and 4.3 years, respectively. In Type II, the affected leg-length discrepancy and mean age at the initial treatment were 5.5 cm and 5 years, respectively. The mean follow-up was 5 years (range: 7-10). The mean lengthening was 7.52 cm (range: 4-13). The lengthening index was 1.28 mo/cm. The mean residual leg-length discrepancy was 0.94 cm. There was ankle joint stiffness and mild equinus foot in type II cases, but patients could walk well without gait aid. No patients were experiencing pain by the end of treatment. All patients expressed satisfaction with this technique.

Conclusion: The Ilizarov technique for bone lengthening of the tibia has shown satisfactory results in the treatment of all types of congenital fibular hemimelia and should be considered an attractive alternative to amputation, as measurable functional improvement can be expected.

Keywords: Fibula hemimelia, Leg-length discrepancy, Ilizarov method, Syme's amputation

J Med Assoc Thai 2014; 97 (Suppl. 9): S44-S49

Full text. e-Journal: <http://www.jmatonline.com>

Fibular hemimelia is characterized by the partial or total absence of the fibula⁽¹⁾. It is recognized as the most common deformity of the long bones⁽²⁾ and is usually associated with other anomalies, such as a spectrum of abnormalities affecting the femur, knee, tibia, ankle, and foot. There are many classifications for fibular hemimelia. Fibular hemimelia is classified using the Achterman and Kalamchi classification and this classification is used worldwide. There are two types of fibular hemimelia: type I is characterized by hypoplasia of the fibula and type II is characterized by the total absence of the fibula. Type I is also divided

into two subtypes by the severity of the partially absent fibula: A: loss of the proximal part of the fibula; and, B: loss of more than 30 percent of the fibula⁽³⁾. Type II sometimes has associated deformities, such as tibial malalignment, shortening of the tibia and/or femur, and almost always equinovalgus of the foot.

The objective of treatment is to allow the patient return to normal life as soon as possible after treatment. Many methods, such as shoe-lift, step-in prostheses, epiphysiodeses, bone-lengthening procedures, and corrective operations of the foot have been used in the past. For cases with more associated and/or complicated deformities, treatments have been more challenging. The Ilizarov method has come to be accepted as one of the most successful foot preservation and leg bone correction treatments⁽⁴⁻⁶⁾. These procedures sometimes fail to achieve satisfactory outcome and time resume procedure, many

Correspondence to:

Eamsobhana P, Department of Orthopedic Surgery, Faculty of Medicine Siriraj Hospital, Mahidol University, Bangkok 10700, Thailand.

Phone: 08-9674-3554

E-mail: peerajite@gmail.com

additional operations may be needed and some cases may result in amputation⁽⁷⁾. Some surgeons prefer Syme's amputation and report good results after prosthesis fitting. In Asian culture, many families deny the amputation alternative, even in cases with severe deformities.

The objective of the present study was to assess the result of limb-lengthening with the Ilizarov method in patients with fibular hemimelia.

Material and Method

Nine patients who were diagnosed with fibular hemimelia and who were treated from 2002 to 2012 were included in this study. According to the Achterman and Kalamchi classification⁽⁴⁾, four patients were Type IA, three patients were Type IB, and two patients were Type II. There were four females and five males. Three cases were on the right side of the body and six cases on the left. Before treatment, all patients had shortening of the affected leg with some associated deformities (Table 1). Pre-operative evaluation and long-leg standing films were used to assess the axis alignment of the affected leg. Orthoroengenogram was used to measure leg-length discrepancies, anatomical axis, mechanical axis deviations, and foot deformities. The Ilizarov fixator was applied with two whole rings using 1.6 mm K-wires. The lengthening was performed by combining tibial osteotomy with the Ilizarov system. Lengthening through a proximal tibial metaphyseal osteotomy was performed at 1 week after surgery by parents until equal length was achieved. Distraction speed for bone lengthening procedures was 1 mm/day. After bone union and equality of bone length was achieved, the Ilizarov fixator was removed. In patients with equinovalgus foot, second stage foot reconstruction and soft tissue release was performed.

The authors followed the patient in the latent phase, distraction phase, and the consolidation phase for every 2 weeks, 1 month, and last for every 6 months at 2 weeks, 1 month, and every 6 months, thereafter. At the last follow-up visit, we evaluated the ankle by grading the ankle according to the activity level of the patient. Patients were requested to grade their level of satisfaction with the Ilizarov method in the areas of ankle function, pain, and cosmetic outcome. Complications and residual length discrepancy at the last visit were also documented (Table 1).

Results

In the type IA cases, the mean leg-length discrepancy and mean age at the initial treatment were

Table 1. Patient characteristics and results

Sex	Initial age	Type*	Side	LLD** (CM)	Predicted shortening (CM)	No. of surgeries	Lengthening (CM)	Lengthening index (mo/cm)	Associated deformity	Satisfaction	Activity level***	FADI
Male	9	IA	L	3	4.14	3	4	2	Femoral shortening	y	1	100
Female	4	IB	L	3.5	6.44	2	6	2	Absent 5 th toe	y	0	100
Male	6	IA	L	4	6.28	2	6	0.9		y	1	100
Male	2	IA	R	2	4	2	4	1.11		y	0	100
Male	7	IB	R	8	12.56	4	I= 6II= 6	I= 1.25II= 1.11	Valgus knee	y	1	98.1
Female	2	IB	L	6	14.34	4	I= 6.7II= 6.3	I= 1III= 1.43	Absent 4 th , 5 th toe, equinovalgus foot	y	1	98.1
Female	14	IA	R	4	4	2	4	0.83		y	0	100
Female	7	II	L	5	7.15	2	6	1.43	equinovalgus foot	y	1	98.1
Male	3	II	L	6	13.44	4	I= 6.5II= 6.2	I= 0.9II= 1.43	Absent 4 th , 5 th toe, equinovalgus foot	y	1	98.1

* Achterman and Kalamchi classification

** Limb length discrepancy

*** Activity level graded from 0 - 3 (0 = no restriction, 1 = mild restriction with strenuous activity, 2 = moderate limitation of activity, 3 = severe limitation of activity)

3.25 cm and 7.75 years, respectively. In the type IB cases, the mean affected leg-length discrepancy and mean age at the initial treatment were 5.83 cm and 4.3 years, respectively. In the type II cases, the mean affected leg-length discrepancy and mean age at the initial treatment were 5.5 cm and 5 years, respectively (Table 1). Mean follow-up was 5 years (range: 7-10). The mean lengthening was 7.52 cm (range: 4-13). The mean residual leg-length discrepancy was 0.94 cm. The lengthening index was 1.28 mo/cm. The mean number of surgical procedures was 2.7 operations/patient. There was ankle joint stiffness and mild equinus foot in type II cases. All patients could walk well without gait aid and with no pain. All patients and family members reported satisfaction with the outcomes. The Foot and Ankle Disability Index (FADI) was used to evaluate each case and the mean score was 99.16⁽⁷⁾. Associated deformities included 1 femoral shortening (1 cm), 3 equinovagis feet, 1 valgus knee, 1 lacked one ray, and 2 lacked 2 rays (Table 1).

Foot reconstruction

Three feet in the present study showed severe equinovagis deformity, but all were corrected by foot osteotomy with soft tissue release. The ankles were all stiff and had mild type II equinus foot, but no pain was reported. The other six cases could walk independently without gait aid and performed normal daily activities without pain (Fig. 1).

Bone-lengthening technique

Patient case data are shown in Table 1. The total amount of tibial lengthening in each patient ranged from 2 cm to 14 cm. Tibial bone consolidation was completed in all cases. No non-union, malunion, or neurovascular complications were observed in any of the patients. The lengthening index ranged from 0.83 to 2. There were three patients who had to do the bone lengthening for two times (Fig. 2).

Complications in the series

Superficial pin tract infection occurred in three of the Ilizarov lengthening cases, with all being treated with oral antibiotics and local wound care.

Discussion

The goals of managing fibular hemimelia cases include, managing the limb deficiency, correcting bone angulations, and achieving a well, plantigrade, and painless foot. Previously, for patients with severe foot deformities with a predicted severe limb-length

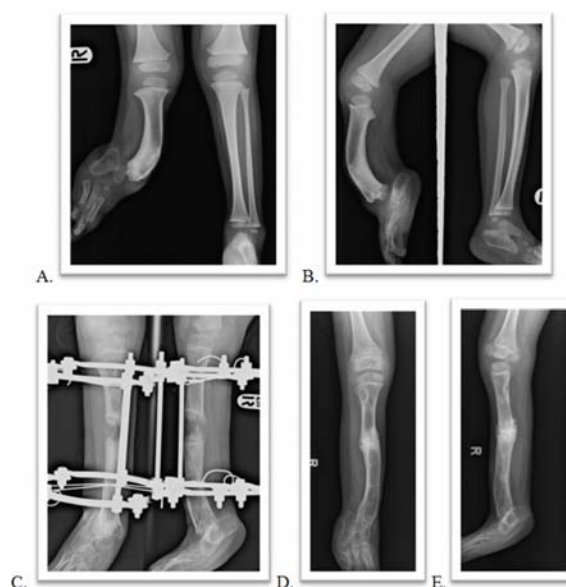

Fig. 1 Fibular hemimelia Type II is shown above A, B) Preoperative standing radiograph of a three-year old boy presenting with right fibular hemimelia Type II with a limb-length discrepancy of 6 cm at initial and absent 2 toes C) Radiograph of lengthening using the Ilizarov method D, E) Postoperative radiograph at follow-up after bone lengthening, showing mild equinus foot.

discrepancy, Syme's or Boyd amputation was performed followed by prosthesis rehabilitation. Many authors in the past recommended early amputation of the foot and the start of early prosthetic rehabilitation with reported good results⁽⁸⁻¹⁴⁾. The advantages of amputation include a single surgical procedure with a short hospital stay, almost immediate walking, and an equalization of leg length so that the child can return to a functional life as quickly as possible. In Thai culture, people live inside the house with bare feet and a sensate foot is needed. A heavy, warm prosthesis is unacceptable for them. As such, they are willing to accept multiple operations instead with the objective of preserving the foot. They prefer treatment with the Ilizarov method, since the Ilizarov method of limb lengthening provides an attractive alternative treatment to amputation. Many surgeons are able to preserve the patient's leg and are able to correct the shortening problem^(15,16). The primary disadvantages include multiple operations and long hospital stays in order to correct the leg shortening or the deformities of the foot. A psychosocial evaluation of the patient must be conducted to determine if the patient is able to cope

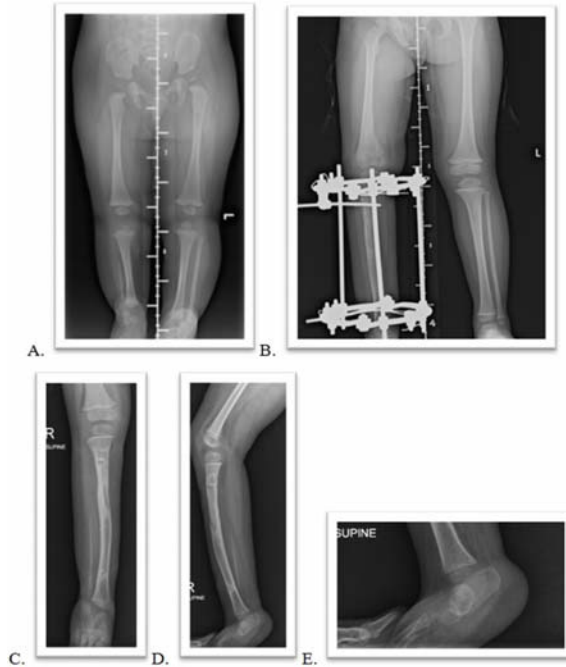


Fig. 2 Fibular hemimelia type Ib is shown above A) Preoperative standing radiograph of six-month old girl presenting with right fibular hemimelia type Ib with a limb-length discrepancy of 7 cm at initial and absent a toe B) Radiograph of lengthening using the Ilizarov method showing equal limb length with good bone consolidation C-E) Postoperative radiograph of 33-month-old girl after bone lengthening, showing mild equinus foot.

with the demands of this complex situation.

Although bone lengthening using the Ilizarov technique has been used in the correction of leg shortening and as an alternative to amputation, many studies have recommended that this method should be performed in limb deficiencies of less than 5 cm and when the patient has a relatively normal plantigrade foot. It should be noted that this operation has a higher risk and may require a number of operations^(9,11,17). Although many studies had reported good bone lengthening outcomes⁽⁶⁾, some studies such as Dutoit et al⁽¹⁰⁾ reported that 22 out of 26 of the fibular hemimelia patients who had the Ilizarov bone lengthening procedure experienced some problems. For example, 20 had problems adapting to wearing shoes and walking. Miller et al and McCarthy et al reported no problems with this technique^(5,18). Jawish and Carliz's study reported that 60% of fibular hemimelia bone lengthening patients required a foot correction operation⁽⁴⁾.

Even extreme tibia shortening cases can be

managed using this technique. In the present study, the authors lengthened the affected tibia up to 14 cm in a 2-year-old girl; twice at the same tibia, with a lengthening index of 1 at first lengthening and 0.7 at the second lengthening. Our conclusion is that the Ilizarov technique is a successful method for bone-lengthening and correction in the treatment for fibular hemimelia. The authors also recommend keeping amputation as the last option. The Ilizarov method is a good option to consider for the treatment of fibular hemimelia, even when confronting associated deformities and/or limb shortening of more than 10 centimeters. We believe bone-lengthening procedures can be done in patients who have walking difficulty without waiting for bone maturity. All of the patients were satisfied with the treatment and all have good leg and foot function. The foot function in the present study was very positive, with a mean FADI score of 99.16. No patients reported experiencing pain at final follow-up.

Treatment of fibular hemimelia with this limb-saving procedure is complicated. Reconstruction in the cases described here was difficult, lengthy and required experience. Amputation is an easy and effective solution. The authors were not able to effectively compare amputation to the reconstruction results reported in the present study due to the different parameters used in evaluation. The authors believe the method of treating fibular hemimelia described in this series might be a welcomed alternative in instances where amputation is refused, as measureable functional improvement can be expected.

Acknowledgement

The authors would like to thank Mr. Tanatip Srisuchinthara for his assistance in statistical analysis and staff of the Orthopaedic Research Unit is also gratefully acknowledged.

Potential conflicts of interest

None.

References

1. Stevens PM, Arms D. Postaxial hypoplasia of the lower extremity. *J Pediatr Orthop* 2000; 20: 166-72.
2. Khurana DK, Bhargava SP. Congenital absence of fibulae, with equinovarus deformity—a case report. *Acta Orthop Scand* 1997; 68: 307-8.
3. Achterman C, Kalamchi A. Congenital deficiency of the fibula. *J Bone Joint Surg Br* 1979; 61-B: 133-7.

4. Jawish R, Carlioz H. Conservation of the foot in the treatment of longitudinal external ectromelia. *Rev Chir Orthop Reparatrice Appar Mot* 1991; 77: 115-20.
5. Miller LS, Bell DF. Management of congenital fibular deficiency by Ilizarov technique. *J Pediatr Orthop* 1992; 12: 651-7.
6. Catagni MA. Management of fibular hemimelia using the Ilizarov method. *Instr Course Lect* 1992; 41: 431-4.
7. Martin RL, Burdett RG, Irrgang JJ. Development of the foot and ankle disability index (FADI). *JOSPT* 1999; 29: A32-33.
8. Epps CH Jr, Schneider PL. Treatment of hemimelias of the lower extremity. Long-term results. *J Bone Joint Surg Am* 1989; 71: 273-7.
9. Choi IH, Kumar SJ, Bowen JR. Amputation or limb-lengthening for partial or total absence of the fibula. *J Bone Joint Surg Am* 1990; 72: 1391-9.
10. Dutoit M, Rigault P, Padovani JP, Finidori G, Touzet P, Durand Y. The fate of children undergoing bone lengthening in congenital hypoplasia of the legs. *Rev Chir Orthop Reparatrice Appar Mot* 1990; 76: 1-7.
11. Oppenheim WL. Fibular deficiency and the indications for Syme's amputation. *Prosthet Orthot Int* 1991; 15: 131-6.
12. Herring JA. Symes amputation for fibular hemimelia: a second look in the Ilizarov era. *Instr Course Lect* 1992; 41: 435-6.
13. Westin GW, Sakai DN, Wood WL. Congenital longitudinal deficiency of the fibula: follow-up of treatment by Syme amputation. *J Bone Joint Surg Am* 1976; 58: 492-6.
14. Fergusson CM, Morrison JD, Kenwright J. Leg-length inequality in children treated by Syme's amputation. *J Bone Joint Surg Br* 1987; 69: 433-6.
15. Letts M, Vincent N. Congenital longitudinal deficiency of the fibula (fibular hemimelia). Parental refusal of amputation. *Clin Orthop Relat Res* 1993; 160-6.
16. Naudie D, Hamdy RC, Fassier F, Morin B, Duhaime M. Management of fibular hemimelia: amputation or limb lengthening. *J Bone Joint Surg Br* 1997; 79: 58-65.
17. Hood RW, Riseborough EJ. Lengthening of the lower extremity by the Wagner method. A review of the Boston Children's Hospital Experience. *J Bone Joint Surg Am* 1981; 63: 1122-31.
18. McCarthy JJ, Glancy GL, Chnag FM, Eilert RE. Fibular hemimelia: comparison of outcome measurements after amputation and lengthening. *J Bone Joint Surg Am* 2000; 82-A: 1732-5.

การรักษาโรคไม่มีกระดูกน่องโดยใช้อุปกรณ์อิลีซารอฟ

ปรางทอง อุ่นประเสริฐ, กมลพร แก้วพรสวรรค์, จตุพร โชติกวณิช, พีระจิตร เอี่ยมโสภณา

ภูมิหลัง: โรคกระดูกน่องสร้างไม่สมบูรณ์เป็นภาวะพิการในการเจริญเติบโตแต่กำเนิดมีกระดูกน่อง การขาดหายบางส่วนหรือขาดหายทั้งหมดที่พบบ่อย การรักษาที่ผ่านมามีทั้งการตัดขาที่ผิดปกติหรือความพยายามที่จะเก็บขาของผู้ป่วย การวิจัยนี้มุ่งเพื่อประเมินผลการรักษาผู้ป่วย ภาวะกระดูกน่องสร้างไม่สมบูรณ์ที่มีขาสั้นยาวไม่เท่ากันและมีการผิดรูปโดยวิธี อิลีซารอฟ โดยวิเคราะห์จากผลแทรกซ้อน การใช้งานของข้อเท้ารวมถึงความพึงพอใจของผู้ป่วยในผลการรักษา

วัสดุและวิธีการ: ผู้มีพันธุกรรมผู้ป่วยที่วินิจฉัยเป็นโรคกระดูกน่องสร้างไม่สมบูรณ์ 9 ราย ที่ได้รับการรักษา โดยการยึดกระดูกน่องและรักษาภาวะเท้าข้อเท้าผิดรูปโดยวิธีการใส่อุปกรณ์อิลีซารอฟ โดยการเก็บข้อมูลความผิดรูป ก่อนการรักษา และการติดตามผลการรักษาแล้วสุดมาวิเคราะห์การใช้งานภาวะขาสั้นยาวไม่เท่ากันที่ได้รับการยึด โดยอุปกรณ์อิลีซารอฟ ภาวะแทรกซ้อน ความพึงพอใจ และลักษณะความผิดปกติของขาที่เหลืออยู่หลังรักษา

ผลการรักษา: ผู้ป่วยได้ถูกแบ่งกลุ่มโดยวิธีของ Achterman และ Kalamchi พบว่ามีความผิดรูปชนิด IA 4 ราย ความผิดรูปชนิด IB 3 ราย และความผิดรูปชนิด II 2 ราย ในชนิด IA ผู้ป่วยมีอายุเฉลี่ย 7.75 ปี และมีค่าเฉลี่ยของขาสั้นกว่าข้างปกติ 3.25 เซนติเมตรในชนิด IB ผู้ป่วยมีอายุเฉลี่ย 4.3 ปี และมีค่าเฉลี่ยของขาสั้นกว่าข้างปกติ 5.83 เซนติเมตร ในชนิด II ผู้ป่วยมีอายุเฉลี่ย 5 ปี และมีค่าเฉลี่ยของขาสั้นกว่าข้างปกติ 5.5 เซนติเมตร ค่าเฉลี่ยการยึดกระดูก 7.52 เซนติเมตร ดัชนีการยึดกระดูกอยู่ที่ 1.28 เดือนต่อเซนติเมตร ผู้ป่วย มีความผิดปกติของความยาวขาหลังรักษาเฉลี่ย 0.94 เซนติเมตร ข้อเท้าเหลือการเขย่งแต่เท้าไม่บิดผิดรูปในส่วนเท้า ส่วนหน้า มีภาวะข้อเท้ายึดติดในผู้ป่วยซึ่งมีความผิดรูปชนิด II แต่ผู้ป่วยทั้งหมดสามารถเดินได้อย่างดีโดยไม่ต้องมีอุปกรณ์ช่วยเดินและปราศจากอาการเจ็บหลังรับการรักษา ผู้ป่วยทั้งหมดมีความพึงพอใจในการรักษาโดยวิธีนี้

สรุป: การรักษาผู้ป่วยโดยอุปกรณ์อิลีซารอฟสามารถใช้ในผู้ป่วยทุกชนิดของโรคกระดูกน่องสร้างไม่สมบูรณ์ ให้ผู้ป่วยได้รับความพึงพอใจ และเป็นทางเลือกนอกเหนือจากการตัดขาในผู้ป่วยที่มีกระดูกน่องสั้นมาก ๆ
