

Case Report

Spontaneous Rupture of an Adrenal Adenoma Managed by Laparoscopic Adrenalectomy: A Case Report

Ronnarat Suvikapakornkul MD, MSc*

* Division of Breast and Endocrine Surgery, Department of Surgery, Faculty of Medicine, Ramathibodi Hospital, Mahidol University, Bangkok, Thailand

Spontaneous rupture of an adrenal adenoma is a rare condition. This case report describes spontaneous rupture of the right adrenal adenoma in the women that presented with acute abdominal pain.

Early suspicion of this condition, effective imaging, and prompt treatment should save the patient. Urgency laparoscopic adrenalectomy is a safe and feasible option.

Keywords: Spontaneous rupture, Adrenal adenoma, Laparoscopic adrenalectomy

J Med Assoc Thai 2014; 97 (1): 123-5

Full text. e-Journal: <http://www.jmatonline.com>

Spontaneous rupture of an adrenal adenoma is a rare condition. The patient presents the signs and symptoms as acute sudden abdominal pain. In the early report⁽¹⁻⁵⁾, the patients with rupture adrenal gland were treated by open adrenalectomy. This case report introduced the feasibility of laparoscopic adrenalectomy in urgent situation and the difficulty caused by hematoma around the gland.

Case Report

A 35-year-old Caucasian woman presented with right-sided upper abdominal pain radiating intensely to the back. The symptoms had started about four hours earlier, while she was sleeping. She vomited approximately 10 times, thus all the food consumed. Her medical history revealed no previous major illness or trauma in the preceding days. She had no abnormal symptom and sign of abnormal adrenal hormone production. She had history of appendectomy one year earlier.

On the day of admission, she was agitated due to severe pain. Physical examination demonstrated mild pale, T 36.3 C, BP 198/130 mmHg, PR 120/min and RR 25/min. Fine crepitation was noted at right lower chest wall. Mild abdominal distention and tenderness at the right subcostal area without rebound tenderness were found on the abdominal examination.

Correspondence to:

Suvikapakornkul R, Division of Breast and Endocrine Surgery, Department of Surgery, Faculty of Medicine, Ramathibodi Hospital, Mahidol University, Bangkok 10400, Thailand.

Phone: 0-2644-9042

E-mail: napaphat.pro@mahidol.ac.th

The following laboratory parameters were noted: hemoglobin 10.9 g/dL, WBC $10.6 \times 10^3/\text{mm}^3$ (N 93%, L 4.1%, and M 2.9%), platelet count $160 \times 10^3/\text{mm}^3$, sodium 137 mmol/L, potassium 3.92 mmol/L, chloride 106 mmol/L, bicarbonate 25 mmol/L and cortisol 28.8 mcg/dL Computed tomography (CT) scan showed a 4.0x3.4x4.5 cm rim enhanced heterogeneous hypo-hyperdense lesion at the right suprarenal region, partly abutting to the right adrenal gland. There was a non-enhancing fluid-filled density (25-30 HU) within the right paranephric space and right retroperitoneal space. Minimal fat reticulation at the right retroperitoneal area was detected. Apart

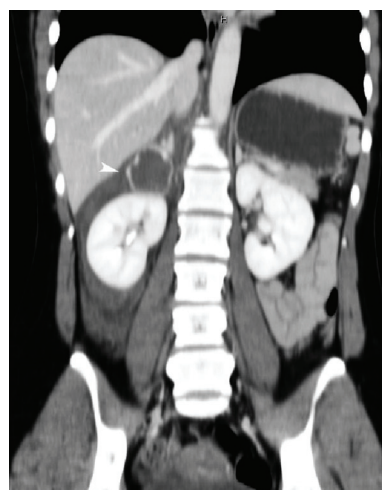


Fig. 1 The CT scan abdomen shows a rim enhanced heterogeneous hypo-hyperdense lesion at the right suprarenal region (arrowhead).

from this, there was no radiological evidence of any other pathology. Retroperitoneal rupture of a right adrenal tumor was suggested.

The patient still felt intense pain even after strong analgesia was given. The patient was informed the advantages of laparoscopic adrenalectomy such as less post-operative pain, faster recovery, and shorter hospital stay than open surgery, but the operative time might be longer and it should be difficult situation because there was no prior report about laparoscopic adrenalectomy in the ruptured adenoma. Urgent right laparoscopic adrenalectomy was performed. The patient was laid in the left lateral decubitus position. Four ports (12 mm, 5 mm, 5 mm, and 5 mm) were placed in the right subcostal area. The right lobe of the liver was retracted by a fan retractor. A large retroperitoneal hematoma, surrounding the periadrenal and perirenal fat, was intraoperatively encountered. The tissue around the adrenal gland was dissected with the Harmonic scalpel, then the adrenal gland was identified. A ruptured 5-cm mixed cystic and solid tumor of the right adrenal gland was found. The right adrenal vein was identified along the line of the inferior vena cava using blunt dissection by a suction tip, and then the vein was identified, doubly clipped, and cut. The gland was totally dissected from the surrounding fat with the Harmonic scalpel. The procedure took 300 minutes and blood loss from hematoma was approximately 500 mL. The patient's recovery was unremarkable. She was discharged from the hospital on the seventh day post-operation without sign of abnormal adrenal hormone presentation. Final pathologic examination revealed a 4 cm cortical

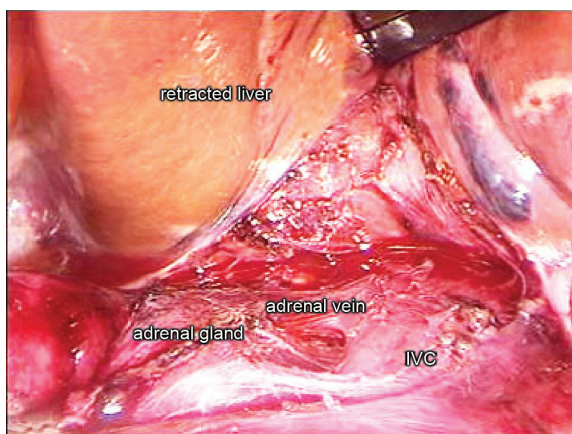


Fig. 2 Laparoscopic view shows right adrenal gland, adrenal vein, inferior vena cava (IVC) and hematoma at suprarenal region.

adenoma with hemorrhage and no characteristics of malignancy.

Discussion

Rupture of an adrenal tumor is rare and has been reported for pheochromocytoma⁽¹⁾, adrenocortical carcinoma^(2,3), myelolipoma⁽⁴⁾, metastatic carcinoma⁽⁵⁾, and adenoma⁽⁶⁾. This case report describes the rupture of a 4-cm benign adenoma. The patient had no sign of abnormal adrenal hormonal production. She had not known that she had an adrenal tumor prior to the rupture episode.

Symptom of rupture of an adrenal tumor includes sudden epigastric pain, which is the most frequent complaint. In some patients, the pain is located on the effected side. Frequently, the pain radiates to other parts of the upper abdomen, flank, and back. The pain is usually intense and aggravated by motion. Localized hyperesthesia, peritoneal irritation, and occasionally diaphragmatic irritation might be found. The patients may develop pallor, hypotension, and finally shock⁽⁷⁾.

A CT scan, magnetic resonance imaging (MRI), or ultrasonography can be used for diagnosis of adrenal hemorrhage⁽⁸⁾. In this case, a CT scan was selected to establish the diagnosis. The diagnosis of adrenal hemorrhage based on a CT scan is challenging because many conditions might mimic its finding in the imaging. The important conditions to be considered in differential diagnosis are ruptured aortic aneurysm, retroperitoneal organ hemorrhage, renal vein thrombosis, splenic rupture, and abdominal abscess^(6,8). Typically, CT findings show an infiltrating hyper-attenuating mass, which suggests acute hematoma with distortion of the inverted v-shaped adrenal gland. Additional findings may include peri-adrenal fat stranding with thickening of the adjacent diaphragmatic crura and an adrenal mass might be identified⁽⁸⁾. If the CT result is in doubt, selective angiography is possible to provide an exact diagnosis⁽⁶⁾.

The adrenalectomy in this case is clearly indicated because of acute bleeding. In general, the benefits of laparoscopic adrenalectomy are less post-operative pain and faster recovery and shorter hospital stay^(9,10) but for the ruptured adrenal adenoma, it might be more difficult than open surgery^(3,4). Urgent laparoscopic adrenalectomy was undertaken by the surgeon who is highly experienced in this procedure. The difficulty during the procedure was caused by the hematoma and the problem of identifying important

structures. Use of the suction tip for blunt dissection, irrigation, and intermittent suction were helpful to identify the gland.

In summary, early suspicion of the ruptured adrenal adenoma, correct diagnosis with effective imaging, and prompt treatment should improve survival. Laparoscopic adrenalectomy is safe and feasible to perform.

What is already known on this topic?

Until now, there is no report that laparoscopic adrenalectomy is used to manage the spontaneous rupture of adrenal adenoma in urgency situation.

What this study adds?

This is the first case report of laparoscopic adrenalectomy used to manage the spontaneous rupture of adrenal adenoma.

Potential conflicts of interest

None.

References

1. Kobayashi T, Iwai A, Takahashi R, Ide Y, Nishizawa K, Mitsumori K. Spontaneous rupture of adrenal pheochromocytoma: review and analysis of prognostic factors. *J Surg Oncol* 2005; 90: 31-5.
2. Leung LY, Leung WY, Chan KF, Fan TW, Chung KW, Chan CH. Ruptured adrenocortical carcinoma as a cause of paediatric acute abdomen. *Pediatr Surg Int* 2002; 18: 730-2.
3. Suyama K, Beppu T, Isiko T, Sugiyama S, Matsumoto K, Doi K, et al. Spontaneous rupture of adrenocortical carcinoma. *Am J Surg* 2007; 194: 77-8.
4. Amano T, Takemae K, Niikura S, Kouno M, Amano M. Retroperitoneal hemorrhage due to spontaneous rupture of adrenal myelolipoma. *Int J Urol* 1999; 6: 585-8.
5. Yang PW, Wang WY, Yang CH, Chou CC, Yen DH, Chou J. Treatment of massive retroperitoneal hemorrhage from adrenal metastasis of hepatoma. *J Chin Med Assoc* 2007; 70: 126-31.
6. Cerwenka H, Karaic R, Pfeifer J, Wolf G. Laceration of a benign adrenal adenoma mimicking a splenic rupture. *Langenbecks Arch Surg* 1998; 383: 249-51.
7. Berte SJ. Spontaneous adrenal hemorrhage in the adult; literature review and report of two cases. *Ann Intern Med* 1953; 38: 28-37.
8. Arora S, Vargo S, Lupetin AR. Computed tomography appearance of spontaneous adrenal hemorrhage in a pheochromocytoma. *Clin Imaging* 2009; 33: 314-7.
9. MacGillivray DC, Shichman SJ, Ferrer FA, Malchoff CD. A comparison of open vs laparoscopic adrenalectomy. *Surg Endosc* 1996; 10: 987-90.
10. Chotirosnramit N, Angkoolpakdeekul T, Kongdan Y, Suvikapakornkul R, Leelaudomlipi S. A laparoscopic versus open adrenalectomy in Ramathibodi Hospital. *J Med Assoc Thai* 2007; 90: 2638-43.

รายงานผู้ป่วยการรักษาภาวะแตกเองของเนื้องอกต่อมหมวกไตชนิด *adenoma* โดยการผ่าตัดด้วยกล้อง

รณรัฐ สุวิกะปกรณกุล

การแตกเองของเนื้องอกต่อมหมวกไตชนิด *adenoma* เป็นภาวะที่พบน้อย รายงานผู้ป่วยฉบับนี้รายงานผู้ป่วยหญิงที่มาด้วยอาการปวดท้องฉับพลัน ตรวจพบว่ามีกรแตกเองของเนื้องอกชนิด *adenoma* ของต่อมหมวกไตด้านขวา การนี้ถึงภาวะนี้ในผู้ป่วยที่มาด้วยอาการปวดท้องฉับพลัน การถ่ายภาพรังสีที่มีประสิทธิภาพและการรักษาที่รวดเร็วจะสามารถรักษาชีวิตผู้ป่วยไว้ได้ การผ่าตัดต่อมหมวกไตผ่านกล้องเป็นทางเลือกของการรักษาที่ทำได้ด้วยความปลอดภัย
