

# Cardiac CT Angiography: Comprehensive Assessment of Patient Suspected Coronary Artery Disease

Sarinya Puwanant, MD\*,  
Sutipong Jongjirasiri, MD\*\*, Pairoj Rerkpattanapipat, MD, FACP, FACC, FASE\*,\*\*\*,\*\*\*\*

\* Cardiovascular Imaging Section, Bangkok Heart Hospital

\*\* Department of Radiology, Ramathibodi Hospital, Mahidol University

\*\*\* Department of Internal Medicine, Faculty of Medicine, Ramathibodi Hospital, Mahidol University

\*\*\*\* Department of Radiology, Faculty of Medicine, Chulalongkorn University

---

Coronary artery disease is the leading cause of mortality and morbidity worldwide. Although coronary angiography is currently a gold standard for diagnosis of coronary artery disease, some patients are of concern regarding small but not negligible risk of complications and discomfort of the procedure. In recent years, cardiac computerized tomographic angiography (CTA) is an attractive non-invasive modality for evaluation of chest pain in patients suspected to have coronary artery disease. The authors report a 61 year-old-man with a history of hypertension and hypercholesterolemia who presented with exertional angina pectoris for 3 weeks. Cardiac CTA was performed and revealed a severely stenotic lesion at the proximal left anterior descending coronary artery (LAD) with left ventricular ejection fraction of 53% and hypokinesia of anteroseptal and apical wall. The patient then was planned and underwent percutaneous coronary interventional procedure. This case highlights the utility of comprehensive information from cardiac CTA as a modality for coronary interventional procedure planning.

**Keywords:** Coronary disease, Angina pectoris, Spiral computed tomography, Angioplasty, Myocardial contraction

*J Med Assoc Thai* 2005; 88(6): 833-6

**Full text. e-Journal:** <http://www.medassocthai.org/journal>

---

## Case Report

A 61 year-old-man with a known history of hypertension and hypercholesterolemia presented with exertional angina pectoris for 3 weeks. Physical examination was unremarkable. Electrocardiogram showed sinus rhythm with biphasic T wave inversion in anterior precordial leads. To avoid an invasive procedure, it was decided to send the patient for computerized tomographic angiography (CTA). This was done on a 16-slice multi-detector row spiral CT scanner, MX 8000 IDT, Philips Medical System, USA. It revealed a severely stenotic lesion at the proximal left anterior descending coronary artery just below the origin of the first diagonal branch (Fig. 1). The LV ejection fraction was calculated to be 53% by

Simpson's method. The mid anteroseptum, anterior wall and apex were severely hypokinetic to akinetic (Fig. 2). Drug-eluting stent was placed at the stenotic site (Fig. 3).

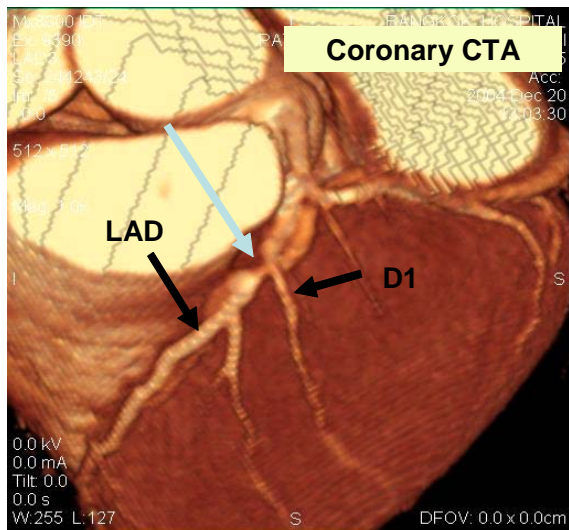
## Discussion

This case highlights that cardiac CTA information of global and regional LV function as well as coronary luminal stenosis provides comprehensive assessment in a patient suspected coronary artery disease which is sufficient for planning percutaneous coronary intervention (PCI) procedure.

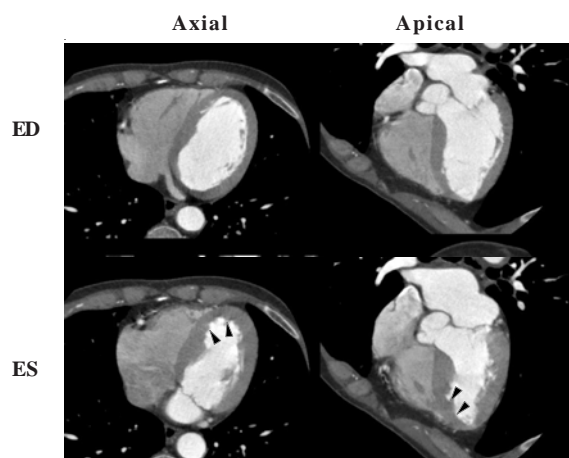
Conventional noninvasive tests to assess for myocardial ischemia including exercise electrocardiography, stress echocardiography, and stress nuclear scintigraphy have some limitations. Exercise electrocardiography has been widely performed and provides data on functional capacity; however, the overall accuracy for detecting significant coronary arterial

---

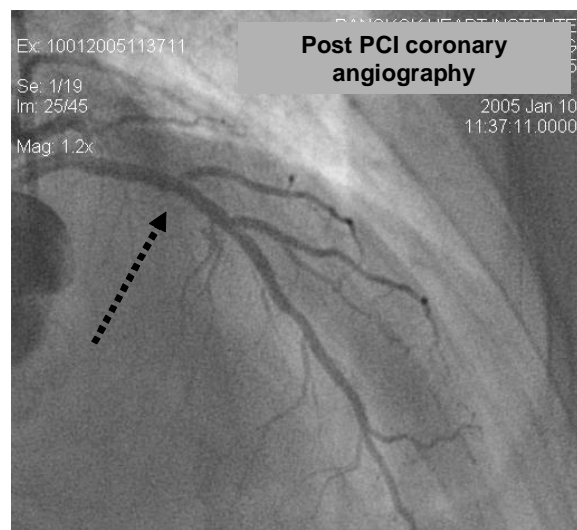
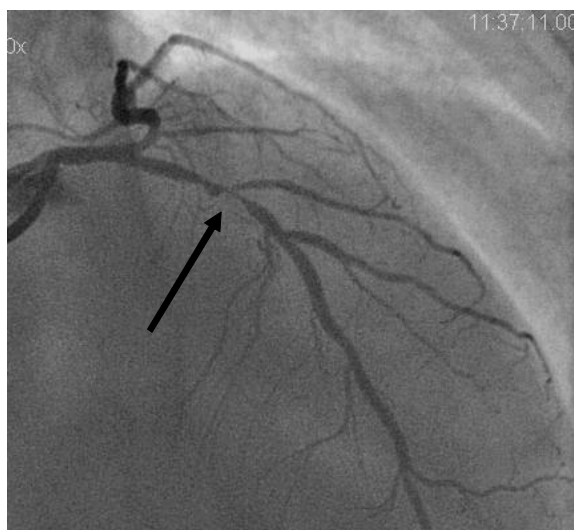
Correspondence to : Rerkpattanapipat P, Bangkok Heart Hospital, 2<sup>nd</sup> Floor, Building C, 2 Soi Soonvijai 7, New Petchburi Rd, Bangkok 10320, Thailand. Phone: 0-2310-3030, Fax: 0-2310-3088, E-mail: [aemc@hotmail.com](mailto:aemc@hotmail.com)



**Fig. 1** CTA image demonstrates severe stenosis (arrow) at the proximal left anterior descending artery (LAD) at the level of the origin of the first diagonal branch (D1)



**Fig. 2** Cardiac CTA images of the left ventricle display in axial (left column) and apical views (right column). The upper row and lower row demonstrate end diastole (ED) and end systole (ES), respectively. There are abnormal wall motion abnormalities at the septum and apex (arrow heads)



**Fig. 3** Coronary angiography of the left coronary arteries demonstrates severe stenosis (black arrow) at the proximal left anterior descending artery (Left Panel) which has no residual stenosis (dotted arrow) after percutaneous coronary intervention (PCI) (Right Panel)

luminal narrowing is moderate which may be the results of unachievable predicted heart response for age, abnormal baseline electrocardiography, and hypertensive response, etc<sup>(1)</sup>. Stress echocardiography has improved the diagnostic accuracy for stress testing in the majority of patients. Unfortunately, 15-20% of patients have inadequate acoustic windows which limit complete assessment of regional wall motion<sup>(1-3)</sup>. For nuclear scintigraphy, it can provide information

on perfusion and function; however, it is a time consuming procedure and requires technical expertise for nuclear material handling and post-processing<sup>(1,4)</sup>. Therefore, it is important to have an alternative and accurate noninvasive technique to assess coronary artery disease (CAD).

Cardiac CTA is an attractive modality because it can acquire complete data set in one short breath-holding. The information on LV function and coro-

nary artery can be analyzed with post-processing software. The accuracy of detecting coronary arterial luminal narrowing has previously described<sup>(5-7)</sup>. Information in global and regional LV function helps in determining the presence of CAD and assessing the associated findings with CAD, such as LV thrombus. Logically, if the patient has significant coronary stenosis and undergoes PCI, the authors can omit left ventriculography which will cause less radiation and contrast exposure to the patient. In addition, from the authors' experience, noncardiac causes of chest pain have been detected in cardiac CT exam during the assessment of chest pain patients. Those etiologies include pulmonary embolism, aortic dissection, and lung mass, etc.

It should also be realized that there are some limitations which impair image quality of cardiac CTA. Those include respiratory artifacts, motion artifacts, cardiac arrhythmia, rapid heart rate during scanning, and artifacts from dense coronary calcification<sup>(8)</sup>. In future development including 64-slice multi-detector row spiral CT scanner, artifacts may be reduced and the excellent spatial and temporal resolutions will allow the assessment of small branches and characterization of coronary arterial plaques<sup>(9,10)</sup> which then expand the role in preventive cardiology.

### Conclusion

The evolution of cardiac CT has changed the world of cardiac imaging. For assessment of a patient with chest pain, clinicians now have a powerful tool to help to determine various causes of chest pain and provide comprehensive assessment in patient suspected CAD. This information is adequate for planning PCI which may reduce the role of diagnostic coronary angiography and it is possible that the cardiac catheterization laboratory will be utilized mainly for interventional procedure. The availability of the scanners in the medical practices will increase the utility of this technology significantly in the near future.

### Acknowledgement

Partial support from Philips Medical System (Thailand).

### References

1. Lee TH, Boucher CA. Noninvasive tests in patients with stable coronary artery disease. *N Engl J Med* 2001; 344:1840-5.

2. Cheitlin MD, Armstrong WF, Aurigemma GP, Beller GA, Bierman FZ, Davis JL, et al. ACC/AHA/ASE 2003 guideline update for the clinical application of echocardiography: summary article: a report of the American College of Cardiology/American Heart Association Task Force on Practice Guidelines (ACC/AHA/ASE Committee to Update the 1997 Guidelines for the Clinical Application of Echocardiography). *Circulation* 2003; 108: 1146-62.
3. Chuah SC, Pellikka PA, Roger VL, McCully RB, Seward JB. Role of dobutamine stress echocardiography in predicting outcome in 860 patients with known or suspected coronary artery disease. *Circulation* 1998; 97: 1474-80.
4. Klocke FJ, Baird MG, Lorell BH, Bateman TM, Messer JV, Berman DS, et al. ACC/AHA/ASNC Guidelines for the clinical use of cardiac radionuclide imaging-executive summary: a report of the American College of Cardiology/American Heart Association Task Force on practice guidelines (ACC/AHA/ASNC Committee to revise the 1995 guidelines for the clinical use of cardiac radionuclide imaging). *Circulation* 2003; 108: 1404-18.
5. Nieman K, Cadernartiri F, Lemos PA, Raaijmakers R, Pattynama PM, de Feyter PJ. Reliable noninvasive coronary angiography with fast submillimeter multislice spiral computed tomography. *Circulation* 2002; 106: 2051-4.
6. Achenbach S, Giesler T, Ropers D, Ulzheimer S, Derlien H, Schulte C, et al. Detection of coronary artery stenoses by contrast-enhanced, retrospectively electrocardiographically-gated, multislice spiral computed tomography. *Circulation* 2001; 103: 2535-8.
7. Ropers D, Baum U, Pohle K, Anders K, Ulzheimer S, Ohnesorge B, et al. Detection of coronary artery stenoses with thin-slice multi-detector row spiral computed tomography and multiplanar reconstruction. *Circulation* 2003; 107: 664-6.
8. Schoepf UJ, Becker CR, Hofmann LK, Yucel EK. Multidetector-row CT of the heart. *Radiol Clin North Am* 2003; 41: 491-505.
9. Leber AW, Knez A, White CW, Becker A, Ziegler VF, Muehling O, et al. Composition of coronary atherosclerotic plaques in patients with acute myocardial infarction and stable angina pectoris determined by contrast-enhanced multislice computed tomography. *Am J Cardiol* 2003; 91: 714-8.
10. Schroeder S, Kopp AF, Baumbach A, Christoph M, Axel K, Georg C, et al. Noninvasive detection and evaluation of atherosclerotic coronary plaques with multislice computed tomography. *J Am Coll Cardiol* 2001; 37: 1430-5.

---

## การตรวจเอกซเรย์คอมพิวเตอร์หัวใจและหลอดเลือดหัวใจ: แนวทางเลือกใหม่ในการวินิจฉัยและวางแผนการรักษาผู้ป่วยที่สงสัยโรคหลอดเลือดหัวใจตีบ

ศริญญา ภูวนันท์, สุทธิพงษ์ จงจิระศิริ, ไพโรจน์ ฤกษ์พัฒนาพิพัฒน์

โรคหลอดเลือดหัวใจตีบเป็นโรคที่พบได้บ่อยและเป็นสาเหตุของอัตราการเสียชีวิตอันดับต้นๆของประเทศไทย ในปัจจุบันความก้าวหน้าทางเทคโนโลยีสามารถพัฒนาเครื่องมือช่วยในการวินิจฉัยโรคหลอดเลือดหัวใจตีบซึ่งเรียกว่า เอกซเรย์คอมพิวเตอร์หัวใจและหลอดเลือด หรือ Cardiac computerized tomographic angiography (CTA) ซึ่งมีความแม่นยำในการวินิจฉัยสูง ใช้เวลาในการตรวจสั้นรวดเร็ว ไม่ต้องเสี่ยงต่อผลแทรกซ้อนจากการสวนหัวใจ และให้ข้อมูลครบถ้วนทั้งลักษณะของหลอดเลือดหัวใจและการทำงานของผนังกล้ามเนื้อหัวใจ ซึ่งมีประโยชน์ในการใช้วางแผนรักษาผู้ป่วย

ผู้เขียนนำเสนอกับผู้ป่วยตัวอย่างอายุ 61 ปี มีประวัติความดันโลหิตสูงและไขมันในเลือดสูง มารับการรักษาด้วยอาการเจ็บหน้าอกขณะออกกำลังกาย เป็นเวลา 3 สัปดาห์ ผู้ป่วยได้รับการตรวจ CTA ซึ่งผลการตรวจพบว่ามีหลอดเลือดหัวใจตีบตำแหน่งหลอดเลือดเส้นซ้ายซึ่งเลี้ยงกล้ามเนื้อหัวใจส่วนหน้า หรือที่เรียกว่า left anterior descending coronary artery (LAD) และ พบว่าผนังของกล้ามเนื้อหัวใจส่วนหน้า (anterior wall) และส่วนยอด (apex) บีบตัวน้อยกว่าปกติ โดยคำนวณสมรรถภาพการบีบตัวของหัวใจคิดเป็นร้อยละ 53 จากข้อมูลของ CTA ผู้ป่วยได้รับการรักษาต่อโดยการขยายหลอดเลือดหัวใจตำแหน่งหลอดเลือดเส้นซ้ายซึ่งเลี้ยงกล้ามเนื้อหัวใจส่วนหน้า หรือ LAD เป็นผลสำเร็จ

รายงานผู้ป่วยฉบับนี้ต้องการแสดงให้เห็นว่า CTA เป็นเครื่องมือใช้ตรวจวินิจฉัยผู้ป่วยที่สงสัยโรคหลอดเลือดหัวใจตีบ ซึ่งมีความแม่นยำสูงและสามารถนำมาใช้ในการเตรียมการรักษาต่อด้วยการขยายหลอดเลือดหัวใจ

---