

Case Report

Female Genital Tract Tumors and Gastrointestinal Lesions in the Peutz-Jeghers Syndrome

Charuwan Tantipalakov MD*, Surapan Khunamornpong MD**,
Nirush Lertprasertsuke MD**, Theera Tongsong MD*

* Department of Obstetrics and Gynecology, Chiang Mai University, Chiang Mai, Thailand

** Department of Pathology, Chiang Mai University, Chiang Mai, Thailand

Background: Peutz-Jeghers Syndrome (PJS) is a rare genetic disorder characterized by mucocutaneous melanin deposition, and intestinal hamartomatous polyps, with an increased risk of breast, gastrointestinal, and female genital tract cancers.

Case Report: Multiple genital tract neoplasms in a 52-year-old northern Thai woman with PJS are described. The patient presented with abdominal distention. A pelvic ultrasound scan showed a left adnexal mass, diagnosed as mucinous cyst. An ovarian microscopic cystadenoma was diagnosed together with a minimal deviation mucinous adenocarcinoma (MDA) of the uterine cervix and mucinous metaplasia in tubal mucosa and endometrium. Pathological findings warranted a search for evidence of PJS. Typical pigmentation at the hard palate and colonoscopic finding of hamartomatous polyps established the diagnosis of PJS. At four-year follow-up, the patient still showed no evidence of tumor recurrence.

Conclusion: A case of PJS complicated by multiple and contemporaneous genital tract tumors with rare histological findings is presented. The presented case suggests MDA and mucinous metaplasia warrant a search for PJS.

Keywords: Peutz-Jeghers Syndrome, Female genital tract tumor, Minimal deviation adenocarcinoma

J Med Assoc Thai 2009; 92 (12): 1686-90

Full text. e-Journal: <http://www.mat.or.th/journal>

Peutz-Jeghers Syndrome (PJS) is a rare genetic disorder. It is a complex hereditary polyposis distinguished by hamartomas, primarily of the gastrointestinal tract, with characteristic mucocutaneous macules, and with a susceptibility to multiple cancers^(1,2). The initial report by Peutz described seven Dutch patients with intestinal polyposis and pigmented spots of the mouth, hands, and feet. However, definitive characteristics of the syndrome were well accepted after a detailed description reported by Jeghers et al in 1949⁽³⁾ and finally by Bruwer et al in 1954⁽⁴⁾. The incidence is quoted as 1 in 120,000 live births⁽¹⁾. Patients with PJS have increased risks of breast, gastrointestinal, and female genital tract cancers. Although each of these tumor types has been reported to occur in this syndrome, the case presented here appeared to be a rare case in which the syndrome

was complicated by multiple and contemporaneous genital tract tumors, and rare histological findings.

Case Report

A 52-year-old northern Thai woman, parity 1, presented at the authors' gynecologic outpatient department with a complaint of abdominal distension for one month. She had been in menopause for two years at the time of admission. Physical examination revealed a pelvic mass of 10 centimeters in diameter. Transabdominal ultrasound showed a huge cystic mass with several daughter cysts at the left adnexa, some small solid parts without papillary projections from the septae and inner wall. Additionally, marked ascites was also noted. Tumor markers before treatment were CEA: 2.7, CA125:18.9 and CA19-9: 21.5. Pap smear showed negative for malignancy.

The patient underwent surgery with a pre-operative diagnosis of ovarian cancer. The operative findings included mucinous ascites of approximately

Correspondence to: Tantipalakov C, Department of Obstetrics and Gynecology, Chiang Mai University, Chiang Mai 50200, Thailand.

2000 ml. The left ovarian mass was as follows: 20 x 15 x 10 cm in size, multiloculated, mucinous content, but no papillary projection. It had an old 0.5 cm-diameter rupture at the anterior wall without adhesion. The right ovary was found to be normal. There was a 1 cm cystic lesion at the left lateral side of the cervix. Other intra-abdominal structures appeared to be unremarkable. Pelvic and paraaortic nodes were not palpable. A frozen section of the mass revealed benign mucinous cystadenoma.

Total abdominal hysterectomy with bilateral salpingo-oophorectomy and appendectomy were performed and peritoneal fluid was also collected for cytology. The pathologic examination of the uterus detected minimal deviation mucinous adenocarcinoma (MDA) (Fig. 1A), arising at the upper endocervix with an extension of the tumor to the entire left lateral wall but no lymphovascular space invasion and negative ectocervical margin. The left lateral wall margin was less than 1 mm from the neoplastic epithelium. Mucinous metaplasia was noted on the surface of the endometrium (Fig. 1B), as well as tubal epithelium of the right tube (Fig. 1C). The left ovary showed mucinous cystadenoma without atypical epithelial proliferation (Fig. 1D). The right ovary and the left tube were unremarkable. Additionally, the omentum showed mesothelial proliferation, and the peritoneal cytology contained benign-appearing mucinous epithelial cells. Subsequent complete physical examination revealed hyperpigmentation at the hard palate. Colonoscopy showed multiple staghorn polyps and elongated polyps of varying sizes at the left half of the colon and rectum with normal intervening mucosa. The microscopic findings of the polyps confirmed typical hamartomatous polyps of PJS (Fig. 2).

At four-year follow-up, the presented patient was still healthy, with no evidence of tumor recurrence.

Discussion

This report describes ovarian mucinous cystadenoma, minimal deviation adenocarcinoma of the cervix, and areas of mucinous metaplasia of the endometrium and tubal mucosa arising in a 52-year-old woman with PJS. The diagnosis of PJS in the presented case was based on the following well-established criteria⁽⁵⁾: 1) Two or more Peutz-Jeghers syndrome polyps in the gastrointestinal tract; 2) One Peutz-Jeghers syndrome polyp in the gastrointestinal tract, together with either classical Peutz-Jeghers syndrome pigmentation or a family history of Peutz-Jeghers syndrome. Interestingly, the authors did not

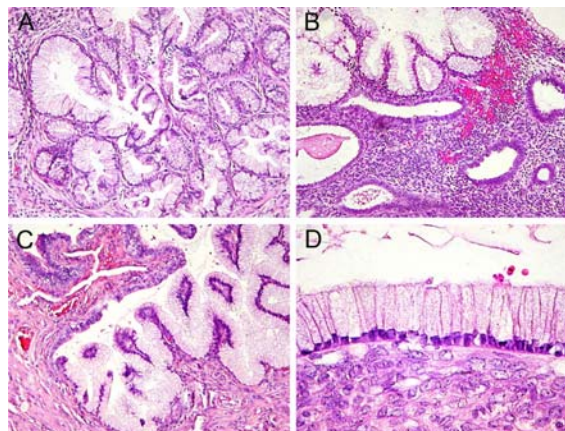


Fig. 1 Mucinous neoplasms and mucinous metaplasia in the genital organs. A) Minimal deviation adenocarcinoma of the cervix is characterized by well-differentiated neoplastic mucinous epithelium showing bland-appearing nuclei with only focal and mild atypia. (x100), B) Mucinous metaplasia of the endometrium. (x100), C) Mucinous metaplasia of the tubal epithelium (x100), D) Mucinous cystadenoma of the ovary (x400)

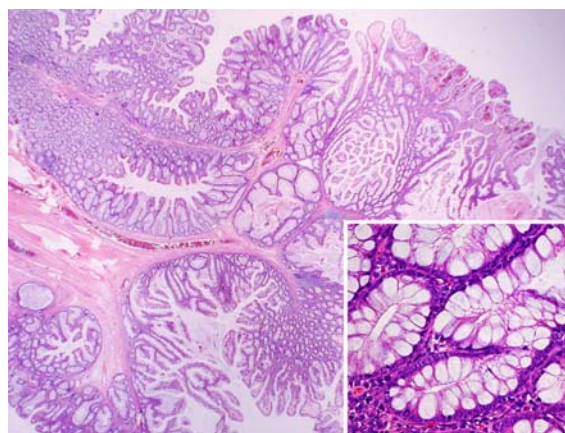


Fig. 2 Hamartomatous polyp of the colon. Low power magnification shows treelike arborizing pattern of the muscular tissue. The branching polypoid structures contain normal elements of colonic crypts(inset) with abundant goblet cells (x200)

initially diagnose for PJS at the time of operation for ovarian tumor. Rather, pathological diagnosis of mucinous cystadoma, MDA, and mucinous metaplasia suggested to the authors that there should be a search for PJS, leading to thorough physical examination and colonoscopy.

The presented case is a good example suggesting that people with PJS have a higher risk of ovarian mucinous tumor, minimal deviation adenocarcinoma (MDA) of the cervix, and mucinous metaplasia in the fallopian tubes and endometrium. MDA of the cervix is an uncommon variant of endocervical columnar-type adenocarcinoma of the uterine cervix characterized by a highly malignant potential, despite a high degree of differentiation. Circumferential sectioning of the cervix is very important when searching for MDA, which represents the poorest prognosis of neoplasia of the genital system in PJS patients. Screening of female patients affected by PJS should take into account the potential presence of this malignancy. However, Pap smear of the presented case had shown negative for malignancy this was because of its extremely well-differentiated aspect. This is the reason why it is often difficult to detect MDA by Pap smear.

MDA, adenoma malignum is a rare, very well differentiated variant of adenocarcinoma of the cervix. In the population as a whole, adenoma malignum accounts for 1-3% of all adenocarcinomas of the cervix, which in themselves only account for 5-15% of all neoplasms of the cervix⁽⁶⁾. Watery or mucoid vaginal discharge is the most common presenting symptom. MDA carries a poor prognosis, possibly as a consequence of (a) the concurrent ovarian pathology and (b) the innocuous histological appearance, which renders detection on standard cervical smears difficult. Recent work by Granter et al⁽⁷⁾ and Hirai et al⁽⁸⁾ have indicated some characteristics, which may be useful in the cytological diagnosis of MDA. Deep biopsy is recommended if either Pap smear or cone biopsy are equivocal. Giardiello et al⁽⁹⁾ did not find a significant increase in squamous cell carcinoma of the cervix in Peutz-Jeghers Syndrome over the general population.

As in the presented case, patients with PJS can present with mucinous metaplasia in the fallopian tube and endometrium and ovarian mucinous tumors ranging from benign cystadenoma to low malignant potential (borderline) tumor^(10,11). In fact, each organ of the female genital tract in a PJS patient may be associated with hyperplastic, metaplastic or neoplastic lesions. These types of pathological conditions are observed mainly along the mucinous type of differentiation. Careful examination and multiple sections of resected organs within the entire genital tract are necessary to observe and identify all types of gynecological lesions expressed in patients with PJS.

In the present case, the histological examination also revealed the presence of typical mucinous metaplasia in which areas of tubal mucosa and endometrium are replaced by mucinous epithelium similar to that found in the normal endocervix. The potential involvement of such areas of mucinous tubal metaplasia in multistep carcinogenesis is still debated. Seidman⁽¹¹⁾ in 1994 reported seven cases of mucinous metaplasia of the tubal mucosa, suggesting an association of mucinous lesions of the fallopian tube with multiple independent mucinous neoplasms of the female genital tract with PJS. Although the possibility of transmucosal spread of the neoplastic mucinous epithelium from cervical MDA to the endometrium and tubal mucosa cannot be definitely excluded, the lack of direct continuity between each lesion in this patient and the favorable clinical course may support the multifocal independent origin of the lesions.

A wide range of ovarian tumors, both benign and malignant, are associated with PJS. These include cystadenomas, granulosa cell tumors, and sex cord tumors with annular tubules (SCTAT), which are usually benign. SCTAT is the most common variant of ovarian neoplasms documented in patients with PJS. Among patients with SCTAT, 36% are affected by PJS⁽¹²⁾. However, mucinous tumors of the ovary have occasionally been reported⁽¹³⁻¹⁶⁾, especially of benign histotype. Although the frequency of mucinous ovarian tumors in PJS patients may be close to that in the general population, it appears that the ratio of mucinous to serous tumors is higher in PJS patients than that in the general population (8:1-1:3, respectively)⁽¹³⁾.

Unfortunately, molecular genetic study was not available for the presented case. Peutz-Jeghers Syndrome (PJS) is a rare autosomal dominant condition with variable penetrance. Somatic mutations of the *STK11* gene are infrequent in sporadic cases of SCTAT and MDA. However, allelic losses at chromosome region 19p13.3 occur in at least a subset of sporadic cases of MDA⁽¹⁷⁾.

In conclusion, although an association has been established between PJS and an increased risk for neoplasm of the female genital tract, in particular SCTAT and MDA, the unique findings in the presented case which includes ovarian mucinous cystadenoma, MDA and mucinous metaplasia of the fallopian tube and endometrium have rarely been reported. The rare combination of these specific findings enabled the authors to carefully look for subtle evidence of PJS, especially pigmentation at the hard palate and multiple

hamartomatous polyps of the colon. The relatively frequent occurrence of genital tract neoplasms in women with PJS warrants close follow-up by gynecologists for early detection and treatment of these tumors.

References

1. Lindor NM, Greene MH. The concise handbook of family cancer syndromes. Mayo Familial Cancer Program. *J Natl Cancer Inst* 1998; 90: 1039-71.
2. McGarrity TJ, Kulin HE, Zaino RJ. Peutz-Jeghers syndrome. *Am J Gastroenterol* 2000; 95: 596-604.
3. Jeghers H, McKusick VA, Katz KH. Generalized intestinal polyposis and melanin spots of the oral mucosa, lips and digits; a syndrome of diagnostic significance. *N Engl J Med* 1949; 241: 993.
4. Bruwer A, Barga JA, Kierland RR. Surface pigmentation and generalized intestinal polyposis; (Peutz-Jeghers syndrome). *Proc Staff Meet Mayo Clin* 1954; 29: 168-71.
5. Tomlinson IP, Houlston RS. Peutz-Jeghers syndrome. *J Med Genet* 1997; 34: 1007-11.
6. Doi T, Yamashita Y, Yasunaga T, Fujiyoshi K, Tsunawaki A, Takahashi M, et al. Adenoma malignum: MR imaging and pathologic study. *Radiology* 1997; 204: 39-42.
7. Granter SR, Lee KR. Cytologic findings in minimal deviation adenocarcinoma (adenoma malignum) of the cervix. A report of seven cases. *Am J Clin Pathol* 1996; 105: 327-33.
8. Hirai Y, Takeshima N, Haga A, Arai Y, Akiyama F, Hasumi K. A clinicocytopathologic study of adenoma malignum of the uterine cervix. *Gynecol Oncol* 1998; 70: 219-23.
9. Giardiello FM, Brensinger JD, Tersmette AC, Goodman SN, Petersen GM, Booker SV, et al. Very high risk of cancer in familial Peutz-Jeghers syndrome. *Gastroenterology* 2000; 119: 1447-53.
10. Costa J. Peutz-Jeghers syndrome: case presentation. *Obstet Gynecol* 1977; 50: 15s-7s.
11. Seidman JD. Mucinous lesions of the fallopian tube. A report of seven cases. *Am J Surg Pathol* 1994; 18: 1205-12.
12. Young RH, Welch WR, Dickersin GR, Scully RE. Ovarian sex cord tumor with annular tubules: review of 74 cases including 27 with Peutz-Jeghers syndrome and four with adenoma malignum of the cervix. *Cancer* 1982; 50: 1384-402.
13. Papageorgiou T, Stratakis CA. Ovarian tumors associated with multiple endocrine neoplasias and related syndromes (Carney complex, Peutz-Jeghers syndrome, von Hippel-Lindau disease, Cowden's disease). *Int J Gynecol Cancer* 2002; 12: 337-47.
14. Chen KT. Female genital tract tumors in Peutz-Jeghers syndrome. *Hum Pathol* 1986; 17: 858-61.
15. Wacrenier A, Boman F, Farine MO, Durand-Reville M, Buisine MP, Porchet N, et al. Ovarian mucinous tumor of gastric and intestinal type associated with Peutz-Jeghers syndrome: in situ hybridization study of apomucin gene transcripts. *Ann Pathol* 1998; 18: 497-501.
16. Young RH, Scully RE. Mucinous ovarian tumors associated with mucinous adenocarcinomas of the cervix. A clinicopathological analysis of 16 cases. *Int J Gynecol Pathol* 1988; 7: 99-111.
17. Connolly DC, Katabuchi H, Cliby WA, Cho KR. Somatic mutations in the STK11/LKB1 gene are uncommon in rare gynecological tumor types associated with Peutz-Jegher's syndrome. *Am J Pathol* 2000; 156: 339-45.

เนื้องอกของระบบอวัยวะสืบพันธุ์สตรีและรอยโรคในระบบทางเดินอาหารในกลุ่มอาการ Peutz-Jeghers

จากรุวรรณ ตันติพิลากร, สุรพันธุ์ คุณอมรพงศ์, นิรัชร์ เลิศประเสริฐสุข, อีระ ทองสง

กลุ่มอาการ Peutz-Jeghers Syndrome เป็นโรคทางพันธุกรรมที่พบบ่อยโดยมีลักษณะสำคัญ คือ มีการสะสมของเม็ดสีเมลานินที่บริเวณเยื่อบุผิวหนัง ตีงเนื้องอก hamartomatous ที่ลำไส้ และมีความเสี่ยงของการเกิดมะเร็งเต้านม, มะเร็งระบบทางเดินอาหาร และมะเร็งทางนรีเวชเพิ่มขึ้น รายงานผู้ป่วยนี้ ได้นำเสนอกรณีผู้ป่วยหญิงอายุ 52 ปี ที่มีกลุ่มอาการ Peutz-Jeghers Syndrome ร่วมกับภาวะทางนรีเวชหลายชนิด ผู้ป่วยมาตรวจด้วยอาการอึดแน่นท้อง ผลการตรวจอัลตราซาวนด์พบมีก้อนในอุ้งเชิงกรานทางด้านซ้าย ผู้ป่วยได้รับการผ่าตัดมดลูก รังไข่ทั้งสองข้างและไส้ติ่ง ผลพยาธิวิทยาของรังไข่ข้างซ้ายเป็น mucinous cystadenoma บริเวณปากมดลูกพบ minimal deviation mucinous adenocarcinoma ส่วนบริเวณเยื่อบุโพรงมดลูกและท่อนำไข่พบ mucinous metaplasia การตรวจร่างกายเพิ่มเติมภายหลังพบ hyperpigmentation บริเวณเพดานแข็งในช่องปาก ผู้ป่วยได้รับการส่องกล้องในลำไส้ (colonoscopy) พบ multiple hamartomatous polyp จากการติดตามดูแลรักษาผู้ป่วยในระยะเวลา 4 ปี ผู้ป่วยปกติดีไม่มีการกลับเป็นซ้ำของมะเร็ง
