

Case Report

A Recalcitrant Acrodermatitis Continua of Hallopeau Successfully Treated with Etanercept

Narumol Silpa-archa MD*,
Chanisada Wongpraparut MD*

* Department of Dermatology, Faculty of Medicine Siriraj Hospital, Mahidol University, Bangkok, Thailand

Acrodermatitis continua of Hallopeau (ACH) is considered as a localized form of pustular psoriasis that is usually refractory to the treatment. The condition is characterized by sterile pustules, onychodystrophy, anonychia, and osteolysis of distal phalanges. The authors report a case of recalcitrant ACH who previously failed to topical corticosteroid, methotrexate, acitretin, and phototherapy and rapidly responded to etanercept in combination with acitretin. The primary varicella infection occurred during the therapy. The patient was able to discontinue etanercept within four months after starting the treatment. The lesion was then under-controlled by acitretin and topical clobetasol ointment with an 8-month clinical remission.

Keywords: Acrodermatitis continua of Hallopeau, Pustular psoriasis, Etanercept, Varicella infection

J Med Assoc Thai 2011; 94 (9): 1154-7

Full text. e-Journal: <http://www.mat.or.th/journal>

Case Report

A 24-year-old patient was referred to the department of Dermatology with a 5-year history of persistent erythematous plaques with pustules on distal phalanges of all fingers, some toes and both palms (Fig. 1). All the fingernails and some of her toenails had totally shed, causing a limitation in fine movement. None of the lesions was detected at other parts of the body. She was previously healthy and denied tobacco smoking or alcohol consumption. She had no family history of psoriasis. Gram's stain and potassium hydroxide (KOH) preparation from the pustules showed no organism. Radiological examination of the hands revealed periarticular osteoporosis of distal interphalangeal (DIP) joint of both hands. Laboratory investigation included complete blood count (CBC), blood chemistry (liver function test, blood urea nitrogen, creatinine), hepatitis B and C viruses, Anti-HIV, chest x-ray and tuberculin skin test were within normal limits or negative. Acrodermatitis continua of Hallopeau was diagnosed. She was treated with various treatment modalities including topical high potency steroids, 3 months of methotrexate (15 mg/week),

2 years of acitretin (0.7 mg/kg/day) and local PUVA (psoralen and ultraviolet A) without significant response. Because of the lacking of efficacy of previous treatments, the symptoms were getting worse. Eventually, the authors started etanercept 50 mg subcutaneous (SC) twice weekly combined with daily acitretin 0.5 mg/kg for a week, and then decreased etanercept to 25 mg SC twice weekly combined with daily acitretin 0.5 mg/kg.

After the second doses of 50 mg etanercept, the lesions and joint symptom were dramatically improved. After six doses of etanercept, the lesions were completely clear (Fig. 2). Simultaneously, the patient developed generalized papulovesicular lesions on the face, trunk, and arms without dermatomal distribution. She also developed coryza and low-grade fever. No mucosal lesion was detected. She had never had chickenpox before. Tzanck's smear from the vesicle was positive for multinucleated giant cell. Primary varicella infection was diagnosed and oral acyclovir had been prescribed for a week. The authors decided to discontinue etanercept and the pustules on phalanges recurred. After one week, the varicella lesions turned to small crusts and in two weeks, the lesions had completely disappeared. After a 2-week discontinuation, the authors restarted etanercept 50 mg weekly combined with 1 mg/kg/day of acitretin without any problems. The disease responded well within 4 weeks. During the course of therapy, no new

Correspondence to:

Silpa-archa N, Department of Dermatology, Faculty of Medicine, Siriraj Hospital, Mahidol University, 2 Prannok Rd, Bangkoknoi, Bangkok 10700, Thailand
Phone: 0-2419-4333, Fax: 0-2411-5031
E-mail: doctornarumol@gmail.com

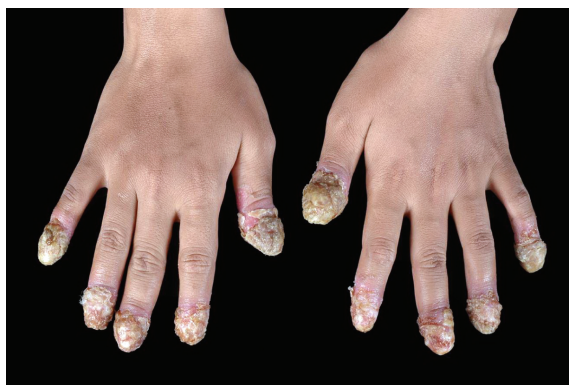


Fig. 1 Before etanercept therapy

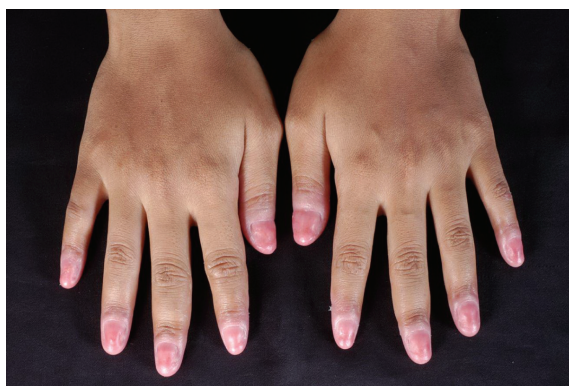


Fig. 2 After the 6th dose of etanercept, the lesion completely subsided and there was regrowth of fingernails

lesion recurred. Hence, etanercept was discontinued after four months of therapy. The authors continued acitretin 0.7 mg/kg/day and topical clobetasol ointment for controlling her lesions. During the 8-month follow-up period, no disease recurrence and her nails started to grow back.

Discussion

Acrodermatitis continua of Hallopeau (ACH) is a localized form of pustular psoriasis that is usually refractory to treatment. It is more common in middle-aged women but can occur in any age group. Typically, lesions contain pustules that coalesce to form lakes of pus on a scaly erythematous base. The lesions start from distal part of digits and can spread proximally to hands and dorsum of forearms and feet. Lesions on nail bed and nail matrix generally lead to onychodystrophy and anonychia. The affected part can cause osteolysis of distal phalanges, as seen in x-ray⁽¹⁾. At present, management of ACH is a challenging

problem. Systemic acitretin is considered as the first-line treatment. Other therapies that have been used include corticosteroids, methotrexate, phototherapy (psoralen plus ultraviolet A, ultraviolet B), calcipotriol, topical tacrolimus and thalidomide⁽²⁻⁵⁾. However, these treatments have been tried with uncertain results.

Etanercept (Enbrel[®]) is a recombinant human receptor fusion protein that competitively inhibits the interaction of TNF- α with cell surface receptor. TNF- α is a pro-inflammatory cytokine involved in pathogenesis of ACH and other forms of psoriasis. Its concentration was detected in the joints and skin of psoriasis patients⁽⁶⁾. In 2005, etanercept was initially reported successful in ACH treatment⁽⁷⁾. Subsequently, many reports demonstrated the benefits of this drug in ACH, sometimes added to other therapies^(8,9). Nevertheless, few cases of ACH had been reported failure to etanercept^(10,11). In Table 1 the authors summarize ACH cases treated with etanercept during 2005-2010. Duration varied from three months to 30 months. Overall etanercept was effective in ACH except for the two studies. Etanercept was usually combined with other treatments such as methotrexate and acitretin. Other anti-TNF- α , including infliximab and adalimumab, were reported as successful for ACH^(12,13). The adverse effect of anti-TNF- α is related to reactivation of many infections such as tuberculosis, fungi, and viruses due to immunomodulating properties. Varicella zoster virus (VZV) infection (primary varicella, recurrent varicella, herpes zoster infection) had been increasingly reported in patients who received anti-TNF- α ⁽¹⁴⁾. Recently there was a report of recurrent varicella infection in a psoriasis patient receiving etanercept for one month. It was proposed that anti-TNF- α agents might aggravate the VZV replication and VZV antigen expression⁽¹⁵⁾. The present patient developed primary varicella infection during etanercept possibly due to the change in the immune status. However, she responded well to acyclovir treatment.

In conclusion, the authors demonstrated the recalcitrant ACH patient who had a dramatic response to etanercept combined with acitretin. The authors recommend etanercept should be considered as an option for recalcitrant ACH.

Potential conflicts of interest

None.

References

1. Piraccini BM, Fanti PA, Morelli R, Tosti A. Hallopeau's acrodermatitis continua of the nail

Table 1. ACH cases treated with etanercept

Authors	Yrs	Age/sex	Dose of etanercept	Combined treatment	Duration	Results
Puig et al ⁽⁹⁾	2010	78/F	50 mg twice weekly	Methotrexate 10-15 mg/week	30 months	Effective but relapsed after discontinuation, switch to adalimumab
Gokdemir et al ⁽¹¹⁾	2009	47/M	50 mg twice weekly	-	3 months	Ineffective
Thielen et al ⁽⁸⁾	2008	64/M	25 mg twice weekly	-	9 months	Effective
Adisen et al ⁽¹⁰⁾	2007	40/M	25-50 mg twice weekly	Topical steroid	3 months	Ineffective
Weisshaar and Diepgen ⁽¹⁶⁾	2007	50/M	25 mg twice weekly	-	9 months	Effective
Ahmad and Rogers ⁽⁶⁾	2007	Not stated	Not stated	-	Not stated	Effective
Bonish et al ⁽¹⁷⁾	2006	76/M	50 mg biweekly	-	Not stated	Effective
Nikkels and Pierard ⁽¹⁸⁾	2006	74	50 mg twice weekly	Acitretin 50 mg/day	6 months	Effective
Kazinski et al ⁽⁷⁾	2005	65/M	25-50 mg twice weekly	Acitretin 75 mg/day	3 months	Effective
This patient		24/F	25-50 mg twice weekly	Acitretin 0.5-0.7 mg/kg/d	4 months	Effective

apparatus: a clinical and pathological study of 20 patients. *Acta Derm Venereol* 1994; 74: 65-7.

- Chowdhury MM, Motley RJ. Treatment of acrodermatitis continua of Hallopeau with oral propylthiouracil and methotrexate. *Clin Exp Dermatol* 2001; 26: 657-60.
- Bordignon M, Zattra E, Albertin C, Belloni-Fortina A. Successful treatment of a 9-year-old boy affected by acrodermatitis continua of Hallopeau with targeted ultraviolet B narrow-band phototherapy. *Photodermatol Photoimmunol Photomed* 2010; 26: 41-3.
- Kiszewski AE, De Villa D, Scheibel I, Ricachnevsky N. An infant with acrodermatitis continua of Hallopeau: successful treatment with thalidomide and UVB therapy. *Pediatr Dermatol* 2009; 26: 105-6.
- Brunasso AM, Lo SG, Massone C. Recalcitrant acrodermatitis continua of hallopeau treated with calcitriol and tacrolimus 0.1% topical treatment. *J Eur Acad Dermatol Venereol* 2008; 22: 1272-3.
- Ahmad K, Rogers S. Two years of experience with etanercept in recalcitrant psoriasis. *Br J Dermatol* 2007; 156: 1010-4.
- Kazinski K, Joyce KM, Hodson D. The successful use of etanercept in combination therapy for treatment of acrodermatitis continua of hallopeau. *J Drugs Dermatol* 2005; 4: 360-4.
- Thielen AM, Barde C, Marazza G, Saurat JH. Long-term control with etanercept (Enbrel) of a severe acrodermatitis continua of Hallopeau refractory to infliximab (Remicade). *Dermatology* 2008; 217: 137-9.
- Puig L, Barco D, Vilarrasa E, Alomar A. Treatment of acrodermatitis continua of Hallopeau with TNF-blocking agents: case report and review. *Dermatology* 2010; 220: 154-8.
- Adisen E, Oztas M, Gurer MA. Lack of efficacy of etanercept in acrodermatitis continua of Hallopeau. *Int J Dermatol* 2007; 46: 1205-7.
- Gokdemir G, Kutlu S, Koslu A. Acrodermatitis continua resistant to etanercept: therapeutic challenge and unfortunate outcome. *J Eur Acad Dermatol Venereol* 2009; 23: 345-7.
- Rubio C, Martin MA, Arranz Sanchez DM, Vidaurrazaga C, Casado M. Excellent and prolonged response to infliximab in a case of recalcitrant acrodermatitis continua of Hallopeau. *J Eur Acad Dermatol Venereol* 2009; 23: 707-8.
- Ryan C, Collins P, Kirby B, Rogers S. Treatment of acrodermatitis continua of Hallopeau with

- adalimumab. Br J Dermatol 2009; 160: 203-5.
14. Tresch S, Trueb RM, Kamarachev J, French LE, Hofbauer GF. Disseminated herpes zoster mimicking rheumatoid vasculitis in a rheumatoid arthritis patient on etanercept. Dermatology 2009; 219: 347-9.
 15. Becart S, Segaert S. Recurrent varicella in an adult psoriasis patient treated with etanercept. Dermatology 2008; 217: 260-1.
 16. Weisshaar E, Diepgen TL. Successful etanercept therapy in therapy refractory acrodermatitis continua suppurativa Hallopeau. J Dtsch Dermatol Ges 2007; 5: 489-92.
 17. Bonish B, Rashid RM, Swan J. Etanercept responsive acrodermatitis continua of Hallopeau: is a pattern developing? J Drugs Dermatol 2006; 5: 903-4.
 18. Nikkels AF, Pierard GE. Etanercept and recalcitrant acrodermatitis continua of Hallopeau. J Drugs Dermatol 2006; 5: 705-6.

ผู้ป่วยโครเดอร์มาไตติส คอนตินูอา ออฟ ฮาไลโพ ที่ต้องต่อการรักษา 1 ราย ตอบสนองดีมากต่อการรักษาด้วยยาอีทาเนอเซพ

นฤมล ศิลปอาชา, ชนิษฐา วงษ์ประภารัตน์

โครเดอร์มาไตติส คอนตินูอา ออฟ ฮาไลโพ เป็นชนิดหนึ่งของโรคสะเก็ดเงินชนิดตุ่มหนองซึ่งเกิดเฉพาะที่ส่วนมากมักต้องต่อการรักษา ภาวะนี้มีลักษณะทางคลินิกคือพบตุ่มหนองที่ไม่มีการติดเชื้อ ภาวะเล็บผิดปกติ ภาวะไม่มีเล็บ และกระดูกนิ้วมือส่วนปลายสลายตัว ผู้นิพนธ์ได้รายงานผู้ป่วย 1 ราย โรคโครเดอร์มาไตติส คอนตินูอา ออฟ ฮาไลโพ ซึ่งไม่ตอบสนองต่อการใช้ยาทาในกลุ่มสเตียรอยด์, ยาเมทโทเทรกเซตและอะซิเทรตตินรับประทาน รวมถึงการฉายแสงอาทิตย์เทียมเฉพาะที่ แต่ผู้ป่วยตอบสนองดีมากต่อยาอีทาเนอเซพร่วมกับยาอะซิเทรตติน ผู้ป่วยได้รับการวินิจฉัยว่าเป็นอีสุกอีใสระหว่างการรักษา ผู้ป่วยสามารถหยุดยาอีทาเนอเซพได้ในระยะเวลา 4 เดือน หลังได้รับยา หลังการติดตามผู้ป่วยเป็นระยะเวลา 8 เดือน โรคของผู้ป่วยสามารถควบคุมได้โดยการใช้ยาอะซิเทรตติน ร่วมกับการทายาโคลอเบตทาซอลชนิดขี้ผึ้ง