

# Treatment of Tinea Capitis Caused by *Microsporum Ferrugineum* with Itraconazole

Wanee Wisuthsarewong MD\*  
Angkana Chaiprasert Dr rer nat\*\*

\*Department of Pediatrics, \*\*Department of Microbiology  
Faculty of Medicine Siriraj Hospital, Mahidol University, Bangkok 10700 Thailand

---

A prospective, non-randomized, open clinical trial was conducted to determine the efficacy of itraconazole for treatment of *Microsporum ferrugineum* tinea capitis. Itraconazole capsules were given every day in continuous group and every day for 1 week on and 3-week off in pulse therapy group. Concomitant topical therapy with 2% ketoconazole shampoo was used daily. Clinical evaluation consisted of assessing the degree of hair loss, scaling, erythema, pustule, and crust. In both groups, the treatment was stopped when the clinical signs of inflammation had resolved and the mycological examination had become negative or at week 12. There were 81 patients consisted of 49 boys and 32 girls enrolled and average dose of itraconazole was 4.5 mg/kg/day. During the 16-week study period (with 4-week follow-up visit) the overall clinical severity score decreased every visit ( $p < 0.001$ ). The improvement of the scores showed no statistical difference between both groups. The cumulative cure rate using combined clinical and mycological cure at week 16 in patients treated with continuous and pulse regimen was 54.3% (19/35) and 37.0% (17/46), respectively. The cumulative percentage of all cure rates including clinical cure, mycological cure and combined clinical and mycological cure of the continuous group was significantly higher than in the pulse therapy group ( $p < 0.001$ ). The superior efficacy of the continuous therapy group was observed after week 8. The cumulative cure rate increased with the longer treatment duration but decreased with the larger infected area involvement ( $p = 0.001$ ). All patients who were not cured showed improvement. There was no significant adverse effect. The higher dosage or the longer treatment duration of itraconazole may be required for treatment of tinea capitis from *M. ferrugineum* to achieve more cure rate.

**Keywords:** Tinea capitis, *Microsporum ferrugineum*, Itraconazole

**J Med Assoc Thai 2005; 88(Suppl 8): S72-9**

**Full text. e-Journal:** <http://www.medassocthai.org/journal>

---

Tinea capitis is a dermatophytic infection of the scalp and hair with involvement of the hair shaft and pilosebaceous unit that primarily affects preadolescent children. It is endemic in many developing countries and often associated with crowded living conditions<sup>(1-5)</sup>. Systemic treatment is required to eradicate the infection. Until now griseofulvin has been the mainstay of therapy for tinea capitis<sup>(6-11)</sup>. However, treatment failure is not uncommon; in those who improve, infection often clears slowly, occasionally requiring

several months for complete resolution. Many studies have shown the efficacy and safety of newer oral anti-fungal agents, including itraconazole, terbinafine and fluconazole in the treatment of tinea capitis<sup>(3,7-10,12)</sup>.

The aim of this study was to evaluate the effectiveness of itraconazole both continuous and pulse therapy in the treatment of children with tinea capitis caused by *Microsporum (M.) ferrugineum*.

## Material and Method

A prospective, non-randomized, open clinical trial was conducted at the Pak-Kred Home for Mentally and Physically Handicapped Children. The planned treatment schedule was discussed with and approved

---

Correspondence to: Wanee Wisuthsarewong, Department of Pediatrics, Faculty of Medicine Siriraj Hospital, Mahidol University, Bangkok 10700 Thailand. E-mail address: [siwws@mahidol.ac.th](mailto:siwws@mahidol.ac.th)

by the Director of the Institute. All children and caregivers in the Institute were screened for tinea capitis.

Inclusion criteria were children having clinical evidence of tinea capitis with a mycological (light microscopy and culture) confirmation diagnosis of the disease caused by *M. ferrugineum*. Exclusion criteria included: (1) a history of allergy to an azoles; (2) use of oral antifungal within 8 weeks or use of topical antifungal within 4 weeks before the commencement of itraconazole; (3) concurrent therapy with medications known to have an interaction with itraconazole; and (4) a history of abnormal liver or renal function tests.

The patients were placed on itraconazole capsule therapy according to their body weight. The capsules of 100 mg were manufactured by Janssen-Cilag; 25 mg and 50 mg capsules were prepared by the hospital pharmacist. Caregivers were instructed to administer the medication with or after meal. For very young patients who were unable to swallow the capsule caregivers were advised to open the capsule and mix the beads and contents with medium chain triglyceride oil to ensure maximum bioavailability. To prevent any confusion in giving the medication, the patients in the same buildings were treated with the same regimen. Itraconazole capsules were given every day in continuous group until clinical signs of inflammation had resolved and mycological examinations had become negative. The pulse therapy regimen involved itraconazole taken once daily with each pulse lasting 1 week and separated by a 3-week period without drug. The decision of whether to administer another pulse was determined by the clinical appearance of the scalp and previous mycological outcome at the time when the next pulse was due. The treatment was stopped at week 12 in both groups. Concomitant topical therapy with 2% ketoconazole shampoo was used daily during the course of the study.

Clinical evaluation consisted of assessing the degree of hair loss, scaling, erythema, pustule, and crust in the affected sites. Each feature was evaluated on a

4-point scale: absent (0), mild (1), moderate (2), or severe (3). The overall surface area of the tinea capitis was recorded. All patients had mycological assessment including the Wood's light examination, 10% potassium hydroxide (KOH) examination and fungal culture. The scalp material consisted of epilated hair stumps, skin scrapings and scales from the infected sites. All specimens were processed by the hospital's mycology laboratory. The light microscopic examination was performed after treatment of the specimen with KOH solution. Sabouraud dextrose agar supplemented with chloramphenicol, and cycloheximide was used for cultivation. They were incubated at room temperature and examined once a week for 4 weeks before being recorded as negative. The fungal colonies were identified by colony morphology and microscopic appearance from the slide culture.

Patients were seen in follow-up visits at the following time periods; at week 2, 4, 8, 12, and 16 after starting the therapy. At each visit, nurses and caregivers were asked of questions relating to efficacy, adverse effects, and compliance. Furthermore, clinical severity assessment, Wood's light and mycological examination were performed. An overall evaluation of the effectiveness of therapy was evaluated at every visit. The assessment of efficacy was based on the combined evaluation of the score of clinical parameter and mycological results. The result was graded as: (1) complete clinical (absence of clinical parameters associated with visible regrowth of scalp hair) and mycological cure (negative KOH examination and culture); (2) improvement, positive mycology with significant clinical improvement (reduction of overall clinical severity score > 50%), or negative mycology with no clinical improvement; and (3) failure, remaining positive mycology (either microscopy or culture) with no clinical improvement. Other laboratory tests were not obtained during the course of the study; however they were performed if symptoms or signs developed to warrant adverse effects.

**Table 1.** Demographic data of the patients and disease characters

	Continuous	Pulse	p
Sex; Male : Female	22:13	27:19	0.704
Age (months)	68.7 ± 22.4	64.9 ± 26.9	0.500
Dose (mg/kg/day)	4.5 ± 0.9	4.6 ± 0.8	0.744
Baseline clinical severity score	3.3 ± 1.1	3.2 ± 1.1	0.720
> 30% area involvement	26/35 (41.9%)	36/49 (58.1%)	0.676

**Statistical analysis**

All statistical evaluations were performed using the Software Package for Social Sciences (SPSS) for windows (Chicago,IL). Means, standard deviations and percentages were used as descriptive statistics where appropriate. Chi-square, Student's t-tests, repeated measures, Kaplan Meier test and Mann-Whitney U test were used for statistical analyses according to the type of data. Statistical significance was defined by a p value of less than 0.05.

**Results**

A total of 81 children with *M. ferrugineum* tinea capitis were enrolled (49 boys and 32 girls). Itraconazole continuous and pulse therapy were

administered in 35 and 46 cases, respectively. The details of sex distribution, age, daily dosage, baseline severity scores, and area involvement of both groups are shown in Table 1. There was no statistical difference in demographic data, baseline parameters, doses of itraconazole, and extent of the disease between the subjects of both groups. Scaling and hair loss were the most common presenting symptoms found in 100% in both groups. Erythema, crust, and pustule were found in 16 (45.7%), 4 (11.4%), and 1 (2.9%) in continuous group and 15 (32.6%), 13 (28.3%), and 0 (0%) in pulse therapy group. The cumulative percentage of overall clinical severity score decreased every 4-week visit in both groups ( $p < 0.001$ ). There was no statistical difference between groups in the improvement of

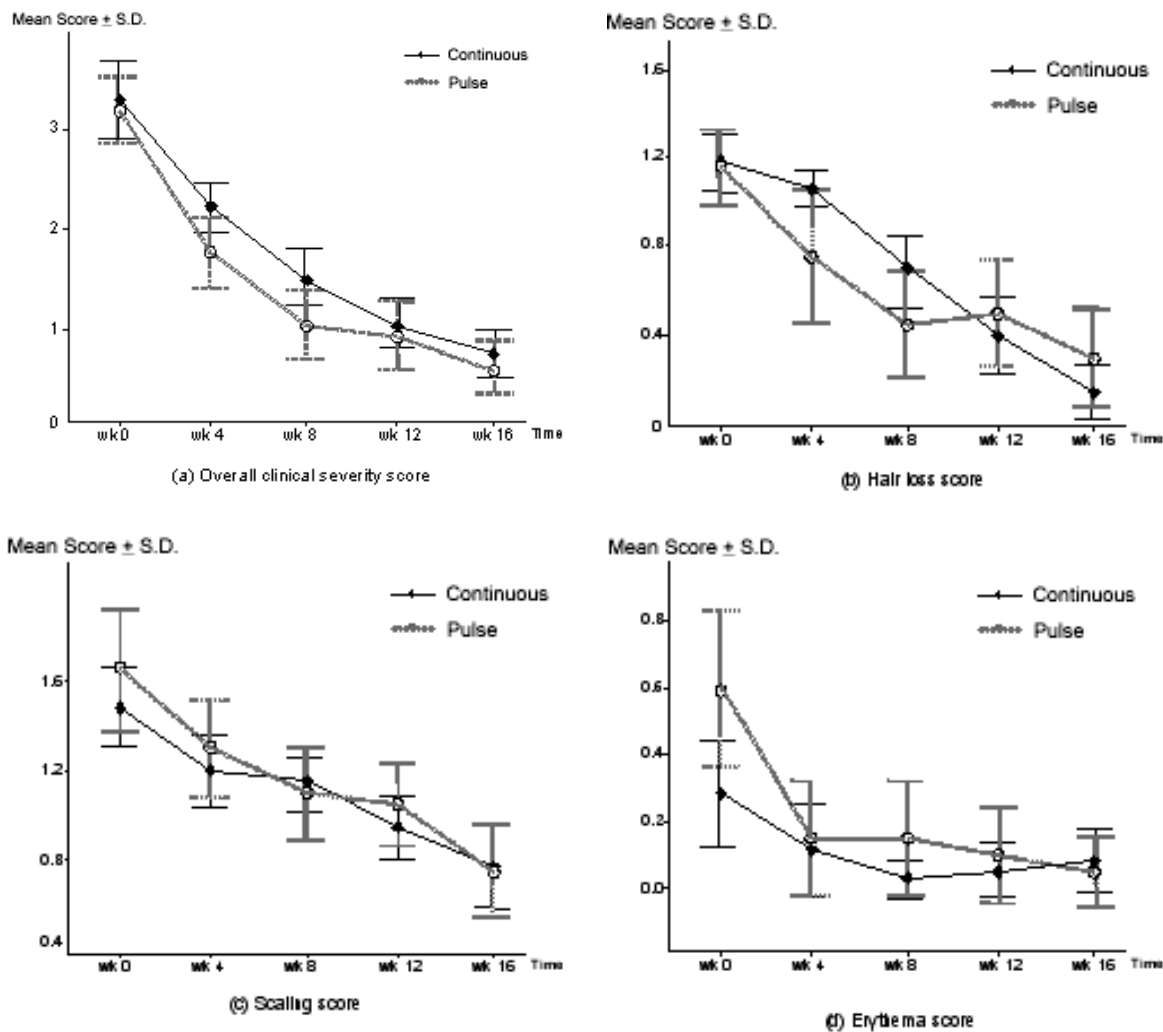


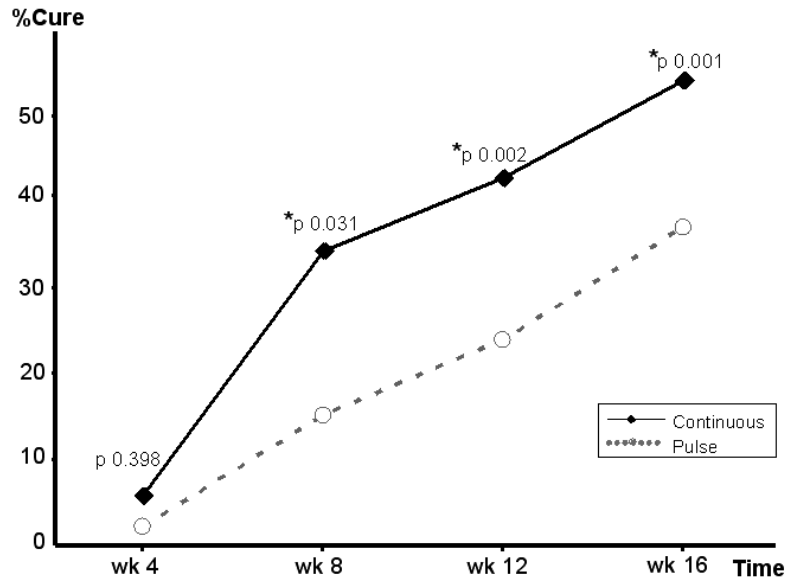
Fig. 1 The improvement of clinical parameter score

overall clinical severity score and scores of each parameter. Pustule and crust in all of the patients in both groups improved at week 2. (Figure 1)

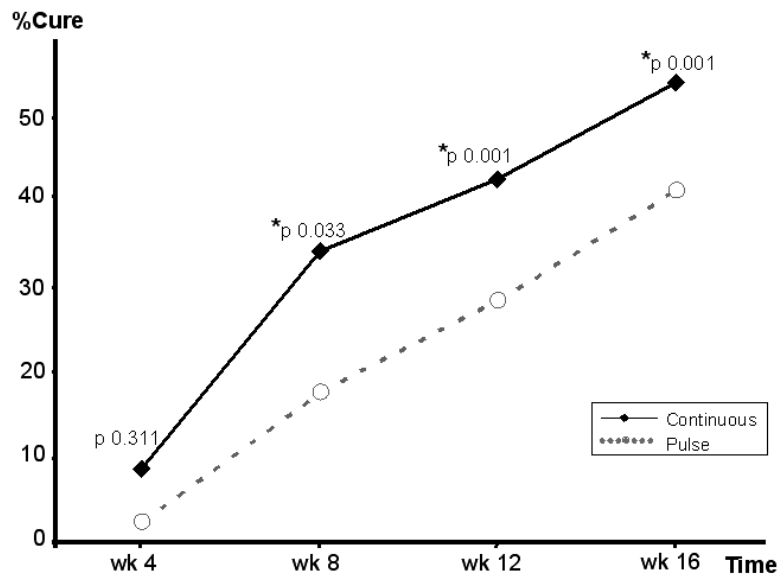
Two cases had positive KOH examination but negative culture at week 12 and showed negative result at week 16. In contrast, 1 case had negative KOH examination but had a positive culture at week 16 but all showed positive result after repeating the tests.

Wood s light examination showed good association to the result of both KOH examination and fungal culture ( $p = 0.001$ ).

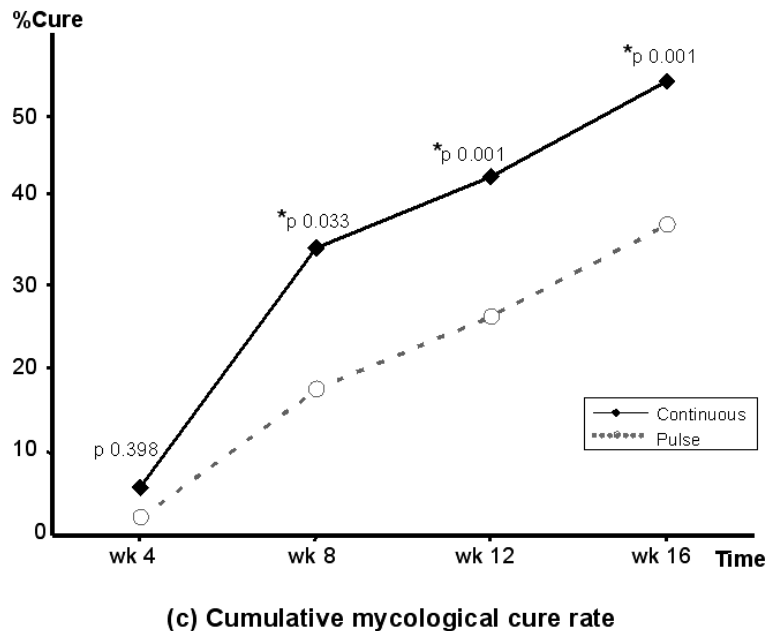
The cumulative cure rate using combined clinical and mycological cure at 16-week follow up visit in patients treated with continuous and pulse regimen was 54.3% (19 of 35) and 37.0% (17 of 46), respectively. There was no failure of the treatment.



(a) Cumulative combined clinical and mycological cure rate



(b) Cumulative clinical cure rate



**Fig 2.** Result of the cumulative percentage of cure rate

All patients who were not cured showed some improvement at the end of 16 weeks. In the pulse therapy group, the numbers of pulse required to produce both clinical and mycological cure were: one pulse in 1 patient (2.2%); two pulses in 6 patients (13.0%); three pulses in 4 patients (8.7%), and four pulses in 6 patients (13.0%). At the end of the study, the cumulative percentage of all cure rates including clinical cure, mycological cure and combined clinical and mycological cure of the continuous group was significantly higher than in the pulse therapy group ( $p = 0.001$ ). The superior efficacy of the continuous regimen was observed after week 8. (Figure 2) The cure rate of tinea capitis in this study had a reverse association with the extent of infected area ( $p = 0.001$ ). It decreased with larger surface area of the scalp being affected. It was not related to either the baseline severity score ( $p = 0.44$ ), or the dosage of itraconazole administered ( $p = 0.635$ ). There was no significant adverse effect observed during the study period.

### Discussion

Tinea capitis is one of the most common dermatophyte infections seen in children caused by a number of different fungal species of the genera *Trichophyton* and *Microsporum*. It is endemic in several developing countries. Socioeconomic factors such as family size, overcrowded living condition, poor

sanitary education, lack of good hygiene, and low socioeconomic class may predispose to infection<sup>(2,13)</sup>. The clinical presentation of tinea capitis varies by the etiologic agent from asymptomatic carrier, non-inflammatory alopecia to kerion and favus. *M. ferrugineum* causes none or minimal inflammation. Only scaling and hair loss with mild erythema of the scalp were observed in most cases in this study.

Because the clinical presentation of tinea capitis is diverse, a definitive diagnosis cannot be made based on the clinical appearance of the infection alone. It is important to confirm the diagnosis usually by morphological examination and fungal culture before committing the patient to a course of treatment that will last for several weeks. Microscopic visualization of infected hair shafts is highly specific and is the only inexpensive method that immediately confirms infection. However, it is a time-consuming and requires an experienced observer and equipment that is not available in every practitioner's office<sup>(14-18)</sup>. Fungal culture yields higher accurate identification of the organism involved and is therefore the most reliable means of confirming the diagnosis of tinea capitis. The results may be positive even when microscopy is negative, but may take up to 2-4 weeks to become available, which may cause a delay in the management<sup>(4,12,19)</sup>. The culture outcome-dependent drug administration offers a more reliable estimation

of the fungal status. This is of importance, because children should never be exposed unnecessarily to systemic therapy. The Wood's light examination (filtered ultraviolet light peak of 365 nm) is a simple bedside test that can detect fluorescent forms of tinea capitis. The *M. ferrugineum* infection can be recognized readily by the characteristic bright yellow green fluorescence under the Wood's light examination<sup>(4,20)</sup>. It demonstrates a great benefit as the helpful diagnostic tool from its high correlation with KOH examination and fungal culture if the infection is caused by *M. ferrugineum*<sup>(21)</sup>. Two cases revealed positive KOH direct examination but negative culture reflecting the possible non-viable filaments from the effect of antifungal treatment of that sample. In contrast, 1 case had negative KOH examination but positive culture. The false-negative interpretations can occur in the following conditions: early case, inflammatory tinea capitis, incorrectly obtained sample, insufficient examination, and finding misinterpretation. Since its sensitivity is not adequate, the fungal culture is usually necessary<sup>(13,19,22)</sup>.

The principles of tinea capitis management consist of oral antifungal therapy, adjunctive therapy, and strategies to reduce reinfection. Topical antimycotic agents are ineffective as sole therapy for tinea capitis; therefore an oral antimycotic agent is needed to penetrate the hair follicles and obtain reasonable cure rates. Griseofulvin has been the gold standard for the treatment of tinea capitis since 1958 and is the only drug approved by the Food and Drug Administration for the treatment of this disease in children. However, this treatment has been found to be lengthy and the response rate in pediatric patients with tinea capitis appears to be decreasing. Higher dosage and longer duration of treatment may be required<sup>(3-5,16-20,23-27)</sup>. Ketoconazole has been compared with griseofulvin for the treatment of tinea capitis and has been found to be less effective than griseofulvin. Thus ketoconazole is generally reserved for patients who do not respond to griseofulvin despite adequate blood levels, are allergic to griseofulvin or develop adverse effects<sup>(25,27)</sup>.

New oral antifungal agents such as itraconazole, terbinafine, and fluconazole has been demonstrated to be effective and safe in the treatment of tinea capitis<sup>(12,20,28)</sup>. Itraconazole is a lipophilic and keratinophilic triazole derivative. After administration it persists in the stratum corneum and continues to act after drug discontinuation. In contrast to skin, nail and hair, the drug in plasma decreases to low levels over 7-10 days. This pharmacokinetic enables it to be

effectively used as short-term pulse therapy<sup>(29-32)</sup>. Itraconazole has also been shown to be effective in treating tinea capitis in both continuous therapy and pulse therapy. When it is given for tinea capitis, the recommended dosage is about 3-5 mg/kg/day given until cure<sup>(10,20,28)</sup>. This study demonstrated that although the cure rate increased with longer treatment duration, itraconazole 4.5 mg/kg/day given either continuously or pulse therapy for the treatment of *M. ferrugineum* tinea capitis gave a quite low response rate. The cure rate often continues to progress for several weeks after the cessation of treatment. The continuous therapy gives the greater cumulative cure rate than the pulse therapy regimen. From the association of the cumulative cure rate, patients affected with larger infected area at baseline require treatment for a longer period of time ( $p = 0.001$ ). The improvement of clinical parameters and safety profile did not show any statistical significantly difference between both regimens.

The reason for poor response of *M. ferrugineum* to itraconazole is unclear. The dose of itraconazole used in this study may have been inadequate for the treatment of tinea capitis from *M. ferrugineum*. The duration of therapy may not have been long enough. Many data recommended higher dosage and longer duration of treatment to achieved superior cure rates<sup>(11,33,34)</sup>. Our study showed that itraconazole therapy was safe and well tolerated for the treatment of tinea capitis. However, if patients require continuous, higher and longer treatment regimen, laboratory monitoring may be needed. From our study at the same Institute in 1996, griseofulvin gave the 84.8% cure rate for tinea capitis mostly (66.7%) from *M. ferrugineum* infection after 15-week treatment<sup>(21)</sup>. Because of its high cost and the lack of evidence for greater efficacy than griseofulvin in the treatment of tinea capitis from *M. ferrugineum*, we currently cannot recommend routine use of itraconazole for this indication.

The presence of asymptomatic carrier state is a major contributor to the persistent prevalence and difficulty in eradicating the infection from *M. ferrugineum*, an anthropophilic dermatophyte, which is highly infectious. A clean environment free from fomites and avoidance of sharing personal items should be encouraged. Searching for carriers and recommendation for appropriate treatment should be undertaken. Medicated antifungal shampoos containing selenium sulfide, ketoconazole, or povidone shampoo should be given daily in patients and household members<sup>(16-19,35)</sup>.

Any new therapy for tinea capitis should bring about rapid clinical and mycological cure without relapse. The ideal antimycotic medication for children with tinea capitis should possess the following characteristics, i.e. , (1) high efficacy, (2) good safety profile and few drug interactions, (3) short treatment duration, (4) pleasant-tasting liquid formulation, and (5) low cost. Relative cost effectiveness of griseofulvin compared to alternative treatments suggest that it may be well suited to treat patients with tinea capitis in developing countries. Regardless of the therapy employed, one should perform follow-up clinical and mycological examination. Treatment should be tailored for each individual patient according to clinical and mycological response.

## References

1. Elewski BE. Tinea capitis: itraconazole in *Trichophyton tonsurans* infection. *J Am Acad Dermatol* 1994;31:65-7.
2. Menan EI, Zongo-Bonou O, Rouet F, KiKI-Barro PC, Yavo W, NGuessan NF, et al. Tinea capitis in schoolchildren from Ivory Coast (western Africa). A 1998-1999 cross-sectional study. *Int J Dermatol* 2002;41:204-7.
3. Chan YC, Friedlander SF. New treatments for tinea capitis. *Curr Opin Infect Dis* 2004;17:97-103.
4. Gupta AK, Hofstader S, Adam P, Summerbell R. Tinea capitis: an overview with emphasis on management. *Pediatr Dermatol* 1999;16:171-89.
5. Blumer JL. Pharmacologic basis for the treatment of tinea capitis. *Pediatr Infect Dis J* 1999;18:191-9.
6. Gupta AK, Solomon RS, Adam P. Itraconazole oral solution for the treatment of tinea capitis. *Br J Dermatol* 1998;139:104-6.
7. Gupta AK, Adam P, De Doncker P. Itraconazole pulse therapy for tinea capitis: a novel treatment schedule. *Pediatr Dermatol* 1998;15:225-8.
8. Greer DL. Treatment of tinea capitis with itraconazole. *J Am Acad Dermatol* 1996;35:637-8.
9. Abdel-Rahman SM, Powell DA, Nahata MC. Efficacy of itraconazole in children with *Trichophyton tonsurans* tinea capitis. *J Am Acad Dermatol* 1998;38:443-6.
10. Gupta AK, Hofstader SL, Summerbell RC, Solomon R, Adam P, Alexis M, et al. Treatment of tinea capitis with itraconazole capsule pulse therapy. *J Am Acad Dermatol* 1998;39:216-9.
11. Mohrenschlager M, Schnopp C, Feso C, Strom K, Beham A, Mempel M, et al. Optimizing the therapeutic approach in tinea capitis of childhood with itraconazole. *Br J Dermatol* 2000;143:1011-5.
12. Gupta AK, Adam P, Dlova N, Lynde C, Hofstader S, Marar N, et al. Therapeutic options for the treatment of tinea capitis caused by *Trichophyton species*: griseofulvin versus the new oral anti-fungal agents, terbinafine, itraconazole, and fluconazole. *Pediatr Dermatol* 2001;18:433-8.
13. Pomeranz AJ, Sabnis SS. Tinea capitis: epidemiology, diagnosis and management strategies. *Paediatr Drugs* 2002;4:779-83.
14. Drake LA, Dinehart SM, Farmer ER, Goltz RW, Graham GF, Hordinsky MK, et al. Guidelines of care for superficial mycotic infections of the skin: tinea capitis and tinea barbae. Guidelines/Outcomes Committee. American Academy of Dermatology. *J Am Acad Dermatol* 1996;34:290-4.
15. Hubbard TW. The predictive value of symptoms in diagnosing childhood tinea capitis. *Arch Pediatr Adolesc Med* 1999;153:1150-3.
16. Chen BK, Friedlander SF. Tinea capitis update: a continuing conflict with an old adversary. *Curr Opin Pediatr* 2001;13:331-5.
17. Mercurio MG, Elewski BE. Tinea capitis treatment. *Dermatologic Therapy* 1997;3:79-83.
18. Hebert AA. Diagnosis and treatment of tinea capitis in children. *Dermatologic Therapy* 1997;2:78-83.
19. Higgins EM, Fuller LC, Smith CH. Guidelines for the management of tinea capitis. British Association of Dermatologists. *Br J Dermatol* 2000;143:53-8.
20. Elewski BE. Treatment of tinea capitis: beyond griseofulvin. *J Am Acad Dermatol* 1999;40:S27-30.
21. Wisuthsarewong W, Chairasert A, Viravan S. Outbreak of tinea capitis caused by *Microsporum ferrugineum* in Thailand. *Mycopathologia* 1996;135:157-61.
22. Schwartz RA, Janniger CK. Tinea capitis. *Cutis* 1995;55:29-33.
23. Friedlander SF. The evolving role of itraconazole, fluconazole and terbinafine in the treatment of tinea capitis. *Pediatr Infect Dis J* 1999;18:205-10.
24. Bennett ML, Fleischer AB, Loveless JW, Feldman SR. Oral griseofulvin remains the treatment of choice for tinea capitis in children. *Pediatr Dermatol* 2000;17:304-9.
25. Friedlander SF. The optimal therapy for tinea capitis. *Pediatr Dermatol* 2000;17:325-6.
26. Nesbitt LT Jr. Treatment of tinea capitis. *Int J Dermatol* 2000;39:261-2.

27. Elewski BE, Hay RJ. International summit on cutaneous antifungal therapy, focus on tinea capitis, Boston, Massachusetts, November 11-13, 1994. *Pediatr Dermatol* 1996;13:69-77.
28. Temple ME, Nahata MC, Koranyi KI. Pharmacotherapy of tinea capitis. *J Am Board Fam Pract* 1999;12:236-42.
29. Legendre R, Esola-Macre J. Itraconazole in the treatment of tinea capitis. *J Am Acad Dermatol* 1990;23:559-60.
30. Saul A, Bonifaz A. Itraconazole in common dermatophyte infections of the skin: fixed treatment schedules. *J Am Acad Dermatol* 1990;23:554-8.
31. Jahangir M, Hussain I, Hasan MUL, Haroon TS. A double-blind, randomized, comparative trial of itraconazole versus terbinafine for 2 weeks in tinea capitis. *Br J Dermatol* 1998;139:672-4.
32. Gupta AK, Alexis ME, Raboobe N, Hofstader SLR, Lynde CW, Adam P, et al. Itraconazole pulse therapy is effective in the treatment of tinea capitis in children: an open multicentre study. *Br J Dermatol* 1997;137:251-4.
33. Ginter-Hanselmayer G, Smolle J, Gupta A. Itraconazole in the treatment of tinea capitis caused by *Microsporum canis*: experience in a large cohort. *Pediatr Dermatol* 2004;21:499-502.
34. Ungpakorn R, Ayutyanont T, Reangchainam S, Supanya S. Treatment of *Microsporum* spp. tinea capitis with pulsed oral terbinafine. *Clin Exp Dermatol* 2004;29:300-3.
35. Honig PJ. Tinea capitis: recommendations for school attendance. *Pediatr Infect Dis J* 1999; 18:211-4.

---

## การใช้ยา itraconazole รักษาโรคกลากบริเวณหนังศีรษะและเส้นผมที่เกิดจากเชื้อ *Microsporum ferrugineum*

วณิ วิสุทธ์เสวีวงศ์, อังคณา ฉายประเสริฐ

การศึกษานี้ทำขึ้นเพื่อศึกษาประสิทธิภาพของยาฆ่าเชื้อรา itraconazole ในการรักษาโรคกลากบริเวณหนังศีรษะและเส้นผมที่เกิดจากเชื้อ *Microsporum ferrugineum* โดยให้ผู้ป่วยรับประทานยา itraconazole ขนาด 4.5 มก./กก./วัน ในกลุ่มที่ได้รับการรักษาชนิดต่อเนื่องให้รับประทานยาละครั้งละครั้งทุกวันและในกลุ่มที่ได้รับการรักษาชนิดรับประทานยาเป็นช่วงให้รับประทานยาละครั้งเป็นเวลานาน 1 สัปดาห์ หลังจากนั้นหยุดยา 3 สัปดาห์ก่อนเริ่มช่วงต่อไป ผู้ป่วยจะได้รับยาจนอาการหายไปหมดและตรวจไม่พบเชื้อราหรือหยุดยาหลัง 12 สัปดาห์ การตรวจติดตามผลดูจากอาการแสดงต่างๆ ของโรคกลากได้แก่ ผมหงอก ขุยบริเวณหนังศีรษะ หนังศีรษะแดง มีตุ่มหนองและคราบสะเก็ดรวมทั้งตรวจเชื้อรา ระยะเวลาการติดตามนาน 16 สัปดาห์ มีผู้ป่วยเป็นโรคกลาก บริเวณหนังศีรษะและเส้นผมที่เกิดจากเชื้อ *M. ferrugineum* เข้าร่วมการศึกษารวมทั้งสิ้น 81 ราย เป็นเด็กผู้ชาย 49 ราย และเด็กผู้หญิง 32 ราย ทุก 4 สัปดาห์ที่ไปติดตามผลอาการแสดงต่างๆ ของโรคกลากดีขึ้นทุกครั้ง ( $p < 0.001$ ) อัตราการหายของโรคกลากดูจากทั้งอาการและการตรวจพบเชื้อราในกลุ่มที่รักษาแบบต่อเนื่องเท่ากับ 54.3% (19/35) ในกลุ่มรักษาแบบเป็นช่วงเท่ากับ 37.0% (17/46) อัตราการหายสะสมทุกชนิด ได้แก่ การหายของอาการแสดง การตรวจพบเชื้อราและการหายรวมทั้งอาการแสดงและการตรวจพบเชื้อราในกลุ่มที่รักษาแบบต่อเนื่องได้ผลดีกว่ากลุ่มที่รักษาแบบเป็นช่วง ( $p < 0.001$ ) โดยเริ่มเห็นผลแตกต่างกันตั้งแต่สัปดาห์ที่ 8 เป็นต้นไป อัตราการหายจะสูงมากขึ้นเรื่อยๆ เมื่อให้การรักษานานขึ้นและอัตราการหายนี้สัมพันธ์ผกผันกลับกับความกว้างของรอยโรค หนังศีรษะที่มีรอยโรคกว้างจะมีอัตรา การหายน้อย ( $p < 0.001$ ) ไม่พบผลข้างเคียงจากการใช้ยา โรคกลากบริเวณหนังศีรษะและเส้นผมที่เกิดจากเชื้อ *M. ferrugineum* นี้ อาจจำเป็นต้องใช้ยา itraconazole ในขนาดที่สูงขึ้นหรือใช้ยาระยะเวลานานขึ้นเพื่อให้ได้อัตราการหายเพิ่มมากขึ้น