

The Fundoscopic Features for Differentiation between Polypoidal Choroidal Vasculopathy and Choroidal Neovascularization from Age-Related Macular Degeneration

Atchara Ampornpruet MD*,
Paisan Ruamviboonsuk MD*, Sittika Kokekhuntod MD*

* Department of Ophthalmology, Rajavithi Hospital, Bangkok

Objectives: To evaluate the fundus features that can differentiate polypoidal choroidal vasculopathy (PCV) from choroidal neovascularization (CNV) due to age-related macular degeneration (AMD).

Design: Retrospective, case-control study.

Material and Method: The fundoscopic features of AMD-related CNV and PCV were compared for evaluation of relative risks for PCV. The odds ratio, sensitivity and specificity of each feature were also calculated.

Results: A total of 30 patients, 15 PCV and 15 age-matched non-PCV cases, approved by indocyanine green angiography (ICG), were enrolled. The odds ratio is highest for subretinal polyp-like structure and lowest in scar formation (28 and 0, respectively) and these ratios are statistically significant differences ($p = 0.001$ and 0.032 respectively). The ratio for either circinate exudates, or larger than 4-disc area of subretinal fluid, or retinal pigment epithelial detachment is 1.75. The ratio for peripapillary location is 1.63. Subretinal membrane has a ratio of 1 while subretinal hemorrhage and subretinal fibrin have less than 1; they are 0.31 and 0.23 respectively. All these ratios are not statistically significant differences ($p > 0.05$).

Conclusion: The orange polyp-like structures beneath retina are hallmarks for diagnosis of PCV. The "serosanguineous retinopathy", described as serous retinal detachment or retinal pigment epithelial detachment with circinate exudates with or without subretinal hemorrhage at the posterior pole or peripapillary region, may also suggest the condition.

Keywords: Polypoidal choroidal vasculopathy, PCV, Age-related macular degeneration, AMD, Choroidal neovascularization, CNV

J Med Assoc Thai 2005; 88 (Suppl 9): S51-6

Full text. e-Journal: <http://www.medassocthai.org/journal>

Polypoidal choroidal vasculopathy (PCV) is a specific form of choroidal neovascularization (CNV) which has been recognized worldwide recently. It is a primarily abnormality of choroidal vasculature which causes leakage and hemorrhage in the posterior pole fundus^(1,2). In clinical features, it may present as submacular hemorrhage or multiple, recurrent serosanguineous detachment of retinal pigment epithelium and/or

detachment of sensory retina with long term preservation of good vision⁽³⁻⁵⁾. In pathologic features, PCV is characterized by an inner choroidal vascular network ending in an aneurysmal bulge, visible clinically as reddish orange, spheroid, polyp-like structures, definitely detected by indocyanine green angiography (ICG)^(2,6). Before the availability of ICG, most cases of PCV were masked by the diagnosis of CNV from age-related macular degeneration (AMD), another leading cause of blindness throughout the world.

However, there appears to be significant differences in the risk factor, clinical interpretation, natural

Correspondence to : Ruamviboonsuk P, Department of Ophthalmology, Rajavithi Hospital, Bangkok 10400, Thailand. Phone: 0-1489-4455, Fax: 0-2982-9435, E-mail: paisan_ru@rcopt.org

course, and outcome of treatment between PCV and AMD-related CNV. PCV was found to be more common in Asians, and have better visual prognosis⁽⁷⁻¹²⁾. In a series of 22 eyes with a 1-year follow-up, complete absence of leakage and total regression of the polyps in PCV were observed in 21 eyes (95%) after photodynamic therapy⁽¹³⁾.

In Thailand, PCV is not familiar among general ophthalmologists and ICG is not generally available. Therefore, it is essential to find some diagnostic clues from fundus examinations, which may suggest the condition and differentiate it from AMD-related CNV. The present study may guide general ophthalmologists to the awareness and referral of this good prognostic form of abnormal choroidal vasculatures for appropriate investigations and managements.

Material and Method

In this retrospective, case-control study, 15 cases of PCV, proved by ICG, were randomly pulled from a group of patients who were diagnosed of having AMD-related CNV from fundus examination and fluorescein angiography (FA), and had ICG. Another 15 age-matched cases without PCV, also proved by ICG, were also randomly pulled from the same group of patients. These latter cases were used as controls. In cases with bilateral disease, only one eye was allowed for the selection.

The common fundoscopic features of AMD-related CNV and PCV were compared between cases and controls for evaluation of relative risks for PCV. The odds ratio of each feature was then calculated for representation of the relative risks. The features included the presence of subretinal fluid, hemorrhage, membrane, fibrin, scar, and polyp-like structure. Characteristics of exudates, retinal pigment epithelial detachment, and location of lesions were also included as the features in the present study.

Results

The demographic characteristics of patients enrolled in the present study in either PCV or non-PCV

group are listed in Table 1. The features of dilated fundus examination included in the present study are demonstrated in Table 2. The ratios are highest for subretinal polyp-like structures and lowest for scar formation; both ratios are statistically significant differences ($p = 0.001$ and 0.032 respectively). The sensitivity and specificity of each feature are also calculated and shown in Table 2. The subretinal polyp-like structure also has the highest sensitivity and specificity.

Discussion

The subretinal polyp-like structures are unique features for PCV. They are easily identified as slightly elevated subretinal orange masses in the macular or peripapillary region in stereoscopic examination using indirect ophthalmoscope, and especially slit lamp with contact lens. They may also locate at the center of circinate exudates with overlying serous retinal detachment or retinal pigment epithelial detachment (Fig. 1). When these detachments with circinate exudates, with or without subretinal hemorrhages, were found at the macular area, the term "serosanguineous maculopathy" has been used for representation^(1,8). This serosanguineous maculopathy or retinopathy should prompt ophthalmologists to rule out PCV by referral for ICG.

Although PCV can be associated with serous retinal detachment or retinal pigment epithelial detachment in any size, the present study suggests that the larger than 4-disc area of both features may be more specific. The 4-disc area was used as a cut-off point because it can be approximated easily in fundus examination based on a principle that an area with a diameter about 1/3 of the width of the major vascular arcade of the posterior pole should have approximately 4-disc area.

Another study also identified subretinal polyps, exudative (or serous) retinal detachment, and hemorrhagic pigment epithelial detachment as common clinical findings of PCV⁽¹⁴⁾. The study also identified subretinal hemorrhage as another common sign of PCV but the odds ratio of this feature in the present study

Table 1. Demographic characteristics of the patients in PCV and Non-PCV groups

	PCV	Non-PCV
Number of cases	15	15
Age (range)	63 (38-69)	62 (37-69)
Male	5	7
Female	10	8

Table 2. The odds ratio, sensitivity, and specificity for each fundus feature in PCV and Non-PCV groups

Lesion	PCV (n = 15)		Non-PCV (n = 15)		Odds ratio (95%CI)	Sensitivity	Specificity
	+	-	+	-			
Subretinal polyps	10	5	1	14	28 ^b (2.82-277.96)	0.67	0.93
Circinate exudation	7	8	5	10	1.75 (0.4-7.66)	0.47	0.67
Subretinal fluid ^a	7	8	5	10	1.75 (0.4-7.66)	0.47	0.67
Pigment epithelial detachment ^a	7	8	5	10	1.75 (0.4-7.66)	0.47	0.67
Peripapillary location	3	12	2	13	1.63 (0.23-11.64)	0.20	0.73
Subretinal membrane	4	11	4	11	1.00 (0.2-5.05)	0.27	0.73
Subretinal hemorrhage	7	8	11	4	0.31 (0.07-1.47)	0.47	0.27
Subretinal fibrin	2	13	6	9	0.23 (0.04-1.41)	0.13	0.60
Scar formation	0	15	4	11	0 ^c (0.55-0.99)	N/A	0.73

+ = positive, - = negative

^b Statistically significant (Chi-square test, p = 0.001), ^c Statistically significant (Chi-square test, p = 0.032), ^a Detachment more than 4-disc area

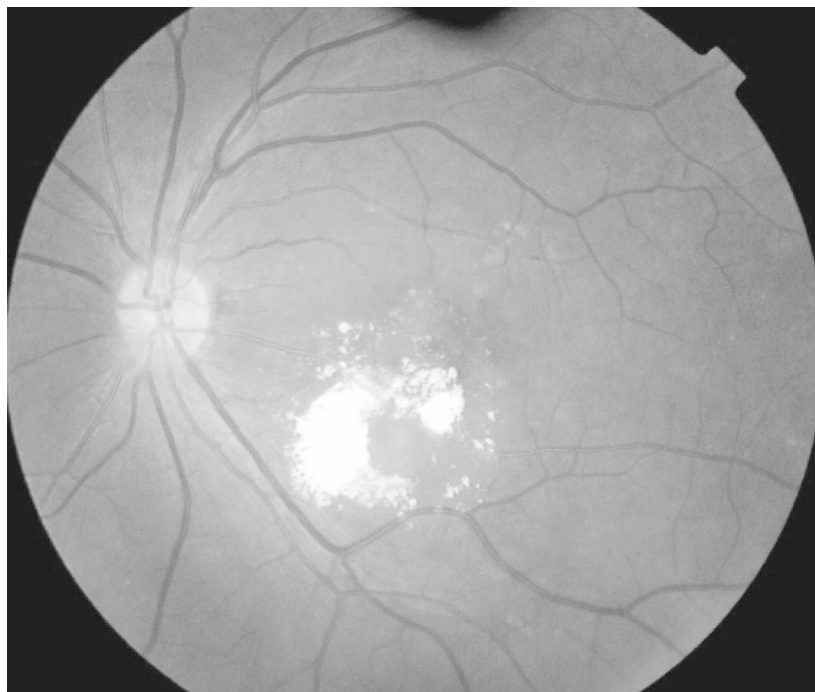

Fig. 1 The subretinal polyp-like structures locate at the center of circinate exudates with overlying retinal pigment epithelial detachment

was only 0.34 (Table 2). Many PCV cases present with massive subretinal hemorrhage from ruptured polyps^(1,14-15). However, those cases were not included in the present study because ICG cannot identify these ruptured polyps and the inclusion criterion for the present study was based solely by ICG identification. This may explain the low value of the odds ratio for submacular hemorrhage in the present study.

Despite multiple recurrent episode of hemorrhage, overt fibrous proliferation resulting in typical plaque-like, disciform characteristic of end stage CNV from AMD is not commonly seen in patients with PCV^(15,16). The authors also found no scar formation in all PCV cases in the present study. However, PCV cases which present with recurrent submacular hemorrhage may also have scar formation.

The peripapillary location should also be another unique feature of PCV (Fig. 2) since AMD-related CNV is commonly located in the posterior pole. The low odds ratio and low sensitivity were found in the present study due to the small sample size and retrospective data collection. Another method for verification of the suggested features for PCV is setting up a prospective study to determine whether patients presenting with the features actually have PCV.

In summary, PCV is a common form of CNV in Asian populations. Although the definite diagnosis is based on ICG finding, the condition can be recognized by dilated fundus examination. General ophthalmologists can suspect this condition when the features in the present study were presented and can refer these patients for further investigation and management.

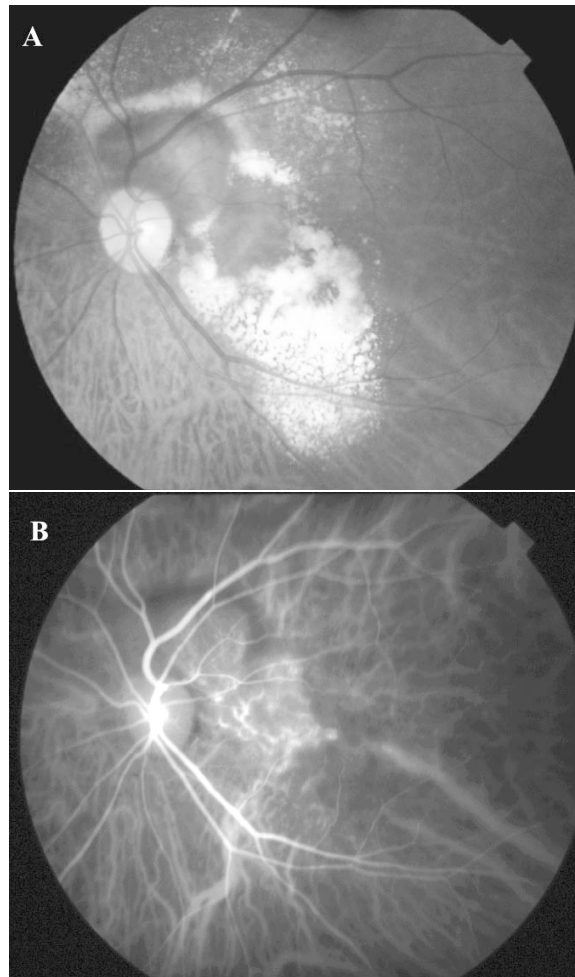


Fig. 2 (A) The peripapillary location of retinal pigment epithelial detachment with circinate exudates from PCV
(B) The polyps are clearly demonstrated at the maculopapillary bundle by indocyanine green angiography (ICG)

References

1. Ciardella AP, Donsoff IM, Huang SJ, Costa DL, Yannuzzi LA. Polypoidal choroidal vasculopathy. *Surv Ophthalmol* 2004; 49: 20-37.
2. Yannuzzi LA, Sorenson J, Spaide RF, Lipson B. Idiopathic polypoidal choroidal vasculopathy. *Retina* 1990; 10: 1-8.
3. Yannuzzi LA, Wong DW, Sforzolini BS. Polypoidal choroidal vasculopathy and neovascularization age-related macular degeneration. *Arch Ophthalmol* 1999; 117: 1503-10.
4. Perkovich BT, Zakov N, Spital G. Pigmentary epithelial detachments in black women. *Retina* 1990; 10: 18-26.
5. Ross RD, Gitter KA, Cohen C, Shoemaker KS. Idiopathic polypoidal choroidal vasculopathy associated with retinal arterial macroaneurysm and hypertensive retinopathy. *Retina* 1996; 16: 105-11.
6. Spaide RF, Yannuzzi LA, Slakter JS. Indocyanine green videoangiography of idiopathic polypoidal choroidal vasculopathy. *Retina* 1995; 15: 100-10.
7. Stern RM, Zakov N, Zegarra H, Gutman FA. Multiple recurrent serosanguineous retinal pigment epithelial detachments in black women. *Am J Ophthalmol* 1985; 100: 560-9.
8. Lafaut BA, Ieyes AM, Snyers B. Polypoidal choroidal vasculopathy in Caucasians. *Graefes Arch Clin Exp Ophthalmol* 2000; 238: 752-9.
9. Escano MF, Fujii S, Ishibashi K. Indocyanine green videoangiography in macular variant of idiopathic choroidal vasculopathy. *Jpn J Ophthalmol* 2000; 44: 313-6.
10. Ferris FL III. Senile macular degeneration: review of epidemiological features. *Am J Epidemiol* 1983; 118: 213-21.
11. Otsuji T, Takahashi K, Fukushima I. Optical coherence tomographic finding in idiopathic polypoidal choroidal vasculopathy. *Ophthalmic Surg Laser* 2000; 31: 210-4.
12. Okubo A, Sameshima M, Uremara A. Clinicopathological correlation of polypoidal choroidal vasculopathy revealed by ultrastructural study. *Br J Ophthalmol* 2002; 86: 1093-8.
13. Chan WM, Lam DS, Lai TY, Liu DT, Li KK, Yao Y, et al. Photodynamic therapy with verteporfin for symptomatic polypoidal choroidal vasculopathy: one-year results of a prospective case series. *Ophthalmology* 2004; 111: 1576-84.
14. Kwok AK, Lai TY, Chan CW, Neoh EL, Lam DS. Polypoidal choroidal vasculopathy in Chinese patients. *Br J Ophthalmol* 2002; 86: 892-7.
15. Iijima H, Imai M, Gohodo T. Optical coherence tomography of polypoidal choroidal vasculopathy. *Am J Ophthalmol* 2000; 129: 21-6.
16. Perkovich BT, Zakov N, Berlin LA. An update on multiple recurrent serosanguineous retinal pigment epithelial detachments in black woman. *Retina* 1990; 10: 18-26.

ลักษณะแสดงบนจอตาที่ไข้แยกระหว่างโรค polypoidal choroidal vasculopathy กับ choroidal neovascularization ที่เกิดจากโรค age-related macular degeneration

อัจฉรา อัมพรพฤติ, ไพศาล ร่วมวิบูลย์สุข, สิทธิกา โคกขุนทด

วัตถุประสงค์: เพื่อวิเคราะห์ลักษณะแสดงบนจอตาที่ไข้แยกระหว่าง polypoidal choroidal vasculopathy (PCV) กับ choroidal neovascularization (CNV) ที่เกิดจากโรค age-related macular degeneration (AMD)

รูปแบบการศึกษา: การศึกษาแบบย้อนหลัง และมีกลุ่มเปรียบเทียบ

วัตถุประสงค์และวิธีการ: เปรียบเทียบลักษณะแสดงบนจอตาของ CNV จากโรค AMD กับโรค PCV เพื่อหาความเสี่ยงสัมพัทธ์ของการเป็นโรค PCV จากลักษณะดังกล่าว ด้วยการคำนวณค่า odds ratio, ความไว (sensitivity) และความจำเพาะ (specificity)

ผลการศึกษา: มีผู้ป่วยทั้งหมด 30 ราย เป็นผู้ได้รับการวินิจฉัยว่าเป็นโรค PCV 15 ราย และไม่เป็นโรค PCV 15 ราย ผู้ป่วยทั้งสองกลุ่มอยู่ในกลุ่มอายุเดียวกัน และได้รับการยืนยันการวินิจฉัยด้วยการตรวจ indocyanine green angiography (ICG) ค่า odds ratio สูงสุดเมื่อจอตามีลักษณะของ polyp-like ได้จอประสาทตา และมีค่าต่ำสุด เมื่อมี scar ซึ่งเท่ากับ 28 และ 0 ตามลำดับและมีนัยสำคัญทางสถิติ ($p = 0.001$ และ 0.032) ค่า odds ratio มีค่าเท่ากันเมื่อจอตามีลักษณะ circinate exudates, subretinal fluid และ retinal pigment epithelial detachment ขนาดมากกว่า 4 disc area ซึ่งเท่ากับ 1.75 ค่า odds ratio เท่ากับ 1.63 เมื่อพยาธิสภาพอยู่ที่ peripapillary สำหรับลักษณะของ subretinal membrane มีค่า odds ratio เท่ากับ 1 ส่วน subretinal hemorrhage และ subretinal fibrin มีค่าน้อยกว่า 1 คือเท่ากับ 0.31 และ 0.23 ตามลำดับ ค่า odds ratio ทั้งหมดนี้ไม่มีนัยสำคัญทางสถิติ

สรุป: ลักษณะ polyp ได้จอตามีความสำคัญมากในการวินิจฉัยโรค PCV นอกจากนี้ หากพบลักษณะ serousanguinous retinopathy กล่าวคือ พบ serous retinal detachment หรือ retinal pigment epithelial detachment ร่วมกับ circinate exudates ซึ่งอาจมีหรือไม่มี subretinal hemorrhage บริเวณ posterior pole หรือ peripapillary ก็น่าจะบ่งถึงโรคนี้ด้วย
