

Pseudophakic Retinal Detachment with Ruptured Posterior Lens Capsule

Apichart Singalavanija MD*,
Ornhathai Thongbun MD*, Sasima Tongsai MSc*

* Department of Ophthalmology, Faculty of Medicine Siriraj Hospital, Mahidol University

The relationship between retinal detachment and posterior lens capsule rupture in pseudophakic patients was studied. Records of patients with pseudophakic retinal detachment who were admitted to Siriraj Hospital from 1992 to 2004 were reviewed. The patients were divided into 2 main groups: 1) The study group (pseudophakic retinal detachment) 79 eyes (78 cases) which was subdivided into group 1a) pseudophakic retinal detachment with intact posterior lens capsule (50 eyes), and group 1b) pseudophakic retinal detachment with ruptured posterior lens capsule (29 eyes); 2) The control group 99 eyes (90 cases) which was subdivided into group 2a) pseudophakic patients with intact posterior lens capsule (83 eyes), and group 2b) pseudophakic patients with ruptured posterior lens capsule (16 eyes). The relationship between pseudophakic retinal detachment and posterior lens capsule rupture was analyzed by Chi-square test, and risk factors were analyzed by multiple logistic regression. Retinal detachment in pseudophakic patients was found more often in males more than in females, and the average age was 57.9 ± 11.8 years, the retinal detachment was related to posterior lens capsule rupture ($p = 0.003$). Patients with pseudophakic retinal detachment with a ruptured posterior lens capsule had a risk 5.7 times greater than pseudophakic patients with an intact posterior lens capsule (adjusted Odds ratio = 5.716, 95%CI = 2.118-15.427).

The present study showed that posterior lens capsule rupture increased the risk of retinal detachment. Ophthalmologists should be aware of retinal detachment development after YAG capsulotomy, especially in patients who have other risk factors such as myopia, lattice degeneration, retinal break, or previous retinal detachment surgery.

Keywords: Pseudophakic retinal detachment, Lens capsule rupture, Capsulotomy

J Med Assoc Thai 2005; 88 (Suppl 9): S37-42

Full text. e-Journal: <http://www.medassocthai.org/journal>

Retinal detachment is one of the causes of blindness. It is a serious complication of cataract surgery. The risk factors of retinal detachment include myopia, retinal degeneration, retinal tears, eye injury and previous cataract surgery. The retinal detachment after extracapsular cataract extraction was reported to range from 0.02-3.6%⁽¹⁻³⁾ and after phacoemulsification from 0.8-1.17%⁽⁴⁻⁶⁾. After cataract surgery and Neodymium: YAG capsulotomy, the incidence of retinal detachment was 0.8-3.6%⁽⁷⁻¹¹⁾. Retinal detachment seemed to be found more frequently in patients after cataract surgery with ruptured lens capsules.

Correspondence to : Singalavanija A, Department of Ophthalmology, Siriraj Hospital, 2 Prannok Rd, Bangkok 10700, Thailand. Phone: 0-2411-2006, Fax: 0-2411-1906. E-mail: siasn@mahidol.ac.th

The authors studied the characteristics of retinal detachment in patients with intraocular lenses (pseudophakic retinal detachment) with and without ruptured posterior lens capsules, and also the correlation between retinal detachment and the status of the posterior lens capsule.

Material and Method

A retrospective study of patients with pseudophakic retinal detachment who were admitted to Siriraj Hospital from June, 1992 to May, 2004 was performed. The patients were divided into 2 major groups:

1) Study group: pseudophakic retinal detachment 79 eyes (78 cases) which was subdivided into group 1a) pseudophakic retinal detachment with intact posterior lens capsule (50 eyes), and group

1b) pseudophakic retinal detachment with ruptured posterior lens capsule (29 eyes).

2) Control group: 99 eyes (90 cases) which was subdivided into group 2a) pseudophakic patients with intact posterior lens capsule (83 eyes), and group 2b) pseudophakic patients with ruptured posterior lens capsule (16 eyes) (Diagram 1).

In the study group, the authors included only pseudophakic retinal detachment. The status of the lens capsule was recorded as intact or ruptured. Lens capsule rupture occurred while performing cataract surgery or after YAG capsulotomy. The duration from lens capsule rupture to retinal detachment development, area of retinal detachment, location of retinal tears, and associated factors for retinal detachment development such as myopia, retinal degeneration, and previous retinal detachment surgery were recorded. The visual acuity and status of retinal reattachment were reviewed and analyzed. In the present study the authors excluded cases of retinal detachment caused by injuries and those with a history of previous injury.

The control group was composed of patients who underwent cataract surgery and had normal fundi postoperatively. Patients were chosen by simple random sampling. Cataract surgery was performed more than 3 months. The status of the lens capsule and risk factors for retinal detachment were recorded.

All data was recorded in SPSS for Windows Version 10.0. The differences in categorical variables

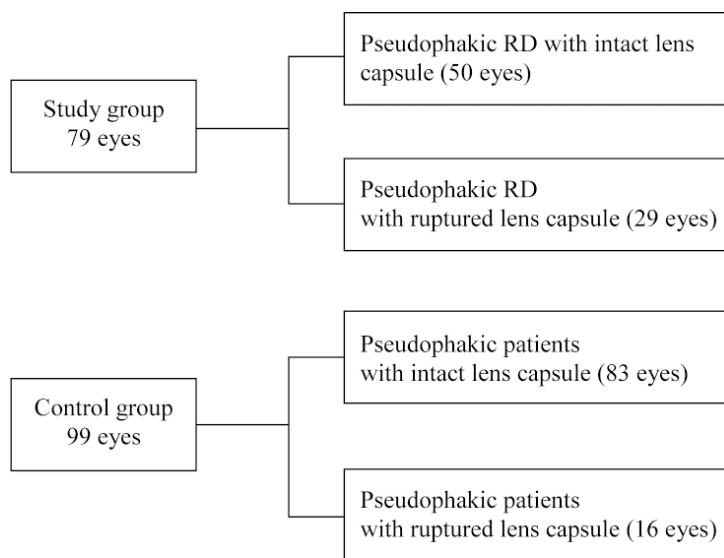
between pseudophakic retinal detachment in the group with intact posterior lens capsules and ruptured posterior lens capsules were compared and analyzed using Chi-square and Student t-tests. The risk factors between pseudophakic retinal detachment and control group were analyzed by logistic multivariate regression analysis and reported by Odds ratios. A p-value of less than 0.05 was considered to be statistical significance

Results

The study of pseudophakic retinal detachment with intact versus ruptured posterior lens capsules

There were a total of 78 cases (79 eyes) of patients with pseudophakic retinal detachment: 57 males (57 eyes), 21 females (22 eyes), average age was 57.9 ± 13.8 years. The patients had an intact lens capsule in 50 eyes and ruptured lens capsule in 29 eyes (Diagram 1).

A) Pseudophakic patients with ruptured lens capsules. There were 17 males (17 eyes) and 11 females (12 eyes). Average age was 57.9 ± 11.8 years. There were 13 eyes (44.8%) with a ruptured lens capsule that developed retinal detachment at 3 months or less after cataract surgery, and 16 eyes (55.2%) after 3 months. Retinal tears were found in 14 of 29 eyes (49.3%). Tears were found in the superior quadrant in 8 eyes and inferior quadrant in 4 eyes. Macular holes were found in 2 eyes. Patients underwent encircling scleral buckling



RD = retinal detachment

Diagram 1. Shows study group and control group

and vitrectomy in 28 eyes, and encircling in 1 eye. In the present group 13 eyes had internal tamponade by sulfur hexafluoride (SF₆) gas and 2 eyes had perfluoropropane (C₃F₈) gas injection.

The visual acuity before operation was 6/60 or better in 11 eyes (37.9%) and 3/60 - hand motion in 18 eyes (62.1%). After the operation, the retina was attached in 24 eyes (82.8%). The best-corrected visual acuity after operation was 6/60 or better in 20 eyes (69%), 3/60 - hand motion in 7 eyes (24.1%), and light projection in 2 eyes (6.9%). Average follow up was 6.5 ± 5.1 weeks.

B) Pseudophakic retinal detachment with intact posterior lens capsules. There were 40 males (40 eyes) and 10 females (10 eyes). Average age was 57.3 ± 15.1 years. Retinal tears were found in 32 eyes (64%). Tears were located in the superior quadrant in 16 eyes, inferior quadrant in 13 eyes and macular holes were found in 3 eyes. The operative procedures were encircling scleral buckling and vitrectomy in 42 eyes, pars plana vitrectomy in 5 eyes, encircling scleral buckling in 2 eyes, and segmental buckling in 1 eye. Internal tamponade was performed with SF₆ gas injection in 25 eyes, C₃F₈ gas injection in 2 eyes, and silicone oil injection in 1 eye.

After the operation, the retina was attached in 35 eyes (70%). The visual acuity before operation

was 6/60 or better in 16 eyes (32%) and 5/60 - light perception in 34 eyes (68%). The best-corrected visual acuity after operation was 6/60 or better in 30 eyes (60%), 5/60 - light perception 20 eyes (40%). Average follow up was 7.5 ± 6.2 weeks.

When the variables between pseudophakic retinal detachment with intact posterior lens capsule and ruptured lens capsule were compared, variables such as age, sex, myopia, retinal degeneration, retinal detachment in the fellow eye, previous retinal detachment in the same eye, postoperative visual acuity, and attachment rate, showed no statistically significant difference between the two groups (Table 2).

The study of risk factors between pseudophakic retinal detachment and control group

The control group consisted of patients with normal fundi after cataract surgery: 38 males (39 eyes) and 52 females (60 eyes). The average age was 70.2 ± 8.6 years. Patients had an intact lens capsule in 83 eyes and ruptured lens capsule in 16 eyes. In this control group, 5 eyes were myopic, 8 eyes had retinal degeneration in the same eye, 2 eyes had retinal tears in the fellow eye, and 4 eyes had retinal detachment in the fellow eye.

When the pseudophakic retinal detachment and control groups were compared, the risk factors of

Table 1. Characteristics of pseudophakic RD with intact and ruptured posterior lens capsule

		RD with intact P/C (eyes)	RD with ruptured P/C (eyes)
Age in years (mean ± SD)		57.3±15.1	57.9±11.8
Sex	Male	40 (80%)	17 (58.6%)
	female	10 (20%)	12 (41.4%)
Duration of P/C rupture	≤ 3 months	-	13 (44.8%)
	> 3 months	-	16 (55.2%)
Position of retinal tear	Superior quadrant	16 (32%)	8 (27.5%)
	Inferior quadrant	13 (26%)	4 (13.7%)
	Macular hole	3 (6%)	2 (6.9%)
	No tear	18 (36%)	15 (51.7%)
Operation	Scleral buckling with PPV	42 (84%)	28 (96.6%)
	Scleral buckling	3 (6%)	1 (3.4%)
	Primary PPV	5 (10%)	0 (0%)
Operative result	Retinal attachment	35 (70%)	24 (82.8%)

RD = Retinal detachment

P/C = Posterior lens capsule

PPV = Pars plana vitrectomy

retinal detachment were analyzed by univariate analysis. The authors found that age, sex, previous retinal detachment in the same eye, and lens capsule rupture showed statistically significant difference (Table 3). Pseudophakic retinal detachment was found more often in the younger age group, and was more common in males than in females.

When the authors analyzed the data by logistic multivariate analysis, by age and sex adjustment, the results showed that the only risk factor for retinal detachment that showed a statistically significant

difference was the status of the lens capsule (Table 4). Patients with a ruptured lens capsule had a risk of retinal detachment 5.7 times higher than those with an intact lens capsule (adjusted Odds ratio = 5.716, CI2.118-15.427).

Discussion

The incidence of retinal detachment after cataract surgery has been estimated to range between 0.6 and 1.7%, compared to 0.006-0.01% in the general population⁽¹²⁾. It was found that risk factors for retinal

Table 2. Risk variables of pseudophakic RD

Variables	RD with intact P/C (50 eyes)	RD with ruptured P/C (29 eyes)	p-value
Age in years	57.3±15.1	57.9±11.8	0.636
Myopia	3 (6%)	2 (6.9%)	1.000
Retinal degeneration	5 (2%)	3 (10.3%)	1.000
Retinal degeneration in fellow eye	2 (4%)	2 (6.9%)	0.622
Retinal detachment in the same eye	4 (8%)	2 (6.9%)	1.000
Retinal detachment in the fellow eye	2 (4%)	2 (6.9%)	0.622
Preoperative VA(VA better than 6/60)	16 (32%)	11 (37.9%)	0.772
Postoperative VA(VA better than 6/60)	30 (60%)	20 (69%)	0.278
Postoperative retinal attachment	35 (70%)	24 (82.8%)	0.340

RD = Retinal detachment P/C = Posterior lens capsule VA = Visual acuity

Table 3. Demographic data of pseudophakic RD and control group

Variables	Pseudophakic RD (79 eyes)	Pseudophakic patients (99 eyes)	p-value
Myopia	5 (6.3%)	5 (5.2%)	0.756
Retinal degeneration in the same eye	8 (10.1%)	4 (4.2%)	0.218
Retinal tear in the fellow eye	2 (2.6%)	2 (2.2%)	1.000
Previous RD in the same eye	6 (7.6%)	0	0.005
RD in the fellow eye	4 (5.1%)	4 (4.2%)	1.000
Capsule status			
Ruptured	29 (36.7%)	16 (16.2%)	0.003
Patent	50 (63.3%)	83 (83.8%)	
	Pseudophakic RD	Pseudophakic patients	
Age			
Mean ± SD (years)	57.9±13.8	70.3±8.6	<0.001
Median (min, max)	60 (28, 85)	70 (42, 90)	
Sex			
Male (cases)	57 (73.1%)	38 (42.2%)	<0.001
Female (cases)	21 (26.9%)	52 (57.8%)	

RD = Retinal detachment

Table 4. Risk analysis

Variables	Crude Odds Ratio (95%CI)	Adjusted Odds Ratio (age, sex)
Myopia	1.230 (0.343-4.410)	1.545 (0.264-9.027)
Retinal tear in the fellow eye	1.145 (0.157-8.324)	2.146 (0.171-26.889)
Retinal degeneration	2.563 (0.742-8.855)	3.271 (0.547-19.570)
RD in the fellow eye	1.213 (0.294-5.016)	1.821 (0.224-14.791)
Ruptured posterior lens capsule	3.009 (1.488-6.083)	5.716 (2.118-15.427)

RD = Retinal detachment

detachment after intraocular lens implantation included myopia with axial lengths longer than 25 millimeters, lattice degeneration, retinal detachment in the fellow eye, and post YAG capsulotomy^(2,13-15). Pseudophakic retinal detachment was usually found more often in males and in the younger age group when the group of patients who received cataract surgery was compared. It was supposed that in the young, the vitreous is firmly attached around the ora serrata, and vitreous traction causes retinal detachment⁽²⁾.

It is believed that the vitreous is the most important factor related to retinal detachment. After cataract extraction the level of hyaluronic acid, which is the main component of vitreous gel, is decreased. Liquefaction of vitreous, vitreous detachment and subsequent vitreous traction can occur. Finally, the traction causes a retinal tear and retinal detachment⁽¹⁵⁾.

Previous studies showed that the retinal detachment usually occurred within the first year after the capsulotomy^(16,17). In the present study the authors found that 44 percent of the patients had the retinal detachment within 3 months after posterior lens capsule rupture. The clinical characteristics of pseudophakic retinal detachment in the group with intact lens capsule and ruptured lens capsule was not statistically significant difference.

The incidence of retinal detachment in pseudophakic patients was higher in males than females, and also in the younger age group. The risk factors for retinal detachment development which showed statistical significant difference between the pseudophakic retinal detachment group and the control group were previous retinal detachment in the same eye and ruptured posterior lens capsule. Javitt JC et al reported the risk of retinal detachment in vitreous loss and Neodymium:YAG laser capsulotomy after cataract surgery. The vitreous loss concomitant with anterior vitrectomy was associated with a 4.5 fold in increased

incidence of retinal detachment⁽⁵⁾. The risk of retinal break or retinal detachment among extracapsular cataract patients who underwent Neodymium:YAG laser capsulotomy was increased 3.9 fold⁽¹⁴⁾. In the present study, by multivariate analysis with age and sex adjustment the authors found that a patient with a ruptured posterior lens capsule had a risk of retinal detachment 5.3 times greater than a patient with an intact lens capsule. After cataract surgery, patients who plan to receive lens capsulotomy should have a peripheral fundus examination. Ophthalmologists should be aware of possible retinal detachment in patients who have other associated risk factors such as myopia, lattice degeneration, retinal break, or previous retinal detachment surgery.

References

1. Kratz RP. Complications associated with posterior chamber lenses. *Ophthalmology* 1979; 86: 659-61.
2. Smith PW, Stark WJ, Maumenee AE, Enger CL, Michels RG, Glaser BM, et al. Retinal detachment after extracapsular cataract extraction with posterior chamber intraocular lens. *Ophthalmology* 1987; 94: 495-504.
3. Coonan P, Fung WE, Webster RG, Allen AW, Abbot RL. The incidence of retinal detachment following extracapsular cataract extraction; a ten-year study. *Ophthalmology* 1985; 92: 1096-101.
4. Wilkinson CP, Anderson LS, Little JH. Retinal detachment following phacoemulsification. *Ophthalmology* 1978; 85: 151-6
5. Javitt JC, Vitale S, Canner JK, Krakauer H, McBean AM, Sommer A, et al. National outcomes of cataract extraction I. Retinal detachment after inpatient surgery. *Ophthalmology* 1991; 98: 895-902.
6. Olsen GM, Olsen RJ. Cataract surgery, capsulotomy, and retinal detachment; a prospective study. *J Cataract Refract Surg* 1995; 21: 136-9.
7. Van Westenbrugge JA, Gimbel HV, Soucek J,

- Chow D. Incidence of retinal detachment following Nd: YAG capsulotomy after cataract surgery. J Cataract Refract Surg 1992; 18: 352-5.
8. Koch DD, Liu JF, Gill EP, Parke DW II. Axial myopia increases the risk of retinal complications after neodymium-YAG laser posterior capsulotomy. Arch Ophthalmol 1989; 107: 986-90.
 9. Powel SK, Olson RJ. Incidence of retinal detachment after cataract surgery and Neodymium:YAG laser capsulotomy. J Cataract Refract Surg 1995; 21: 132-5.
 10. Dardenne MU, Gerten GJ, Kohleas K, Kermani O. Retrospective study of retinal detachment following Nd-YAG laser posterior capsulotomy. J Cataract Refract Surg 1989; 15: 676-80.
 11. Olsen G, Olsen RJ. Update on a long-term, prospective study of capsulotomy and retinal detachment rates after cataract surgery. J Cataract Refract Surg 2000; 26: 1017-21.
 12. Lois N, Wong P. Pseudophakic retinal detachment. Surv Ophthalmol 2003; 48: 467-87.
 13. Tielsch JM, Iegro MW, Cassard SD, Schein OD, Javitt JC, Singer AE, et al. Risk factors for retinal detachment after cataract surgery. Ophthalmology 1996; 103: 1537-45.
 14. Javitt JC, Tielsch JM, Canner JK, Kolb MM, Sommer A, Steinberg EP. National outcomes of cataract extraction. Increased risk of retinal complications associated with Nd:YAG laser capsulotomy. The Cataract Patient Outcomes Research Team. Ophthalmology 1992; 99: 1487-98.
 15. Oliver S. Pseudophakic retinal detachment. Techniques in Ophthalmol 2004; 2: 55-9.
 16. Rickman-Barger L, Florine CW, Larson RS, Lindstrom RL. Retinal detachment after neodymium: YAG laser posterior capsulotomy. Am J Ophthalmol 1989; 107: 531-6.
 17. Salvesen S, Eide N, Syrdalen P. Retinal detachment after YAG capsulotomy. Acta Ophthalmol (Copenh) 1991; 69: 61-4.

จอประสาทตาลอกภายหลังการผ่าตัดต้อกระจกร่วมกับภาวะถุงหุ้มเลนส์ฉีกขาด

อภิชาติ สิงคาลวณิช, อรหทัย ทองบุญ, ศศิมา ทองสาย

ได้ทำการศึกษาผู้ป่วยที่มีจอประสาทตาลอกหลังผ่าตัดต้อกระจกและใส่เลนส์เทียม ศึกษความสัมพันธ์ระหว่างการเกิดจอประสาทตาลอกกับภาวะถุงหุ้มเลนส์ฉีกขาด โดยศึกษาย้อนหลังจากข้อมูลของผู้ป่วยที่มารับการรักษา ณ ภาควิชาจักษุวิทยา โรงพยาบาลศิริราช ตั้งแต่ปี พ.ศ. 2535-2547 โดยแบ่งผู้ป่วยเป็น 2 กลุ่ม กลุ่มแรกเป็นกลุ่มผู้ป่วยที่มีจอประสาทตาลอก และใส่เลนส์เทียม 79 ตา (78 คน) ซึ่งเป็นผู้ป่วยจอประสาทตาลอกโดยมีถุงหุ้มเลนส์ปกติ 50 ตา และจอประสาทตาลอกที่มีถุงหุ้มเลนส์ฉีกขาด 29 ตา กลุ่มที่สองเป็นกลุ่มผู้ป่วยที่มีจอประสาทตาปกติ และใส่เลนส์เทียม 99 ตา (90 ราย) ซึ่งประกอบด้วย ผู้ป่วยหลังผ่าตัดต้อกระจกที่มีถุงหุ้มเลนส์ปกติ 83 ตา และถุงหุ้มเลนส์ฉีกขาด 16 ตา

พบว่าจอประสาทตาลอกในผู้ป่วยที่ใส่เลนส์เทียม พบในชายมากกว่าหญิง มีอายุเฉลี่ย 57.9 ± 11.8 ปี ปัจจัยที่มีผลต่อการเกิดจอประสาทตาลอก ได้แก่ ภาวะการฉีกขาดของถุงหุ้มเลนส์ ผู้ป่วยหลังผ่าตัดต้อกระจกที่มีถุงหุ้มเลนส์ฉีกขาดมีความเสี่ยงต่อการเกิดจอประสาทตาลอกมากกว่าผู้ป่วยที่มีถุงหุ้มเลนส์ปกติ 5.7 เท่า (adjusted Odds ratio = 5.716, 95%CI = 2.118-15.427) ดังนั้นการทำ YAG capsulotomy ในผู้ป่วยหลังผ่าตัดต้อกระจกที่มีปัจจัยเสี่ยงอื่นๆ ร่วมด้วย เช่น สายตาสั้นมาก จอประสาทตาเสื่อม การเคยได้รับการผ่าตัดจอประสาทตาลอกมาก่อน จึงต้องระวังการเกิดจอประสาทตาลอกในภายหลัง