

## Case Report

# Median Nerve Palsy after Operative Treatment of Olecranon Fracture

Ekamol Thumroj, MD\*,  
Surut Jianmongkol, MD\*, Jureerut Thammaroj, MD\*\*

\* Department of Orthopedic Surgery, Khon Kaen University, Khon Kaen

\*\* Department of Radiology, Khon Kaen University, Khon Kaen

---

*Olecranon fracture is not an uncommon fracture in clinical practice. Simple olecranon fracture usually heals quite well without any types of iatrogenic complications. Despite close proximity of the fracture to the nerve, median nerve palsy after operative treatment of olecranon fracture is a rare complication. To the authors' knowledge, this complication has not been previously reported in the Thai or English literature. The authors present a patient who had median nerve palsy after tension-band wiring for olecranon fixation. Intraoperative finding revealed that the median nerve was injured by the tip of K-wire. While this complication is uncommon on a per-person basis, it may result in serious complication, such as nerve palsy or limb ischemia. Orthopedic surgeons must remain vigilant with regard to any type of internal fixation in the upper extremity because the risk of neurovascular injury is high.*

**Keywords:** Nerve, Olecranon fracture, Fixation

**J Med Assoc Thai 2005; 88 (10): 1434-7**

**Full text. e-Journal:** <http://www.medassocthai.org/journal>

---

Median nerve palsy after operative treatment of olecranon fracture is a rare complication. To the authors' knowledge, this complication has not been reported in the Thai or English literature. In the present day, increasing malpractice premium continue to endanger the practice of orthopedic surgeons to practice medicine in Thailand. However, there is little information that can accurately assist surgeons in minimizing the risk of a malpractice claim. The authors present a case of a patient who suffered from median nerve palsy after operative treatment of olecranon fracture. The patient was informed that data concerning his case would be submitted for publication.

### Case Report

A twenty-one-year-old man sustained a left olecranon fracture from the knife of the opponents during a quarrel. He was admitted to the nearest hospital with open olecranon fracture. Open reduction and internal fixation with tension-band wiring was performed

eight hours after the injury. Long arm cast was used postoperatively for one month. Two weeks after the operation, the patient came to the hospital and complained about the numbness of his left hand. One month after the operation, the long arm cast was taken off and active-assisted range-of-motion exercises were started. The patient still complained about numbness of the hand and weakness of hand grip. The doctor told him that there was one nerve palsy and suggested observation.

The patient came to our orthopedic clinic one year after the injury. Physical examination demonstrated no tenderness to palpation of the olecranon. Neurological evaluation revealed the decreased sensation to pinprick along the radial side of the left hand. The patient had atrophy of the thenar muscle and could not perform the opposition as Fig. 1. Tinel sign was positive at the volar site of the proximal forearm. Peripheral pulse was presented.

Plain radiographs of the right elbow revealed a healed fracture of olecranon and protrusion of Kirchner wire (K-wire) through the volar cortex of ulna as in Fig. 2. Electrodiagnosis revealed the median nerve palsy at 1 the elbow level.

---

Correspondence to : Thumroj E, Department of Orthopedics, Faculty of Medicine, Khon Kaen University, Khon Kaen 40002, Thailand. Phone: 0-4334-8360 ext. 4070, Fax: 0-4334-8398, E-mail: tekamo@kku.ac.th

The patient underwent exploration of the median nerve before removal of the K-wire was done. Intraoperative finding demonstrated K-wire protrusion through the median nerve as in Fig. 3. There was fibrosis around the median nerve and ulnar artery. Median nerve was gently elevated from the tip of the K-wire and protected between removal of the K-wire. External fibrolysis was done for median nerve and ulnar artery to free them from the surrounding fibrosis. Six months after the surgery, the patient had gained some grip strength. There was progression of the Tinel sign to the mid-forearm.

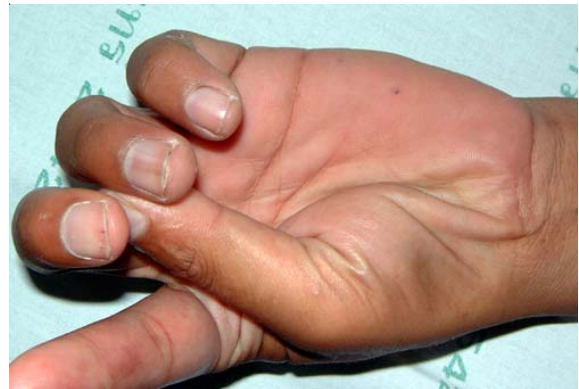### Discussion

Displaced fracture of olecranon is still the indication for operative fixation. Tension-band wiring is usually the best internal fixation construct to use in these fractures<sup>(1)</sup>. Traditionally, K-wire has been used in the tension-band construct except for some large olecranon fragments, a long screw can be used in place of the K-wire.

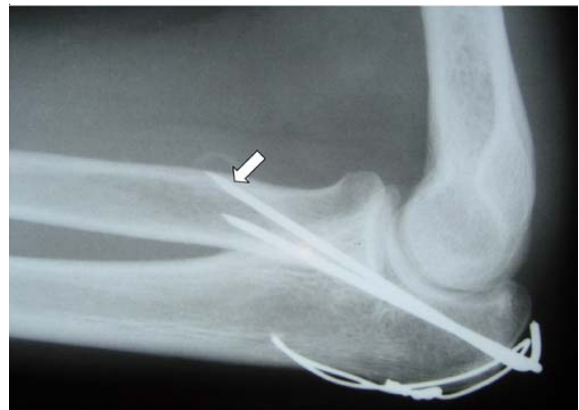Complications of operative treatment of olecranon are not uncommon<sup>(2-4)</sup>. Symptomatic hardware has been reported in up to 80% of patients and may require removal after the fracture is solidly healed<sup>(5)</sup>. However, the neurological complications from this injury are rare. Ulnar nerve symptoms have been reported in 10% of patients<sup>(6)</sup>. To the authors' knowledge, median nerve palsy from the operative treatment of olecranon has not been reported.

The olecranon process is a large curved eminence comprising the proximal and posterior portion of the ulna. There are median, ulnar and radial nerves surrounding the olecranon. Because of the close proximity of ulnar nerve to the medial cortex of olecranon, it has the highest incidence of neurological complications in olecranon fracture. The median and radial nerve seems to be less vulnerable. The median nerve descends anterior to the volar cortex of the proximal ulna as in figure 4. In this area, it lies between the flexor digitorum profundus and the flexor digitorum superficialis muscle. The data of the pilot study from our anatomy laboratory revealed that the average distance from the median nerve to the volar cortex of olecranon is 8 mm. To reduce the risk of neurovascular injuries after operative treatment of olecranon fracture, surgeons have to pay attention to the protrusion of K-wire or screws through the volar cortex of the proximal ulna.

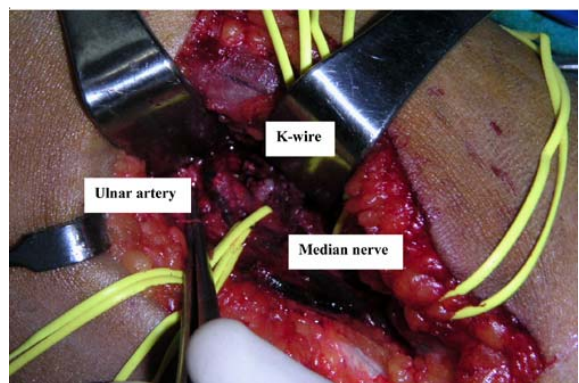
Although the median nerve palsy from the internal fixation of olecranon is rare, a missed or



**Fig. 1** Picture of the left hand reveals atrophy of the thenar muscle. The patient can not perform the opposition

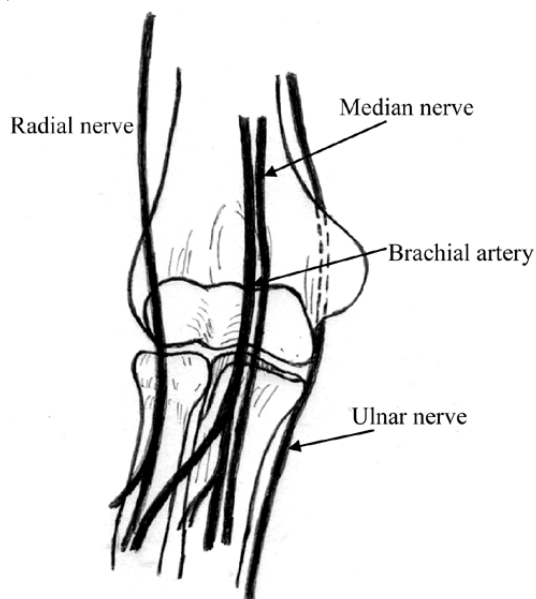


**Fig. 2** Plain radiograph shows the protrusion of K-wires through the volar surface of the ulnar cortex (arrow)



**Fig. 3** An Intraoperative view, tip of K-wire penetrated through the median nerve

delayed diagnosis can be problematic in that it can result not only in delayed surgical decompression but also in increasing malpractice claims. The authors can



**Fig. 4** Schematic diagram shows median, ulnar and radial nerves surrounding the elbow. Median nerve and ulnar artery pass anterior to the volar cortex of the proximal ulna

not assure that this complication is iatrogenic or a by chance event but the modern clinical practice is further clouded by the medical-legal conundrum. While malpractice risk management is of prime importance to practicing orthopedic surgeons, few scientific data are available on strategies to reduce the risk of a malpractice claim.

In conclusion, while neurovascular injuries from K-wire protrusion of operative treatment of olecranon fracture are uncommon on a per-person basis, these may result in serious complications for the patient, such as nerve palsy or limb ischemia. Orthopedic surgeons must remain vigilant with regard to any types of fixation in the upper extremity because the risk of neurovascular injury is high.

#### References

1. Mezera K, Hotchkin RN. Fractures and dislocations of the elbow. In: Bucholz RW, Heckman JD, editors. Rockwood and Green's Fracture in adults. 5<sup>th</sup> ed. Philadelphia:Lippincott-Raven publishers 2001:921-52.
2. Finalyson D. Complications of tension-band wiring of olecranon fracture (letter). *J Bone Joint Surg* 1986; 68A: 951-2.
3. Rowland SA, Burkhalter SS. Tension band wiring of olecranon fracture-a modification of the AO technique. *Clin Orthop* 1992; 227: 238-42.
4. Wolfgang G, Burke F, Bush D, Parenti J, Perry J, LaFollette B, et al. Surgical treatment of displaced olecranon fractures by tension band wiring technique. *Clin Orthop* 1987; 224: 192-204.
5. Matthewson MH, McCreath SW. Tension band wiring in the treatment of olecranon fractures. *J Bone Joint Surg* 1975; 57: 399.
6. Macko D, Szabo RM. Complications of tension-band wiring of olecranon fractures. *J Bone Joint Surg* 1985; 67: 1396-401.

---

## การบาดเจ็บของเส้นประสาทมีเดียนหลังการผ่าตัดรักษากระดูก olecranon หัก

เอกกมล ธรรมโรจน์, สุรัตน์ เจียรณมงคล, จุรีรัตน์ ธรรมโรจน์

กระดูก olecranon หักพบได้พอสมควรในทางคลินิก ถ้าเป็นกระดูก olecranon หักชนิดธรรมดาผลการรักษาจะค่อนข้างดีโดยไม่มีภาวะแทรกซ้อนจากการรักษา แม้ว่าตำแหน่งรอยหักของกระดูกนี้จะมีเส้นประสาทอยู่ใกล้แต่ภัยอันตรายต่อเส้นประสาทโดยเฉพาะเส้นประสาทมีเดียนจากการผ่าตัดยึดตรึงกระดูกหักกลับพบน้อยมากจากการทบทวนวรรณกรรมยังไม่พบรายงานผู้ป่วยที่เกิดภัยอันตรายต่อเส้นประสาทนี้จากการผ่าตัดยึดตรึงกระดูกทั้งในวารสารภาษาไทยและภาษาอังกฤษ รายงานผู้ป่วยนี้ได้นำเสนอกรณีผู้ป่วยที่เกิดภัยอันตรายต่อเส้นประสาทมีเดียนจากการใช้ลวดยึดตรึงกระดูกเพื่อรักษากระดูก olecranon หัก ผลที่พบในระหว่างการผ่าตัดคือ ปลายของลวดยึดตรึงกระดูกได้ทิ่มทะลุโดนเส้นประสาทมีเดียน แม้ว่าภาวะแทรกซ้อนรูปแบบนี้จะพบน้อย แต่ก็ทำให้เกิดภาวะแทรกซ้อนที่รุนแรง เช่น การสูญเสียการทำงานของเส้นประสาท หรือปลายแขนตายจากการขาดเลือด ศัลยแพทย์ออร์โธปิดิกส์ควรให้ความสนใจและระมัดระวังทุกครั้งที่ทำกรผ่าตัดยึดตรึงกระดูกกระยางค์บนหัก เพราะมีความเสี่ยงสูงต่อการเกิดภัยอันตรายต่อเส้นเลือดและเส้นประสาท

---