

Significance of Lead aVR ST Segment Elevation in Acute Coronary Syndrome

Kriengkrai Hengrussamee, MD*,
Wirash Kehasukcharoen, MD*, Sudaratana Tansuphaswadikul, MD*

* Cardiac Unit, Chest Disease Intitute, Nonthaburi

Objectives: To study the relation between lead aVR ST segment elevation (aVRSTE) and angiographic coronary artery lesions in patients with acute coronary syndrome (ACS).

Material and Method: From January 2001 to December 2001, the authors retrospectively studied 26 consecutive patients who were admitted to the coronary care unit, Chest disease Institute with ACS. The admission 12-lead EKGs, chest X-ray, troponin T, creatine phosphokinase (CPK), creatine kinase MB fraction (CK MB) and blood chemistry including fasting blood sugar, renal function test (BUN and creatinine), electrolytes and lipid profiles were obtained and analyzed before coronary angiogram. CAG was performed in all within 48 hours after admission. The admission 12-lead EKGs and angiographic coronary artery lesions were analyzed.

Results: There were 26 patients (M:F = 21:5) with a mean age of 64 ± 9 yr. The culprit lesions were located at the left main coronary artery (LM) in 5 (19%), the left anterior descending artery (LAD) in 8 (31%), the right coronary artery (RCA) in 11 (42%) and the left circumflex artery (LCX) in 2 (8%). Of these, aVRSTE (> 0.1 mV) was detected in 9 (35%), 4 in the LM group (80%), 3 in the RCA group (27%) and 2 in the LAD group (25%). The findings of aVRSTE distinguished the LM group from the non LM group (LAD, RCA and LCX), with 80% sensitivity, 76% specificity and 77% accuracy.

Conclusion: In patients with acute coronary syndrome, lead AVR ST segment elevation is associated with the culprit left main coronary lesion.

Keywords: Lead aVR ST segment evaluation (aVRSTE), Acute coronary syndrome (ACS), Electrocardiography (ECG)

J Med Assoc Thai 2005; 88 (10): 1382-7

Full text. e-Journal: <http://www.medassocthai.org/journal>

Acute coronary syndrome (ACS) consists of acute ST elevation myocardial infarction (STEMI), acute non-ST elevation myocardial infarction (NSTEMI) and unstable angina (UAP). The electro-cardiogram (ECG) is sensitive and valuable for detecting ACS. It showed ST elevation in patients with acute STEMI and horizontal ST depression in those with acute NSTEMI and UAP. However lead aVR is a mostly ignored but very valuable lead in ACS^(1,3,11). It represents abnormalities of the right upper side of the heart (right ventricular outflow tract) and basal part of the interventricular septum. Lead aVR can inform reciprocal changes from

the left lateral side covered by lead aVL, II, V₅ and V₆^(1,2). ST segment elevation in lead aVR determined myocardial ischemia or infarction of the basal part of the interventricular septum and culprit coronary lesions in patients with acute coronary syndrome (ACS). Those lesions are acute left main occlusion⁽³⁾, proximal left anterior descending artery occlusion⁽⁴⁾ and 3-vessel coronary artery disease⁽⁵⁾.

Objectives

The authors' aim was to study the relation between lead aVR ST segment elevation and angiographic coronary artery lesions in patients with ACS.

Type of study

Retrospective.

Correspondence to : Hengrussamee K, Department of Cardiology, Chest Disease Intitute, 39 Mu 9 Tiwanon Road, Nonthaburi, 11000, Thailand, Phone: 0-2580-6366 ext 7201, 7202, E-mail: cardiocc@cscoms.com

Material and Method

From January 2001 to December 2001, the authors studied 31 consecutive patients who were admitted to the coronary care unit, Chest Disease Institute with a diagnosis of ACS. The authors excluded 5 patients who died before coronary angiogram. There were another 12 patients who were admitted to the cardiac wards other than CCU and CAG was not performed on their admission. All 26 studied patients had the following investigations on admission including 12-lead EKGs, chest X-ray, troponin T, creatine phosphokinase (CPK), creatine kinase MB fraction (CK MB) and blood chemistry including fasting blood sugar, renal function test (BUN and creatinine), electrolytes and lipid profiles. CAG was performed in all within 48 hours after admission.

Definition

Acute coronary syndrome includes acute ST elevation myocardial infarction (STEMI), acute non-ST elevation myocardial infarction (NSTEMI) and unstable angina (UAP).

Culprit lesion⁽⁶⁾ was the coronary artery lesion which was totally occluded or showed severe stenosis (flow delay-TIMI flow grade 1 or local dissection or thrombosis or more than 75% stenosis). The authors categorized coronary artery culprit lesions to the left main group (LM), the left anterior descending group (LAD), the left circumflex group (LCX) and the right coronary group (RCA).

- ECG: The 12-lead EKGs recorded on admission were analyzed (averaged 5 consecutive beats) and ST segment elevation were measured.

- A ST segment deviation either elevation or depression was determined as the mean value of 5 consecutive beats measured at 60 milliseconds after the J point of the QRS complex. ST segment elevation was defined as present when ST segment elevation was >0.05 mV or 0.5 mm in the limb leads and aVR lead and ST segment elevation was >0.1 mV or 1 mm in the pre-cordial leads. Inter-observer and intra-observer differences were checked by using 12 randomized selected ECG tracings from 4 groups. Then measurements were performed by 2 cardiologists who did not know any angiographic findings.

Statistical and analysis

- Descriptive data were expressed as mean \pm SD

- The incidence of ST segment elevation in aVR and all leads were analyzed and compared between

LM group, LAD group and RCA group using univariate analysis, and the Fisher Exact test.

- The differences in ST segment elevation between lead aVR, lead aVL and V1 were examined and compared between LM group vs. LAD group and LM group vs. RCA group using one-way and two-way ANOVA test.

- At p value <0.05 was considered statistically significant.

Results

Patients' characteristics (Table 1)

There were 26 studied patients with the mean age around 64 years old, ranging from 46 to 77. Male was predominant. Diabetes mellitus and hypertension was found in 31% and 35%. Current cigarette smoking and family history of CVD was 24% and 19% respectively. 24% had hypercholesterolemia and 42% had LDL-C more than 100 mg/dl and HDL less than 40 mg/dl.

The culprit lesions were located at the left main coronary artery (LM) in 5 (19%), the left anterior descending artery (LAD) in 8 (31%), the right coronary artery (RCA) in 11 (42%) and the left circumflex artery in 2 (8%). Troponin T was positive (>0.1 mg/ml.) more in LM group (80%) than in the LAD (50%) and RCA group (45%). Intraaortic balloon pump was needed to support hemodynamics of the patients before coronary angiogram was performed in 20% of the LM group, 12.5% in the LAD group and 27% in the RCA group. Collateral arteries from the right coronary artery were found in 60% of the LM group and 37.5% of the LAD group and the left anterior descending artery gave

Table 1. Patients' characteristics

Characteristics (N = 26 case)	Value
Age (years)	64 \pm 9 (range 46-77)
Male:Female	21:5
DM (%)	8 (31)
HT (%)	9 (35)
Total cholesterol >200 mg/dl (%)	6 (24)
LDL-C >100 mg/dl (%)	11 (42)
HDL <40 mg/dl (%)	11 (42)
Current cigarette smokers (%)	6 (24)
Familial history of CVA and CVD death (%)	5 (19)
History of prior MI (%)	3 (12)
Prior history of ischemic heart disease	5 (19)
Mean time from onset to coronary angiogram (hours)	22.6

Table 2. Univariate analysis of the degree of ST segment elevation for distinguishing between the Left main coronary artery group (LM), the left anterior descending artery group (LAD) and the right coronary artery group (RCA)

ST segment shift	LM group (n = 5)	LAD group (n = 8)	RCA group (n = 11)	p value
Lead aVR (mV)	0.22 ± 0.20*	0.03 ± 0.08*	0.04 ± 0.07*	< 0.05*
Lead V ₁ (mV)	0.16 ± 0.11	0.09 ± 0.21	0.03 ± 0.06	NS
Lead aVR-V ₁ (mV)	0.06 ± 0.27	-0.06 ± 0.14	-0.02 ± 0.17	NS

collaterals to the right coronary artery in 63% of the RCA group (Table 2). The mean duration from the onset of ACS to CCU admission was 11.2 hours in the LM group, 12.5 hours in the LAD group, 37 hours in the RCA group and 10.8 hours in the LCX group.

Incidence of aVR ST segment elevation

The admission ECG revealed aVR ST segment elevation (>0.1 mV) in 9 (35%), 4 in the LM group (80% of the LM group and 44% of all positive aVR ST elevation), 3 in the RCA group (27% of the RCA group and 33% of all positive aVR ST elevation) and 2 in the LAD group (25% of the LAD group and 22% of all positive aVR ST elevation). The sensitivity and specificity of Lead aVR ST elevation in detection of the left main culprit coronary lesion was respectively 80% and 76%. The positive and negative predicted values were 44% and 94% respectively.

The prevalence of ST segment elevation in each lead among the LM, LAD and RCA group (Fig. 1)

The percentage of ST segment elevation in

lead aVR and V1 was 60% and 80% in the LM group 12.5% and 25% in the LAD group and 19% and 9% in the RCA group.

Comparison between degree of ST segment elevation in the LM group and ST segment elevation in the LAD group

Univariate analysis for distinguishing between the LM and LAD Groups was done. Degree of ST segment elevation in lead aVR was significantly higher in the LM group than the LAD group and RCA group (LM group: LAD group: RCA group = 0.22 ± 0.20: 0.03 ± 0.08 mV: 0.04 ± 0.07 mV; p = 0.009). The greater degree of ST elevation in lead aVR than lead V₁ ST elevation showed no statistically significant difference between the LM group, the LAD group and the RCA group (ST segment shift Lead aVR - ST segment shift Lead V₁ LM group: LAD group: RCA group = 0.06 ± 0.27: -0.06 ± 0.14 mV: -0.02 ± 0.17 mV; p = 0.38).

Clinical outcomes in ACS studied patients

There were 2 deaths in patients with aVR ST

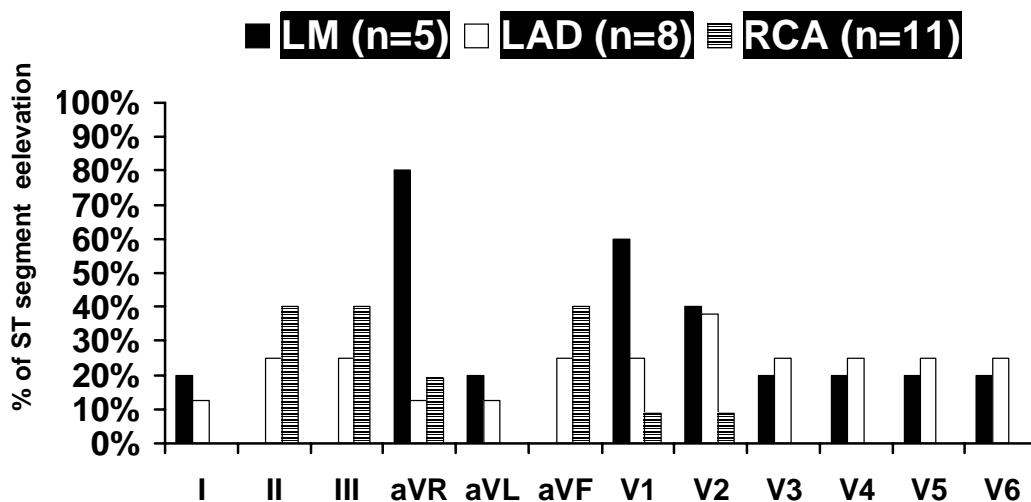


Fig. 2 The prevalence of ST segment elevation in each leads among the LM, LAD and RCA group

segment elevation (22%) but there was no death in those with aVR non-ST segment elevation. Revascularization was performed in all either percutaneous coronary intervention (aVR ST segment elevation vs. aVR non-ST segment elevation: 22% vs 42%) or coronary artery bypass graft (aVR ST segment elevation vs. aVR non-ST segment elevation: 78% vs 58%)

Analysis of intra-observer variability

The intra-observer mean differences in the limb leads was 0.01 ± 0.03 mV. The intra-observer mean differences in chest or precordial leads was 0.01 ± 0.04 mV. The correlation coefficient efficient was 0.9 at $p < 0.001$.

Discussion

Lead aVR ST segment elevation with less ST segment elevation in V_1 in patients with acute coronary syndrome are considered to relate with culprit left main coronary artery disease. Lead aVR ST segment elevation determines severe coronary artery disease such as acute left main occlusion⁽³⁾, proximal LAD lesion⁽⁴⁾ and three-vessel coronary artery disease⁽⁵⁾. There was a report by Barrabes JA et al about the poorer outcome predicted by ST-segment elevation in lead aVR in patients with a first non-ST segment elevation acute myocardial infarction⁽⁹⁾. However, significance of a lead aVR in clinical cardiology is not only in patients with acute coronary syndrome but also in those with acute pulmonary embolism⁽¹⁰⁾ and cardiac arrhythmia such as AV nodal tachycardia and ventricular tachycardia⁽¹¹⁾.

There were reports of the relationship of significance of lead aVR, the site of coronary occlusion and the size of area at risk. ST elevation in lead aVR are highly related with acute left main coronary artery occlusion⁽³⁾, proximal left anterior descending artery occlusion⁽⁴⁾ and three-vessel coronary artery disease⁽⁵⁾. The present study revealed significance of lead aVR ST segment elevation in the patients with acute coronary syndrome. It was found in 35% of the studied patients. The majority of those with aVR ST segment elevation had the culprit lesion at the left main coronary artery (80% of the left main group, 27% of the RCA group and 25% of the LAD group). This prevalence in the left main group is not different from a previous report by Yumaji et al (88% in the left main group)⁽³⁾ but its prevalence in the LAD group is less than the study of Engelen et al (43% in the LAD group)⁽⁴⁾ and Yumaji et al (43% in the LAD group)⁽³⁾. In three patients of the RCA group with aVR ST segment elevation, dominant RCA was found.

Univariate analysis for distinguishing between the LM and LAD Groups of the present study revealed that (Table 2) the degree of ST segment elevation in lead aVR was significantly higher in the LM group than the LAD group. The most likely interpretation of less ST segment elevation in lead V1 in the LM group compared with the LAD group is the result of electrical force induced by posterior wall ischemia in the LM group counterbalancing the ischemia induced electrical force in the anterior wall⁽⁴⁾.

Clinical outcomes of ACS patients with lead aVR ST segment elevation and lead aVR non ST segment elevation were different. There were 2 deaths (22%) in patients with aVR ST segment elevation but there was no death in those with aVR non-ST segment elevation. The left main coronary artery supplies a large myocardium of the left ventricle area and the culprit left main has resulted in severe hemodynamic changes and high mortality^(7,8). Revascularization was performed more either percutaneous coronary intervention or coronary artery bypass graft in those with lead aVR ST segment elevation. This corresponds with the previous studies⁽³⁻⁵⁾. The reason is that lead aVR ST segment elevation represent the culprit left main coronary artery, proximal LAD lesion and three vessel CAD. Those lesions had worse outcomes in terms of death and revascularization.

Study limitations

1. The small number of patients.
2. Retrospective study.
3. Selected cases from the patients who were admitted to the CCU
4. Interpretation of the relationship of the ECG findings and culprit coronary artery lesions
5. The ECG findings in the patients who had collateral artery may be different from those without collateral arteries.

In patients with acute coronary syndrome, Lead aVR ST segment elevation is associated with the culprit left main coronary lesion.

References

1. Gorgels AP, Vos MA, Mulleneers R. Value of the electrocardiogram in diagnosing the number of severely narrowed coronary arteries in rest angina pectoralis. *Am J Cardiol* 1993; 72: 999-1003.
2. Hurst JW. Methods used to interpret the 12-lead electrocardiogram: Pattern memorization versus the use of vector concepts. *Clin Cardiol* 2000; 23: 4-13.
3. Yamaji H, Iwasaki K, Kusachi S. Prediction of acute left main coronary artery obstruction by 12-lead

- electrocardiography: ST-segment elevation in lead aVR with less ST-segment elevation in lead V₁. *J Am Coll Cardiol* 2001; 38: 1348-54.
4. Engelen DJ, Gorgels AP, Cheriex EC. Value of the electrocardiogram in localizing the occlusion site in the left anterior descending coronary artery in acute anterior wall infarction. *J Am Coll Cardiol* 1999; 34: 389-95
 5. Gorgels APM, Engelen DJ, Wellens HJJ. The electrocardiogram in acute myocardial infarction. In: Fuster V, Alexander RW, O' Rourke RA, editors. *Hursts' the Heart*. 10th edition. New York: McGraw-Hill, 2000: 1361-71.
 6. Mueller HS, Dyer A, Greenberg MA. TIMI Study Group. The Thrombolysis in Myocardial Infarction (TIMI) trial: phase I findings. *N Engl J Med* 1985; 312: 932-6.
 7. Golgberg S, Grossman W, Markis JE. Total occlusion of the left main coronary artery; a clinical hemodynamic and angiographic profile. *Am J Med* 1978; 64: 3-8.
 8. Ward DE, Valentine H, Hui W. Occluded left main coronary artery; report of five patients and review of published reports. *Br Heart J* 1983; 49: 276-9.
 9. Brrabes JA, Figueras J, Moure C. Prognostic value of lead aVR in patients with a first non-ST-segment elevation acute myocardial infarction. *Circulation* 2003; 108: 814-9.
 10. Sreeram N, Cheriex EC, Smeets JLRM, George APM, Wellens HJJ. Value of the 12-lead electrocardiogram at hospital admission in the diagnosis of pulmonary embolism. *Am J Cardiol* 73: 298-303.
 11. Gorgels APM, Engelen DJ, Wellens HJJ. Editorial Comment. Lead aVR, a mostly ignored but very valuable lead in clinical electrocardiography. *J Am Coll Cardiol* 2001; 38: 1355-6.

ความสำคัญของคลื่นไฟฟ้าหัวใจที่มี ST segment elevation ในลีดส์ aVR ในผู้ป่วยที่มีกลุ่มอาการทางคลินิกที่เกิดจากหลอดเลือดแดงโคโรนารีตีบหรืออุดตันเฉียบพลัน

เกรียงไกร เสงษ์ศรี, วิรัช เคหสุขเจริญ, สุदारัตน์ ดันสุภสวัสดิกุล

วัตถุประสงค์: เพื่อศึกษาความสัมพันธ์ระหว่างคลื่นไฟฟ้าหัวใจในช่วง ที่มี ST segment elevation ในลีดส์ aVR กับ รอยโรคในหลอดเลือดแดงโคโรนารีที่สำคัญ (culprit lesion) ในผู้ป่วยหลอดเลือดหัวใจตีบหรืออุดตันเฉียบพลัน (acute coronary syndrome หรือ ACS) ซึ่งตรวจด้วยการฉีดสารทึบรังสีเพื่อตรวจหลอดเลือดหัวใจ (Coronary angiogram หรือ CAG)

วัสดุและวิธีการ: ตั้งแต่เดือนมกราคม 2544 ถึงเดือนธันวาคม 2544 เราได้ทำการศึกษาแบบย้อนหลัง (Retrospective study) ในผู้ป่วย 26 ราย จากผู้ป่วย 31 ราย ซึ่งรับไว้รักษาในหอผู้ป่วยหนักอายุรกรรมหัวใจของสถาบันโรคทรวงอก ด้วยกลุ่มอาการ ACS ได้ทำการตรวจ ECG, Chest X ray , ตรวจเลือดหาระดับ troponin T , creatine phosphokinase (CPK) , creatine kinase MB fraction (CK MB) ก่อนการทำ CAG สำหรับ CAG จะทำภายใน 48 ชั่วโมงหลังจากรับผู้ป่วยไว้ในโรงพยาบาล ได้นำผลการตรวจ ECG และ CAG มาทำการวิเคราะห์

ผลการศึกษา: ในจำนวนผู้ป่วย 26 ราย เป็นชาย 21 ราย และหญิง 5 ราย อายุเฉลี่ย 64 ± 9 ปี รอยโรคสำคัญใน กลุ่ม 1 อยู่ที่ Left main coronary artery (5 ราย, 19%), กลุ่ม 2 อยู่ที่ proximal left anterior descending artery (8 ราย, 31%), กลุ่ม 3 อยู่ที่ Right coronary artery (11 ราย, 42%) และกลุ่ม 4 อยู่ที่ Left circumflex artery (2 ราย, 8%) ผลการตรวจ ECG พบว่ามี ST segment elevation ในลีดส์ aVR (aVRSTE) มากกว่า 1 มิลลิโวลท์ (mV) ในผู้ป่วย 9 ราย (35%), 4 รายในกลุ่ม 1 (80%) 3 รายในกลุ่ม 2 (27%) และ 2 รายในกลุ่ม 3 (25%) ECG ที่มี aVRSTE พบในผู้ป่วยที่มีรอยโรคสำคัญอยู่ที่ Left main coronary artery มากกว่ารอยโรคสำคัญที่หลอดเลือดหัวใจที่ตำแหน่งอื่นโดยมี sensitivity 80%, specificity 76 % และ accuracy 77%.

สรุป: ในผู้ป่วยหลอดเลือดหัวใจตีบหรืออุดตันเฉียบพลัน คลื่นไฟฟ้าหัวใจที่มี ST segment elevation ในลีดส์ aVR มีความสัมพันธ์กับรอยโรคที่ Left main coronary artery
