

## Case Report

# Meningioma of the Internal Auditory Canal: A Case Report

Wandee Khaimook MD\*,  
Siriporn Hirunpat MD\*\*, Chawaboon Dejsukum MD\*\*\*

\* Department of Otolaryngology Head and Neck Surgery, Faculty of Medicine,  
Prince of Songkla University, Hat Yai, Songkhla

\*\* Department of Radiology, Faculty of Medicine, Prince of Songkla University, Hat Yai, Songkhla

\*\*\* Department of Pathology, Faculty of Medicine, Prince of Songkla University, Hat Yai, Songkhla

---

*Meningioma of the internal auditory canal is very rare. There are only 15 previous reports of intracanalicular meningioma. The authors add a case report of a patient with meningioma of the internal auditory canal. A 31-year-old woman presented with a one-year history of headache, dizziness, hearing loss and left facial paralysis. An MRI of the temporal bone demonstrated a tiny isointense intracanalicular tumor with inhomogeneous enhancement. In the operative field carried out by translabyrinthine approach, the tumor was found in the IAC without intracranial involvement. Pathology revealed a meningioma. The patient was followed up for 2 years without recurrence.*

**Keywords:** Meningioma, Internal auditory canal

**J Med Assoc Thai 2005; 88 (11): 1707-11**

**Full text. e-Journal:** <http://www.medassocthai.org/journal>

---

Meningiomas are the second most common tumors located in the cerebello-pontine angle (CPA)<sup>(1,2)</sup>. Although acoustic schwannoma account for the great majority of internal auditory canal (IAC) lesions, alternative pathological entities such as meningioma, facial nerve schwannoma, hemangioma, lymphangioma, hamatoma, lipoma, lymphoma, metastases and arachnoid cyst should also be considered<sup>(1-14)</sup>. It was unclear whether a meningioma could originate from within IAC and grow out into CPA or whether they always originated in the CPA and involved the IAC later. There have been only 14 previous reports of intracanalicular meningioma<sup>(1,2,7-14)</sup>. With the introduction of MRI with gadolinium, a tumor as small as 2 mm in the IAC could be detected. The authors report a case of IAC meningioma without intracranial attachment or extension.

### Case Report

A 31-year-old female presented with a two-year history of headache, dizziness and hearing loss.

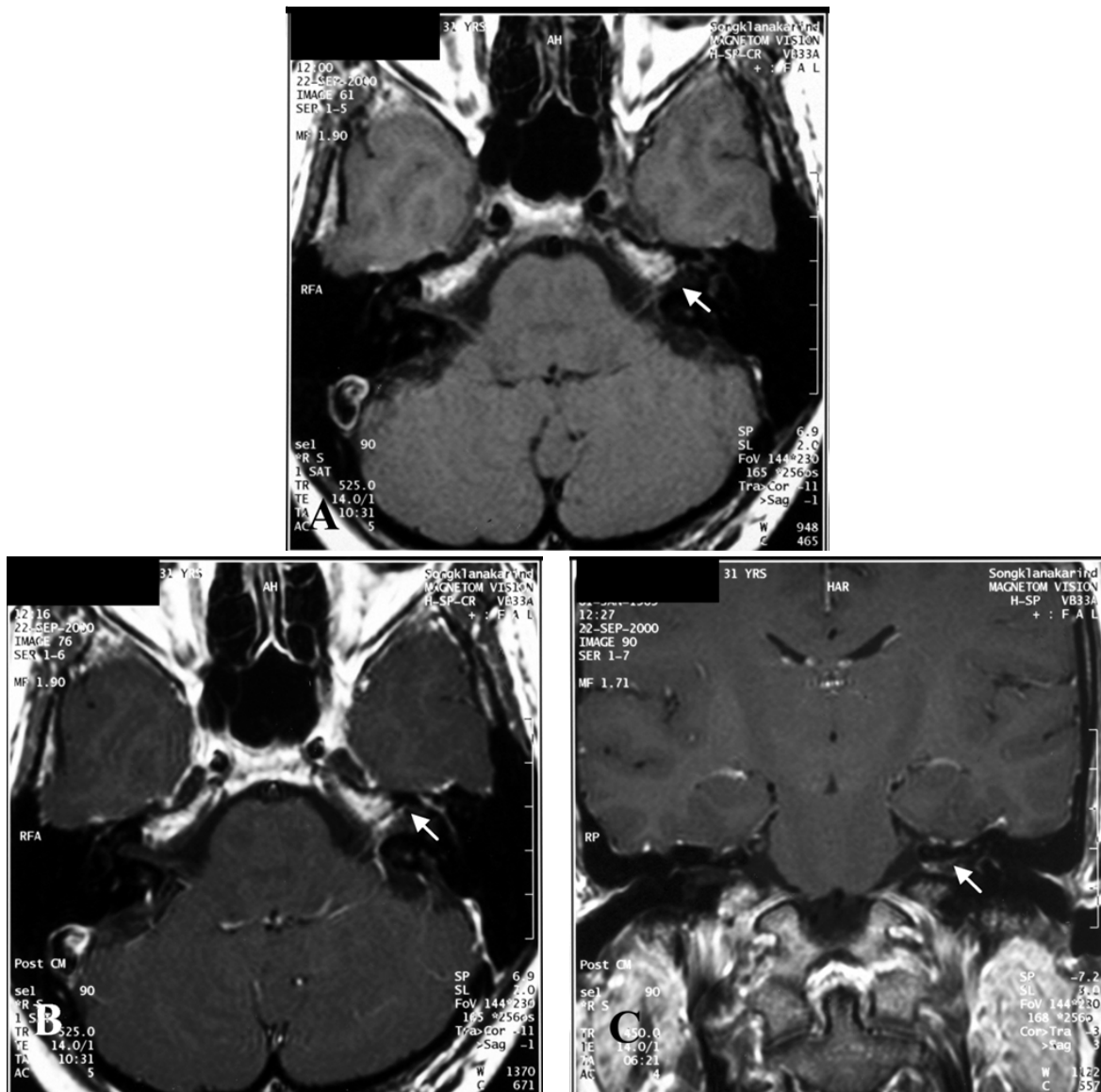
---

*Correspondence to : Khaimook W, Department of Otolaryngology Head and Neck Surgery, Faculty of Medicine, Prince of Songkla University, Hat Yai, Songkla 90112, Thailand.*

She had a one year history of progressive left-sided hearing loss and followed by left facial nerve paralysis. Physical examination revealed a complete lower motor neuron facial nerve paralysis. An audiologic workup revealed left deafness. A caloric test revealed no vestibular response on the left side. The remainder of the neurological examination showed no abnormal findings.

On T1-weighted Magnetic Resonance Imaging (MRI) images showed a tiny isointense intracanalicular tumor with inhomogeneous enhancement after gadolinium injection, displaced and almost obliterated the normal content of CSF compared to the contralateral IAC (Fig. 1). A pre-operative diagnosis of acoustic schwannoma was made.

At surgery, carried out by the translabyrinthine approach, the IAC was explored and a tan, multilobulated, soft tumor was found in the IAC, not extending into the CPA and without intracranial attachment. The seventh, and eighth nerve were infiltrated with tumor and the bone around IAC was destroyed. The lateral end of the tumor was carefully dissected to ensure complete removal, and the tumor was completely excised. Postoperatively, she did well without CNS



**Fig. 1** Magnetic resonance imaging of temporal bone  
 A) Axial T1- weighted images reveal a tiny isointense intracanalicular tumors (arrow), displacing and almost obliterating the normal content of CSF  
 B,C) Inhomogeneous enhancement (arrow) after Gd- DTPA injection

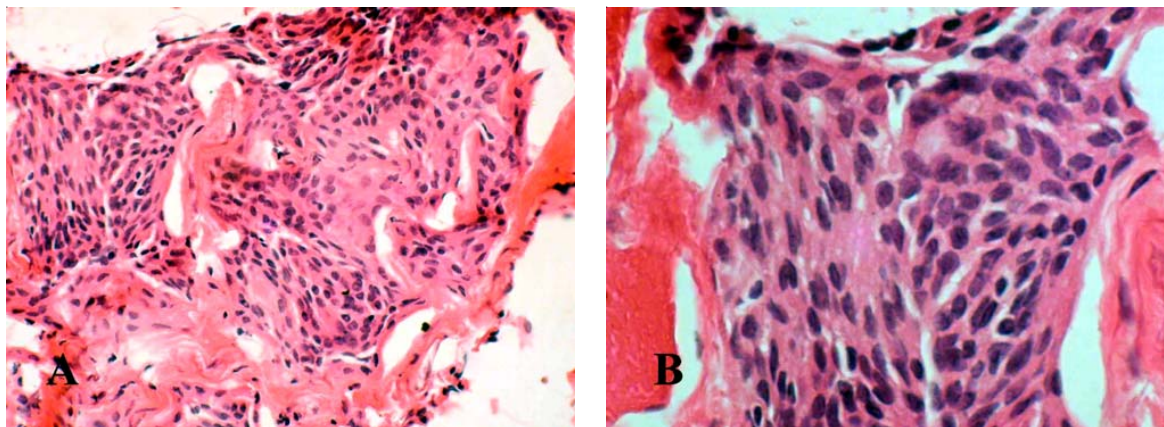
complication and she was followed up for 24 months without recurrence.

Pathology revealed a meningioma (Fig. 2).

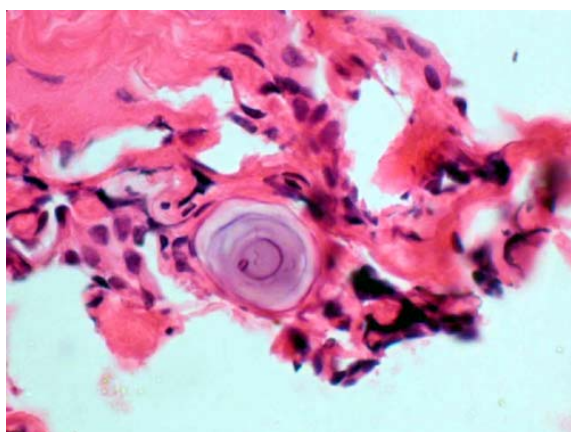
### Discussion

Most lesions of the IAC and CPA are acoustic schwannoma and meningioma. Other rare lesions are hamartomas<sup>(3)</sup>, hemangiomas<sup>(4)</sup>, facial nerve schwannomas<sup>(6)</sup>, lipomas and arachnoid cysts.

Meningiomas are thought to arise from the epithelial lining cells of arachnoid villi. They arise most frequently along the dural venous sinuses adjacent to the sigmoid sinus, jugular foramen, torcula, or the superior and inferior petrosal sinuses<sup>(1,2,5,7-13)</sup>. Arachnoid granulations also occur less commonly along the dural lining of foramina of the cranial nerves, including the IAC, thus meningiomas may originate within the IAC. Meningiomas can arise within IAC 10-20%<sup>(5)</sup>.



**Fig. 2** Histopathological analysis of the mass demonstrating meningioma. (Hematoxylin and eosin stain)  
A, B) The sections show nests of cells which oval nuclei, inconspicuous nucleoli, lightly eosinophilic cytoplasm and indistinct cytoplasmic border, a feature of meningothelial cells



**Fig 3.**The sections show the concentrically calcified structure (Psammoma body) among the tumor cell

In the era before MRI, meningioma were most often discovered when they had grown quite large, and their site of origin was uncertain<sup>(2)</sup>. It was unclear whether a meningioma could originate from within the IAC and grow out into the CPA or whether they always originate in the CPA and involves the IAC secondarily. With MRI tumor as small as 2 cm could be detected in the IAC.

Meningioma most commonly arise during the fourth to sixth decades, and occur more frequently in women (F:M ratio 2-5:1)<sup>(2,5,7,9,11,12)</sup>. Monosomy of chromosome 22 is the most characteristic genetic anomaly, when either copies of the gene are missing or damaged, unregulated growth can occur, leading to tumor formation<sup>(2)</sup>.

The clinical symptomatologies of intracanalicular meningioma are very similar to those in patients with acoustic schwannoma and other lesions that occupy the IAC such as headaches, dizziness, dysequilibrium and hearing loss (Table 1). But some evidence may facilitate the diagnosis of meningioma more than acoustic schwannoma such as hearing loss has been noted to be less frequent with meningioma than AN, whereas facial nerve involvement is more common in IAC meningiomas than in AN<sup>(1,5-13)</sup>. For CPA meningioma, enhanced MRI demonstrated a sessile, broadly based, homogeneous enhancing lesion. Computed tomography (CT) scan showed a dural tail, calcification 25-36%, hyperostosis of petrous bone 15-25%<sup>(1,5,9)</sup>, bone invasion and an aggressive lesion more than acoustic neuroma such as deep invasion of the temporal bone, the tumor extended to the fundus of the IAC, the tumor invaded the labyrinth and the cochlear of the inner ear, extension from IAC along facial nerve canal to involve horizontal and vertical part of facial nerve, involvement of the ampullated end of the posterior semicircular canal and involvement of the vestibule of the inner ear<sup>(1,4)</sup>.

On T1- weighted MRI both acoustic schwannoma and meningioma are mostly isointense, but occasionally hypointense relative to brain parenchyma. On T2- weighted MRI acoustic neuroma tend to be higher in intensity than meningiomas and more enhancement with intravenous gadolinium contrast than meningiomas, but this difference is too insignificant to be of clinical value<sup>(3,5,7-10)</sup>. Bone invasion is an unusual finding with intracanalicular tumors, but may suggest meningioma like in the presented case.

**Table 1.** Clinical findings of intracanalicular meningiomas and surgical approach

Study	age/sex	major symptom	surgical approach	intraop. finding
Singh et al <sup>(12)</sup> 1975	14/M	Lt deaf facial weakness 4 yr	MF	granular appear
Langman et al <sup>(10)</sup> 1990	52/M	Rt SNHL, vertigo	TL	Mass at porus acousticus
	54/M	Bilateral HL	TL	not reported
Zeitouni et al <sup>(2)</sup> 1997	60/F	Dysequilibrium, HL 6 mo	TL	not reported
Ishikawa et al <sup>(1)</sup> 1999	55/M	HL, Facial palsy 5 yr	TL	not reported
Dinh et al <sup>(7)</sup> 2000	53/F	Rt HL, hemifacial spasm 1 yr	SO	tan to red mass
Caylan et al <sup>(13)</sup> 2000	42/M	Rt HL, vertigo 2 yr	TL	hypervascular
	46/M	Rt HL, Unsteadiness 2 mo	TL	high vascular
Devesa et al <sup>(11)</sup> 2001	48/F	Lt HL, unsteadiness 9 mo	TL	friable and vascular
Hilton et al <sup>(8)</sup> 2002	38/F	Lt HL 2 y, facial palsy 3 mo	TL	not reported
Asaoka et al <sup>(9)</sup> 2002	66/M	Lt HL tinnitus 3 mo	MF	tan multilobe, hypervascular
	39/M	Lt SNHL 1 yr	TL	Friable, hypervascular
	67/F	Lt HL, facial palsy 3 yr	TL	Hypervascular, calcification

Meningiomas have a much higher tendency to recurrence than acoustic schwannoma and varies between 0% and 30%<sup>(2,11)</sup>. The most important factor in determining the recurrence rate are associated with incomplete resection, presence of residual disease at the tumor resection, cauterizing adjacent dura may lead to a higher recurrence rate, wide dural excision should be performed<sup>(2,9)</sup>.

#### References

- Ishikawa N, Komatsuzaki A, Tokano H. Meningioma of the internal auditory canal with extension into the vestibule. *J Laryngol Otol* 1999; 113: 1101-3.
- Zeitouni AG, Zagzag D, Cohen NL. Meningioma of the internal auditory canal. *Ann Otol Rhinol Laryngol* 1997; 106: 657-61.
- Ajal M, Roche J, Turner J, Fagan P. Unusual lesions of the internal auditory canal. *J Laryngol Otol* 1998; 112: 650-3.
- Omojola MF, Hawashim NS, Zuwayed MA, Ferayan AA. Case report: CT and MRI features of cavernous haemangioma of internal auditory canal. *Br J Radiol* 1997; 70: 1184-7.
- Voss NF, Vrionis FD, Heilman CB, Robertson JH. Meningiomas of the cerebellopontine angle. *Surg Neurol* 2000; 53: 439-47.
- Saada AA, Limb CJ, Long DM, Niparko JK. Intracanalicular schwannoma of the facial nerve. *Arch Otolaryngol Head Neck Surg* 2000; 126: 547-9.
- Dinh DH, Clark SB, Whitehead M, Amedee R, Bhattacharjee MB. Intracanalicular meningioma. *South Med J* 2000; 93: 618-21.
- Hilton MP, Kaplan DM, Ang L, Chen JM. Facial nerve paralysis and meningioma of the internal auditory canal. *J Laryngol Otol* 2002; 116: 132-4.
- Asaoka K, Barrs DM, Sampson JH, McElveen JT, Tucci DL, Fukushima T. Intracanalicular meningioma mimicking vestibular schwannoma. *Am J Neuroradiol* 2002; 23: 1493-6.
- Langman AW, Jackler RK, Althaus SR. Meningioma of the internal auditory canal. *Am J Otol* 1990; 11: 201-4.
- Devesa PM, Wareing MJ, Moffat DA. Meningioma in the internal auditory canal. *J Laryngol Otol* 2001; 115: 48-9.
- Singh KP, Smyth GDL, Allen IV. Intracanalicular meningioma. *J Laryngol Otol* 1975; 89: 549-52.
- Caylan R, Falcioni M, Donato GD, Ferrara S, Russo A, Taibah A, et al. Intracanalicular meningioma. *Otolaryngol Head Neck Surg* 2000; 122: 147-50.

---

## เนื้องอกเยื่อหุ้มสมองของช่องหูชั้นใน: รายงานผู้ป่วย

วันดี ไช่มุกด์, สิริพร หิรัญแพทย์, ชวบูลย์ เดชสุขุม

เนื้องอกเยื่อหุ้มสมองของช่องหูชั้นใน (Meningioma of the internal auditory canal) เป็นโรคที่พบบได้น้อยมาก มีผู้ป่วยที่รายงานเพียง 15 คน คณะผู้รายงานได้รายงานผู้ป่วยเพศหญิงหนึ่งราย อายุ 31 ปีมีอาการปวดและมีเสียงศีรษะ การได้ยินลดลงและใบหน้าซีกซ้ายเป็นอัมพาตมา 1 ปี ส่งตรวจคลื่นแม่เหล็กพบว่ามีเนื้องอกขนาดเล็กที่ช่องหูชั้นใน ผู้ป่วยได้รับการผ่าตัด ผลชิ้นเนื้อทางพยาธิวิทยายืนยันว่า เป็น Meningioma การติดตามผู้ป่วยหลังผ่าตัด 2 ปี ยังไม่พบการเกิดซ้ำ

---