

## Case Report

# Canadian Frame and Bilateral Brachial Plexus Neurapraxia

Maliwan Oofuvong MD\*

\* Department of Anesthesiology, Faculty of Medicine, Prince of Songkla University

*A reported case of postoperative bilateral brachial plexus neurapraxia associated with the use of a Canadian frame in a patient who had thoracolumbar spinal surgery under general anesthesia. Symmetrical misposition of the upper pads of the Canadian frame underneath both shoulder heads during prolonged surgery led to direct compression on or stretching of the bilateral brachial plexus. This complication should be prevented by carefully placing the patient on this sort of frame.*

**Keywords:** Canadian frame, Bilateral brachial plexus neurapraxia

*J Med Assoc Thai 2005; 88(12): 1952-4*

*Full text. e-Journal: <http://www.medassocthai.org/journal>*

Postoperative brachial plexus injury is not an uncommon complication following improper positioning and padding<sup>(1-4)</sup>. It results from direct compression on or stretching of the brachial plexus<sup>(2-4)</sup> or severe compression secondary to swelling of the surrounding structures<sup>(5)</sup>. There is only one report which discusses cases of brachial plexopathy related to a Relton-Hall positioning frame that is similar to the Canadian frame used in the authors' hospital<sup>(6)</sup>. The author report a case of bilateral brachial plexus neurapraxia caused by different mechanism during a prone position related to the Canadian frame.

### Case Report

A 19-year-old Asian man with paraplegia from a car accident was admitted to the hospital with a burst fractured dislocation at T12-L1, scheduled for posterior fusion under general anesthesia. The preanesthetic evaluation revealed an ASA physical status II from the paraplegia. There was no associated injury, especially cervical spine injury. General anesthesia was induced with the patient in the supine position. Subsequently, he was placed in a prone position above a Canadian frame (Fig. 1). The upper chest, shoulders and the iliac crests were supported by 4 pads of the Canadian frame, with part of the heads of the shoulders placed on the upper pads. The head was supported by a horseshoe pad in a neutral

position. Both arms abducted and the hands pronated not exceeding 90 degrees. The operation lasted for about 7 hours and then the patient was turned supine.

Five hours after surgery, the patient complained of bilateral arms weakness, numbness and electric shock-like sensation in the left side more than the right side. A physical examination revealed more diminished sensation in the left fifth, sixth and seventh cervical dermatomes than the right side. Motor power of the left deltoid, biceps, triceps and brachioradialis was grade II while it was grade III on the right side. A plain film of the cervical spine was normal. A diagnosis of bilateral brachial plexus injury involving mainly the upper trunk was suggested by a neurosurgeon. After intensive physiotherapy, the motor power of the right arm was completely recovered within 3 days. Motor power and numbness of the left arm were improved within 7 days and completely recovered within 3 weeks. An electromyogram (EMG) was not performed because the patient demonstrated a full recovery of both arms within 3 weeks.

### Discussion

This brief case report, although not associated with serious neuropathy, should serve to remind anesthesiologists of the possibility of brachial plexus injury in patients placed in a prone position using a spinal operating frame under general anesthesia. The two most common mechanisms are improper positioning and padding of the patient. Carefully placing the patient on the operating frame is very important. There is no reported incidence of brachial

Correspondence to :Oofuvong M, Department of Anesthesiology, Faculty of Medicine, Prince of Songkla University, Hatyai, Songkhla 90110, Thailand Tel.&Fax 66-074-429621E-mail address: malewan@yahoo.com

plexus injury related to a spinal operating frame in the ASA closed claims project database, however, Schwartz DM et al<sup>(6)</sup> reported an incidence of 3% for brachial plexopathy in scoliotic patients exerted by a Relton-Hall positioning frame which is similar to the Canadian frame used in the authors' hospital. The mechanism was thought to be a result from pressure of the upper pads on the axilla effecting the lower trunk of the brachial plexus. The reported case is unlikely to be explained by this mechanism because the lower trunk of the brachial plexus was not involved.

The Canadian frame is a spinal supporting frame with 4 small pads sized 12 cm x 12 cm (Fig. 1) to support the upper chest, shoulders and iliac crests. Its figure looks like the Relton-Hall frame, therefore it could be a local description for a variant of the Relton-Hall frame. The advantage of this frame for spinal surgery is its ability to reduce blood loss at the surgical site by not compressing the pendulous abdomen, in comparison with the Wilson frame<sup>(7)</sup>. However, the 4 small pads of the Canadian frame only partially support the trunk compared to the Wilson frame which provides full support. In this context, the Canadian frame may result in significant pressure on the upper chest and shoulders. It should be taken into account that position of the upper pads is important. External rotation of the upper pads results in a position likely to abduct the shoulder heads, which may lead to stretching of the brachial plexus. If compression on and/or stretching of the brachial plexus occurred in this case, the prolonged operation time (7 hours) may have aggravated the situation<sup>(8)</sup>.

Placing and positioning a patient on the Canadian frame cautiously is of fundamental importance. The upper pads of the frame should be placed underneath the upper chest on the antero-lateral chest wall not the shoulder to avoid compression on and stretching of the upper trunk of the brachial plexus. The lower pads of the frame should be placed underneath the iliac crests (Fig. 2). The shoulders should not be abducted more than 90 degrees to avoid injury to the lower trunk of the brachial plexus.

### Conclusion

An awareness of the potential injury of the brachial plexus during prone positioning using a Canadian frame is important. Patients should be correctly placed on the pads of the Canadian frame to avoid nerve damage.



Fig. 1 Canadian frame

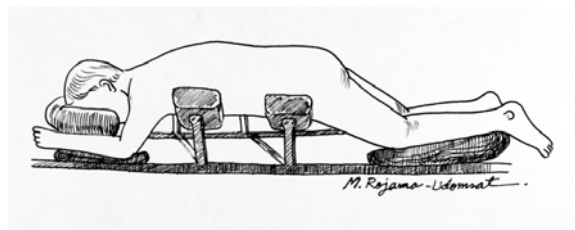


Fig. 2 Recommended position for patient placing on Canadian frame

### Acknowledgement

The author wishes to thank Dr. Sasikaan Nimmaanrat for reviewing this manuscript.

### References

1. Godfrey PM, Godfrey NV, Fast A, Kemeny M. Bilateral brachial plexus palsy after immediate breast reconstruction with TRAM flaps. *Plast Reconstr Surg* 1994; 93: 1078-9; discussion 1080-1.
2. Mitterschiffthaler G, Theiner A, Posch G, Jager-Lackner E, Fuith LC. Lesion of the brachial plexus, caused by wrong positioning during surgery. *Anasth Intensivther Notfallmed* 1987; 22: 177-80.
3. Lin PY, Luo CY, Kan CD, Yang YJ, Jou IM. Brachial plexus injury following coronary artery bypass surgery: a case report. *Kaohsiung J Med Sci* 2000; 16: 638-42.
4. Anderton JM, Schady W, Markham DE. An unusual cause of postoperative brachial plexus palsy. *Br J Anaesth* 1994; 72: 605-7.
5. Bhardwaj D, Peng P. An uncommon mechanism of brachial plexus injury. A case report. *Can J Anaesth* 1999; 46: 173-5.
6. Schwartz DM, Drummond DS, Hahn M, Ecker ML, Dormans JP. Prevention of positional brachial plexopathy during surgical correction of scoliosis. *J Spinal Disord* 2000; 13: 178-82.
7. Park CK. The effect of patient positioning on intraabdominal pressure and blood loss in spinal surgery. *Anesth Analg* 2000; 91: 552-7.

8. Akinbingol G, Borman H, Maral T. Bilateral brachial plexus palsy after a prolonged surgical procedure of

reduction mammoplasty, abdominoplasty, and liposuction. *Ann Plast Surg* 2002; 49: 219-20.

---

## แคนาเดียนเฟรมและการบาดเจ็บชั่วคราวของข่ายประสาทเบรเคียลทั้ง 2 ข้าง

มลิวัดย์ ออฟูวงศ์

รายงานผู้ป่วยที่มีการบาดเจ็บชั่วคราวของข่ายประสาทเบรเคียล 2 ข้างภายหลังการดมยาสลบ ซึ่งมีความสัมพันธ์กับการใช้แคนาเดียนเฟรมในขณะผ่าตัดบริเวณกระดูกสันหลังระดับเอว จากการเลื่อนตำแหน่งของการจัดท่าทำให้เบาะรองส่วนบนของแคนาเดียนเฟรมวางใต้หัวไหล่ทั้ง 2 ข้างรวมกับการผ่าตัดที่ใช้เวลานาน อาจเป็นสาเหตุทำให้เกิดการกดทับเส้นประสาทโดยตรงหรือมีการดึงรั้งของข่ายประสาทเบรเคียลบริเวณหัวไหล่ ซึ่งภาวะแทรกซ้อนดังกล่าวสามารถป้องกันได้โดยให้ความระมัดระวังเป็นพิเศษขณะจัดท่าผู้ป่วยบนเฟรมผ่าตัดดังกล่าว