

# Comparison of Clinical Success between CT-Guided Percutaneous Drainage and Open Surgical Drainage of Intra-Abdominal Fluid Collection in Srinagarind Hospital

Vallop Laopaiboon MD MSc\*,  
Chalida Aphinives MD\*, Parawee Prawiset MD\*

\* Department of Radiology, Faculty of Medicine, Khon Kaen University, Khon Kaen, Thailand

**Background:** Treatment outcome of intra-abdominal fluid collections has improved over the recent decades due to advancement in surgical techniques as well as development of computed tomography (CT) guided percutaneous interventional techniques.

**Objective:** To compare clinical success of CT-guided percutaneous drainage with open surgical drainage of intra-abdominal fluid collections in Srinagarind hospital.

**Material and Method:** The records and images of all patients undergone CT-guided percutaneous drainage (CT-PCD) or open surgical drainage (OSD) from 2004 to 2007 were reviewed. Comparison of clinical success (improvement of lesion, subsidence of clinical sepsis, no complications, and no mortality) between the two groups was determined.

**Results:** There was no statistically significant difference ( $p$ -value = 0.520) in the clinical success between CT-PCD group (25/29 patients, 86.2%) and OSD group (11/14 patients, 78.5%). Complication in four patients (including one death) was found in the OSD group compared to zero patients in the CT-PCD group. The proportion of lesion subsided after CT-PCD (25/28 patients, 89.3%) was higher than OSD (10/14 patients, 71.4%). The mean times of hospital stay were 20.2 days in PCD and 24.5 days in OSD groups.

**Conclusion:** CT-guided percutaneous drainage might be used as a first line treatment of intra-abdominal fluid collections.

**Keywords:** CT-guided percutaneous drainage, Surgical drainage, Intra-abdominal fluid collection, Srinagarind Hospital

*J Med Assoc Thai 2010; 93 (Suppl. 3): S45-51*

**Full text. e-Journal:** <http://www.mat.or.th/journal>

Intra-abdominal abscesses or collections of fluids or purulent materials may be intraperitoneal, retroperitoneal or visceral. Although the clinical features vary depending on the location of an abscess, fever, leukocytosis, and increased erythrocyte sedimentation rate are frequently noted. The mortality in undrained abdominal abscesses is high with a mortality rate ranging between 45 and 100%<sup>(1,2)</sup>. Radiological diagnosis of a clinically suspected abdominal collection is essential to guide the treatment. The first-line diagnostic tools include plain abdominal films and ultrasonography. Ultrasound is a fast, portable, and cheap diagnostic tool; furthermore, there is no ionizing radiation<sup>(1,3)</sup>. Ultrasound (US) is a very useful diagnostic tool for detection and localization of fluid collection

in the abdomen. It is particularly useful in evaluating multiloculated collections<sup>(4)</sup>. Limitations of ultrasound are in cases with extensive surgical wounds, bowel ileus or obese patients<sup>(5)</sup>. Although US is useful, computed tomography (CT) is the preferred method in the diagnosis of intra-abdominal abscesses. CT is more accurate than US for detection of intra-abdominal abscesses. It provides excellent anatomic detail, and clearly demonstrates the relation of fluids to nearby structures. CT is not affected by the surgical wounds or dressings, ileus, or obesity. Radionuclide imaging with <sup>67</sup>Ga- and <sup>111</sup>In-labeled leukocytes provides useful information in the diagnosis of intra-abdominal abscesses. These agents accumulate in the abscesses and appear as hot spots in areas of inflammation or abscesses and also in tumors. The major disadvantage of scintigraphy studies is that they do not provide sufficient anatomic details to help plan and select the best access for percutaneous drainage<sup>(3,6)</sup>. Treatment

Correspondence to: Laopaiboon V, Department of Radiology, Faculty of Medicine, Khon Kaen University, Mitrapap Road, Khon Kaen 40002, Thailand. Phone: 043-348-389, Fax: 043-348-389. E-mail: [laopaiboonv@yahoo.co.uk](mailto:laopaiboonv@yahoo.co.uk)

of the intra-abdominal collections is divided into; (1) surgical, (2) medical, and (3) combined surgical and medical treatments. Surgical treatment is subdivided into open and percutaneous drainage. The outcome in various sites of intra-abdominal abscesses, has improved over the recent decades due to advancement in surgical techniques as well as development of image guided percutaneous interventional techniques which allow for an effective drainage with minimal trauma to the tissues and lower morbidity and mortality rates<sup>(2,3,7)</sup>. In post-operative collections, the most common goal was to avoid or delay additional abdominal surgery wherein re-operation would be difficult especially in high-risk patients<sup>(8)</sup>. The basic indication for needle aspiration is to confirm the radiological diagnosis of an abscess because the radiological signs may not distinguish among various types of fluid collections including abscess, hematoma, urinoma, biloma, lymphocele, seroma, and loculated ascites. The main indications for the catheter drainage include treatment or palliation of sepsis associated with an infected fluid collection, and alleviation of the symptoms that may be caused by fluid collections by virtue of their size, like pancreatic pseudocyst or lymphocele<sup>(1)</sup>. CT is the method of choice when US guidance does not seem to be safe enough in such cases. In the experience of this group, a preference for the CT guidance is helpful in most cases.

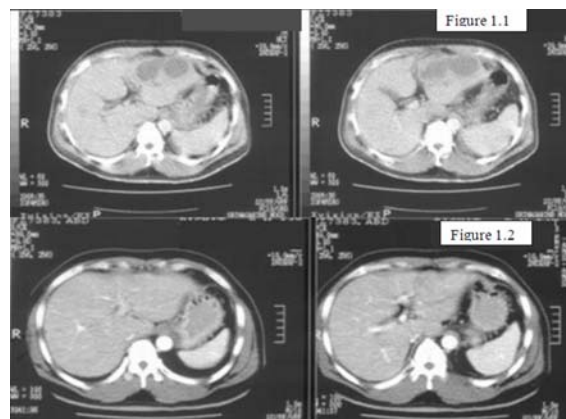
The purpose of the present study was to compare the clinical success of CT-guided percutaneous drainage with surgical drainage of intra-abdominal collections at Srinagarind Hospital.

## Material and Method

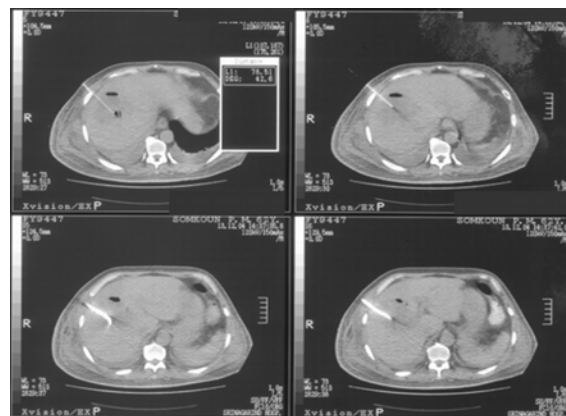
### Study Population

The medical records, radiological records, and images of 43 patients at Srinagarind Hospital during 4 years period (January 1, 2004 to December 31, 2007) who had undergone CT-guided percutaneous drainage (CT-PCD) and open surgical drainage (OSD) of intra-abdominal collection(s) were retrospectively reviewed. Prior to each procedure, the risks and benefits of treatment were discussed, and informed consent was obtained from every patient. The patients of CT-guided in PCD group were evaluated for platelet count, PT, PTT, INR. More information was required in OSD group such as chest film, BUN, creatinine, ECG and CBC, which was individually adjudged by the surgeon. The study population included 14 men (48.3%) and 15 women (51.7%) in CT-PCD group and 9 males (64.3%) and 5 females (35.7%) in OSD group. Their ages are range

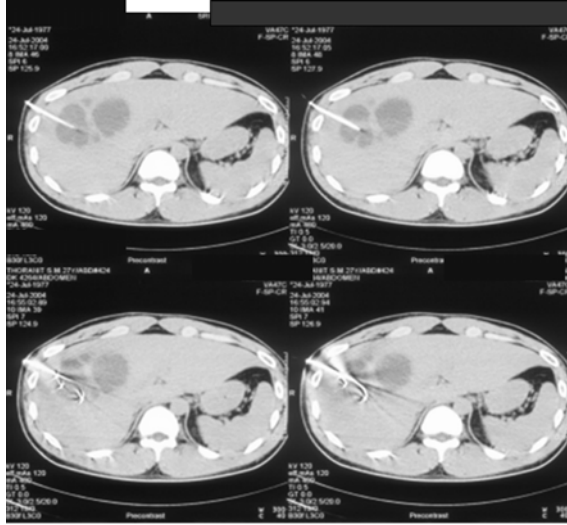
from 12 to 80 years (mean, 50.9 and 48.5 years in PCD and OSD groups respectively). Sixteen CT-PCD patients underwent CT-guided percutaneous aspiration without drainage catheter placement (Fig. 1, 5), and 13 patients had catheter placement (Fig. 2-4). The authors's exclusion criteria were those who were treated by other image-guided PCD such as ultrasonography, and the patients or their family members who could not accept



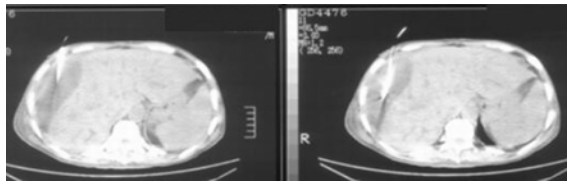
**Fig. 1** 1.1) Male, age 54 years old, with liver abscesses at segment 2,3 underwent CT-guided percutaneous tapping at lateral segment of left lobe liver (drainage was not performed due to minimal residual normal liver parenchyma at lateral segment). 1.2) CT scan shows complete resolution after 5 weeks of follow-up study.



**Fig. 2** Male, age 65 years old, with liver abscess at segment 7, underwent CT-guided PCD improved after 2 more revisions (images not shown). The depth from skin was 7.8 cm.



**Fig. 3** Male, age 27 years old, with liver abscess at segment 8, underwent CT-guided PCD. The abscess resolved in only one procedure. The drainage catheter was removed in 30 days.



**Fig. 4** Male, age 55 years old, with post-op right subphrenic collection for cholangiocarcinoma underwent successful CT-guided PCD. The post-procedure images were not shown.

procedure-related risks. The authors's study was approved by the Institutional Review Board of Srinagarind Hospital.

#### **Technique of CT-guided percutaneous drainage**

All patients underwent a diagnostic CT examination prior to the procedure. The images were obtained at the area of interest with 10 mm-thick contiguous axial computed tomographic sections, depending on the size of the lesion by a single slice helical CT scanner (Exvision/Ex: Toshiba Cooperation Medical System Division, Tokyo, Japan) with 5 mm collimation and a pitch of 1, or a multislice CT scanner (Somatom plus 4 Volume zoom: Siemens, Forchheim, Germany) with 2.5 mm collimation and a pitch of 0.25. The diameters of the lesions range from 1 to 15 cm (mean 6.4 cm). The drainage paths were planned to

avoid vital organs and vascular structures. The drainage procedures were performed by radiologists with different of training: 2 staff members with 24 and 13 years of experience after radiology residency and periodic post-residency training in interventional radiology and image-guided PCD; and, 1<sup>st</sup>, 2<sup>nd</sup>, and 3<sup>rd</sup> year-radiology residents. All resident's performances were under staff supervision, in accordance with the protocol of the Interventional Radiology Section at the authors's institution. The procedure was performed with the patient in a supine, prone, or lateral decubitus position, depending on the location of the lesion.

A subcutaneous injection of 1% Lidocaine for local anesthesia was administered. The needle was then left in place with its tip pointed to the lesion of interest. The depth from skin to the center of the collection was measured. Intravenous Pethidine 25 mg was given for systemic anesthesia in some cases. A 5 Fr sheath catheter was used for all punctures. Imaging was performed immediately to document the position of the sheath catheter within the lesion. All patients had imaging available for review before the procedures. From the preview of existing or new localization CT scans, an optimal drainage path was planned. After local anesthesia and a small incision, a 5 Fr sheath catheter was inserted under intermittent CT guidance with its trajectory pointing toward the lesion. The tract was dilated by dilators up to the size of drainage catheter. Each radiologist had free choice for selection of drainage catheter size, but an 18-gauge Cope self retaining loop catheter was most commonly used. The catheter tip was left in the lesion in a dependent position which will provide effective drainage. The external part of catheter was then sutured securely to the skin, and then connected to the container. For the patients who underwent percutaneous tapping, an 18-gauge spinal needle was inserted under intermittent CT guidance into the center of the lesion, and then aspiration was done. The specimen was obtained and sent to the microbiology department for culture/sensitivity and sometime cytology examination. There was no available on-site cytopathologists.

#### **Post procedure Care**

After the procedure, the patients were monitored in inpatient ward. They were observed for symptoms of complications such as abdominal pain or bleeding. Conservative treatment was given by monitoring the vital signs, drainage output, supplementary oxygen, adequate analgesia and antibiotics.

**Definitions**

The criteria for clinical success were: - (1) improvement of the lesion, (2) sepsis subsided (sepsis is improved and/or discharge with approval), (3) no complication, and (4) no mortality.

Number of attempts of treatment procedure refer to number of performances (the first attempt plus the revised attempts) done to correct the drainage problems.

**Data Analysis**

Demographic data was expressed as mean value and percentage. The type and frequency of all complications and successful procedures in 43 patients were recorded and analyzed. Inferential statistics; Fisher’s Exact test and Chi-square tests were used. A p-value of less than 0.05 was considered statistically significant difference.

**Results**

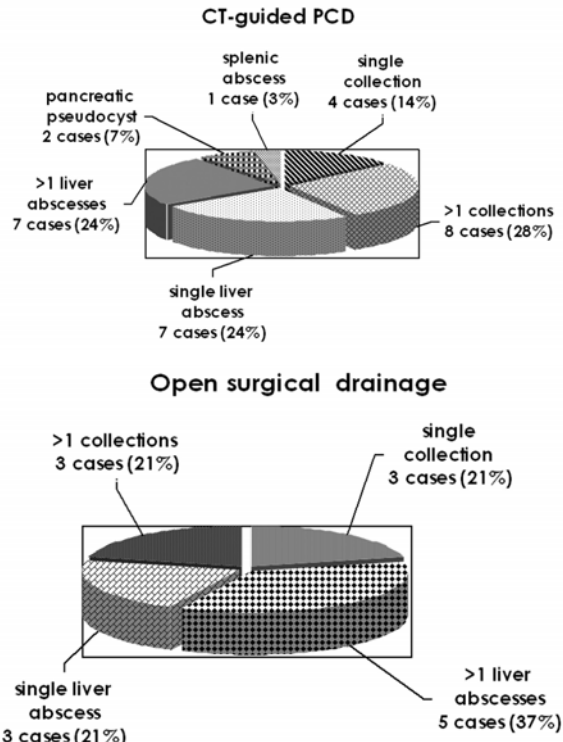
The mean size of the collections in CT-PCD group and OSD group were 42.06 mm (SD = 30.1) and 29.79 mm (SD = 19.9), respectively. There was no statistically significant difference of mean size between two groups (p-value = 0.200). The mean lengths of hospital stay were 20.2 days and 24.5 days in PCD and OSD groups, respectively. There was no statistically significant difference of mean length of hospital stay between two groups (p-value = 0.49).

Improvement of the lesion and subsidence of the clinical sepsis were achieved in 25 CT-PCD cases (89.3%), and 10 cases (71.4%) from OSD group. There was no statistically significant difference between two groups (p-value = 0.140).

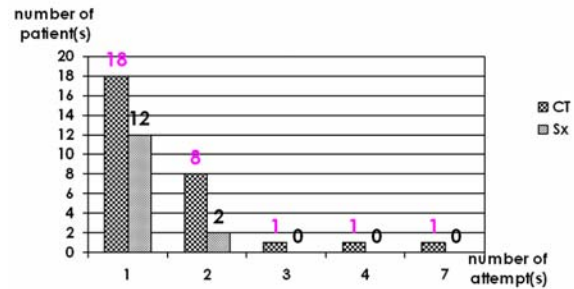
Three patients in CT-guided PCD were discharged against advice and one patient in OSD expired.

Graph 1 shows the site of collections in both groups. Single/multiple collection(s) and liver abscess (es) were separately analyzed. The procedures were performed more frequent for various sites/organs in CT-PCD group than OSD group (6 and 4, respectively). Pancreatic pseudocysts (Fig. 5) and splenic abscess were not performed in OSD group.

Graph 2 shows number of attempts of treatment procedures. More than 60% of the patients underwent only one attempt procedure (18 patients, 62.0% and 12 patients, 85.7% and in PCD and OSD groups respectively). Two patients in OSD group required second operation. One of the two was cases had poor response to treatment, finally was converted



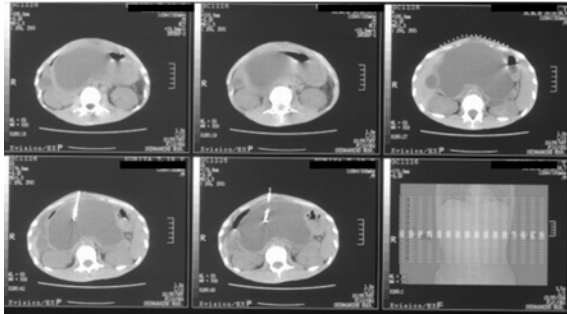
**Graph. 1** Site of intra-abdominal fluid collections in two groups



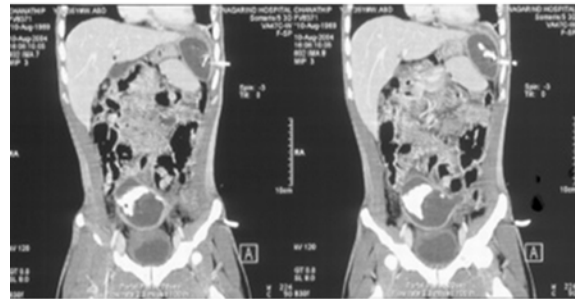
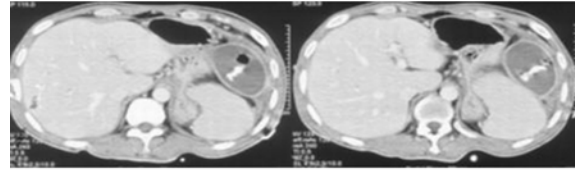
**Graph. 2** Number of attempts of each of treatment procedure

to percutaneous drainage.

There was no post procedural complication in CT-PCD group. Four patients in OSD group developed postoperative complication (28.6%), (Fig. 6). There was statistically significant difference in its occurrence between the two procedures (Fisher’s Exact test = 0.008). All were late complication; 1 wound infection, 1 enterocutaneous fistula, 1 lung atelectasis, 1 pneumonia with sepsis and death. Moreover, one patient in OSD group who underwent sequential CT-PCD devel-



**Fig. 5** Male, age 21 years old, with a huge traumatic pancreatic pseudo-cyst underwent successful CT-guided PCD. He was discharged 7 days after treatment. Note a marker was placed at the anterior abdominal wall.



**Fig. 6** Male, age 39 years old, post cholecystectomy with multiple intra-abdominal collections and failed US-guided PCD (by the surgeon). Finally, he underwent explore laparotomy with successful drainage.

oped mild pneumothorax that required supportive treatment.

Twenty-five patients in CT-guided PCD group (86.2%) and 11 patients (78.5%) in OSD group met the criteria of clinical success. There was no statistically significant difference between two groups (p-value = 0.665). Table 1 shows clinical success in both groups.

### Discussion

During the past 20 years, numerous studies had proved the adequacy and safety of CT-guided percutaneous drainage (PCD) of intra-abdominal collection (s) and abscess (es). Only few studies had compared the success of CT-guided PCD versus open surgical drainage (OSD). The use of image-guided PCD is currently adopted by many institutions in an effort to reduce the frequency of complication and opened surgical drainage<sup>(7-11)</sup>.

CT-guided PCD now play an important role in intra-abdominal abscess in various sites, without the need for surgical laparotomy. It is important to emphasize that the authors's favorable results are successful treatment with less complication and mortality than an open drainage. Direct visualization of the needle/catheter and the lesion by CT facilitates accurate guidance. Perhaps the most valuable asset of the technique is the ability to assess vascularity by bolus injection. To my knowledge, in Asia, there was no previous report that compared clinical success of CT-guided PCD with open surgical drainage before.

The authors's study show 86.2% and 78.5% clinical success rare in CT-guided PCD group and open surgical drainage groups respectively. There was no statistically significant difference between two groups

**Table 1.** Clinical success in the two groups

Group	Successes	Failure	% Clinical Success
CT-PCD	25	4	86.2
OSD	11	3	78.5

(p-value = 0.665). This rate is in agreement with those reported in the literatures<sup>(9,11,12)</sup>.

The authors's complication rate was zero in PCD group. The difference was statistically significance from 28.6% in OSD group (Fisher's Exact Test = 0.008). The reported complications in the literatures were 7-40.7%<sup>(9,11,12)</sup>. This is in agreement with ours for OSD group. However, in those same reports, their complication rate from PCD was 4-29%. The difference in complication rate in PCD group may perhaps because of different study period. The imaging and intervention technique nowadays are much more advancement than 20 years ago.

The authors found no statistically significant difference of mean lesion size between two groups (p-value = 0.200). The mean hospital stays were 20.2 days and 24.5 days in PCD and open drainage groups, respectively. There was no statistically significant difference of mean length of hospital stay between two groups (p-value = 0.490). The length of hospital stay varied in other studies, from 7.4-17 days in PCD and

6.8-29 days in opened drainage<sup>(9,11,12)</sup>.

Improvement of the lesion was seen in 25 patients who underwent PCD (86.2%), and 10 patients (1.4%) with OSD. There was no statistically significant difference between two groups (Pearson Chi-square = 0.14). Three patients in CT-guided PCD group were discharged against advice; one patient in open surgical drainage group was dead. The patients whose lesion was not improved were included in "failure category". This detail, to the authors's knowledge, has not yet been discussed in other literatures.

The one attempt PCD in the authors's series was successful in more than 60%. More than 80% in OSD group had one attempt procedure. The re-open drainage was performed in 2 OSD patients. One of them converted to CT-guided PCD. But in PCD group, three patients required 3, 4 and 7 attempts per each. The revised procedure in PCD was only irrigation and checking the position of the catheter.

The main limitation of the authors's study is its retrospective nature. The authors may lose some data not carefully recorded. Needle paths and needle sizes selection among radiologists may vary for a particular site of lesion. As such, different needle paths and sites of collection will affect all of the variables selected for statistical analysis in this model. It is apparent that the selection of needle size is partly determined by lesion size, fluid viscosity and is influenced by the radiologist's preference and by whether lesions are surrounded by vital structure.

### Conclusion

There was no statistically significant difference in clinical success between CT-PCD and OSD groups. However the authors achieved higher improvement rate of the lesion(s), lower complication and no mortality in the patients who underwent CT-guided percutaneous drainage of intra-abdominal collection. So, the authors recommend CT-guided percutaneous drainage for not only an alternative treatment but also the first line treatment of the various site of intra-abdominal collection.

### Acknowledgements

The authors gratefully acknowledge the efforts of Dr. Tula Dhiensiri for her editorial assistance. The authors thank Emeritus Professor James A. Will for assistance with the English-language presentation of the manuscript.

### References

1. Men S, Akhan O, Koroglu M. Percutaneous drainage of abdominal abscess. *Eur J Radiol* 2002; 43: 204-18.
2. Khurram BM, Hua ZR, Batista O, Uriburu JP, Singh JJ, Weiss EG, et al. Percutaneous postoperative intra-abdominal abscess drainage after elective colorectal surgery. *Tech Coloproctol* 2002; 6: 159-64.
3. Gazelle GS, Mueller PR. Abdominal abscess. Imaging and intervention. *Radiol Clin North Am* 1994; 32: 913-32.
4. Jeffrey RB Jr, Wing VW, Laing FC. Real-time sonographic monitoring of percutaneous abscess drainage. *AJR Am J Roentgenol* 1985; 144: 469-70.
5. Doust BD, Quiroz F, Stewart JM. Ultrasonic distinction of abscesses from other intra-abdominal fluid collections. *Radiology* 1977; 125: 213-8.
6. Eisenberg PJ, Dawson SL. Percutaneous treatment of abdominal abscesses. In: Baum S, Pentecost MJ, editors. *Abram's angiography*. Vol. III. *Interventional radiology*. 4<sup>th</sup> ed. Boston: Little Brown; 1997: 925-38.
7. Marano I, Mainenti PP, Selva G, Cannavale M, Sodano A. Computerized tomography-guided drainage of postoperative abdominal fluid collections. *Radiol Med* 1999; 97: 160-5.
8. Walters R, Herman CM, Neff R, Cummings D, Harley J. Percutaneous drainage of abscesses in the postoperative abdomen that is difficult to explore. *Am J Surg* 1985; 149: 623-6.
9. Brolin RE, Noshier JL, Leiman S, Lee WS, Greco RS. Percutaneous catheter versus open surgical drainage in the treatment of abdominal abscesses. *Am Surg* 1984; 50: 102-8.
10. Olak J, Christou NV, Stein LA, Casola G, Meakins JL. Operative vs percutaneous drainage of intra-abdominal abscesses. Comparison of morbidity and mortality. *Arch Surg* 1986; 121: 141-6.
11. Treutner KH, Truong S, Klose K, Schubert T, Schumpelick V, Gunther RW. Intraabdominal abscesses-percutaneous catheter drainage versus operative treatment. *Klin Wochenschr* 1989; 67: 486-90.
12. Johnson WC, Gerzof SG, Robbins AH, Nabseth DC. Treatment of abdominal abscesses: comparative evaluation of operative drainage versus percutaneous catheter drainage guided by computed tomography or ultrasound. *Ann Surg* 1981; 194: 510-20.

---

**การศึกษาเปรียบเทียบผลสัมฤทธิ์ทางคลินิก ระหว่างการเจาะระบายผ่านผิวหนังภายใต้  
เครื่องเอกซเรย์คอมพิวเตอร์ กับการผ่าตัดเปิดช่องท้อง เพื่อระบายของเหลวที่คั่งค้างในช่องท้อง  
ในโรงพยาบาลศรีนครินทร์**

**วัลลภ เหล่าไพบูลย์, ชลิตา อภินิเวศ, ปารวี ประวิเศษ**

**ภูมิหลัง:** ผลการรักษาเพื่อระบายของเหลวที่คั่งค้างในช่องท้องดีขึ้นในช่วงทศวรรษที่ผ่านมา เนื่องจากความก้าวหน้า  
ในเทคนิคการผ่าตัดและการพัฒนาเทคนิคการเจาะระบายผ่านผิวหนังภายใต้เครื่องเอกซเรย์คอมพิวเตอร์

**วัตถุประสงค์:** เพื่อเปรียบเทียบผลสัมฤทธิ์ทางคลินิก ระหว่างการเจาะระบายผ่านผิวหนังภายใต้เครื่องเอกซเรย์  
คอมพิวเตอร์กับการผ่าตัดเปิดช่องท้อง เพื่อระบายของเหลวที่คั่งค้างในช่องท้อง ในโรงพยาบาลศรีนครินทร์

**วัสดุและวิธีการ:** ศึกษาเวชระเบียนและภาพถ่ายเอกซเรย์คอมพิวเตอร์ของผู้ป่วยทุกราย ระหว่างปี พ.ศ. 2547-2550  
ที่ผ่านการเจาะระบายผ่านผิวหนังภายใต้เครื่องเอกซเรย์คอมพิวเตอร์ (CT-PCD) หรือการผ่าตัดระบาย  
โดยการเปิดช่องท้อง เปรียบเทียบผลสัมฤทธิ์ทางคลินิก (การดีขึ้นของ lesion, การดีขึ้นของ clinical sepsis, การไม่มี  
ภาวะแทรกซ้อน และไม่มีภาวะเสียชีวิตของผู้ป่วย) ระหว่างสองกลุ่มนี้

**ผลการศึกษา:** ไม่พบความแตกต่างอย่างมีนัยสำคัญทางสถิติ ( $p\text{-value} = 0.520$ ) ในผลสัมฤทธิ์ทางคลินิกระหว่างกลุ่ม  
CT-PCD (25/29 ราย , 86.2%) และ กลุ่ม OSD (11/14 ราย , 78.5%) พบภาวะแทรกซ้อนในผู้ป่วย 4 ราย  
(รวมการเสียชีวิต 1 ราย) ในกลุ่ม OSD โดยกลุ่ม CT-PCD ไม่มีภาวะแทรกซ้อน สัดส่วนของผู้ป่วยที่มี lesion ขนาด  
เล็กลงหลังทำ CT-PCD (25/29 ราย, 89.3%) สูงกว่ากลุ่ม OSD (10/14 ราย, 71.4%) ระยะเวลาเฉลี่ยที่อยู่ใน  
โรงพยาบาลเป็น 20.2 วันในกลุ่ม CT-PCD และ 24.5 วันในกลุ่ม OSD

**สรุป:** การเจาะระบายผ่านผิวหนังภายใต้เครื่องเอกซเรย์คอมพิวเตอร์ อาจเป็นหัตถการแรกที่ใช้ในการรักษา  
เพื่อระบายของเหลวที่คั่งค้างในช่องท้อง

---